MONASH University

A Systems Approach to Assessment of Left Ventricular Outflow Tract Anatomy and Function

The Aortoventricular Interface in the Era of Transcatheter Aortic Valve Replacement

Dr Robert Gooley
MBBS (Hons) FRACP

A thesis submitted in fulfilment of the degree of Doctor of Philosophy in Medicine at Monash University

First submitted on 3rd May 2016

Table of Contents

COPYRIGHT NOTICES **3**
GENERAL DECLARATION **4**
ACKNOWLEDGEMENTS **5**
THESIS OVERVIEW **6**
CHAPTER 1 ..... **8**
CHAPTER 1A – INTRODUCTION 9
CHAPTER 1B – THE STATUS OF TRANSCATHETER AORTIC VALVE REPLACEMENT IN 2016 16
Declaration for Thesis Chapter 1B 17
Preface 18
CHAPTER 1C – THE LOTUS TRANSCATHETER AORTIC VALVE PROSTHESIS: A NOVEL TAVR DEVICE 32
Declaration for Thesis Chapter 1C 33
Preface 34
CHAPTER 2: QUANTIFICATION OF NORMATIVE RANGES OF AORTOVENTRICULAR INTERFACE DIMENSIONS USING MDCT IMAGING IN PATIENTS WITHOUT AORTIC VALVE DISEASE **42**
Declaration for Thesis Chapter 2 43
Preface 44
CHAPTER 3: THE GEOMETRIC INTERACTION BETWEEN A NOVEL TAVR DEVICE AND THE NATIVE AORTIC ANNULUS **54**
Declaration for Thesis Chapter 3 55
Preface 56
CHAPTER 4: COMPARATIVE SAFETY AND EFFICACY OF CURRENT GENERATION SELF---EXPANDING AND NEW GENERATION MECHANICALLY---EXPANDING TAVR PROSTHESES **67**
Declaration for Thesis Chapter 4 68
Preface 69
CHAPTER 5: MULTI---DETECTOR COMPUTED TOMOGRAPHIC ASSESSMENT OF LEAFLET THICKNESS IN A NOVEL MECHANICALLY EXPANDED TAVR PROSTHESIS **80**
Declaration for Thesis Chapter 5 81
Preface 82
CHAPTER 6: CONCLUSIONS AND FUTURE DIRECTIONS **99**
APPENDIX A – OTHER PUBLISHED WORK **103**
PUBLISHED MANUSCRIPTS 104
The SADRA Lotus Valve System: a fully repositionable, retrievable prosthesis 105
The next era of transcatheter aortic valve replacement: a case illustrating the benefit of a fully re---positionable, re---sheathable, and retrievable prosthesis. 113
BOOK CHAPTERS 118
The Interaction Between Psychological Health and valvular Heart Disease: Pathogenesis, Clinical Course and Treatment 118
APPENDIX B – ORAL PRESENTATIONS **140**
APPENDIX C – AWARDS AND SCHOLARSHIPS **141**

Copyright Notices

Notice 1

Notice 2

General Declaration

Declaration for thesis based or partially based on conjointly published or unpublished work

In accordance with Monash University Doctorate Regulation 17.2 Doctor of Philosophy and Research Master's regulations the following declarations are made:

I hereby declare that this thesis contains no material which has been accepted for the award of any other degree or diploma at any university or equivalent institution and that, to the best of my knowledge and belief, this thesis contains no material previously published or written by another person, except where due reference is made in the text of the thesis.

This thesis includes five original papers published in peer reviewed journals and one submitted though unpublished publication. The core theme of the thesis is assessment of aortoventricular interface in health, disease and following transcatheter aortic valve replacement. The ideas, development and writing up of all the papers in the thesis were the principal responsibility of myself, the candidate, working within the Monash Cardiovascular Research Centre under the supervision of Professor Ian Meredith and Professor James Cameron

The inclusion of co---authors reflects the fact that the work came from active collaboration between researchers and acknowledges input into team---based research.

Chapter	Publication Title	Publication Status	Candidate's Contribution
1B	Transcatheter Aortic Valve Implantation – Yesterday, Today and Tomorrow	Published	Background lit review, writing and editing manuscript
1C	The Lotus Transcatheter Aortic Valve: A Next---Generation Repositionable, Resheathable and Recapturable Prosthesis	Published	Background lit review, writing and editing manuscript
2	Quantification of Normative Ranges and Baseline Predictors of Aortoventricular Interface Dimensions Using Multi---Detector Computed Tomographic Imaging in Patients Without Aortic Valve Disease	Published	Review of existing data, study plan, data collection and interpretation, writing and editing manuscript
3	Assessment of the Geometric Interaction Between the Lotus Transcatheter Aortic Valve Prosthesis and the Native Ventricular Aortic Interface by 320---Multidetector Computed Tomography	Published	Review of existing data, study plan, data collection and interpretation, writing and editing manuscript
4	Comparison of Self---Expanding and Mechanically Expanded Transcatheter Aortic Valve Prostheses	Published	Review of existing data, study plan, data collection and interpretation, writing and editing manuscript
5	4---Dimensional Multidetector Computed Tomographic Assessment of Leaflet Thickening and Motion in Patients Treated with a Mechanically Expanded TAVR Prosthesis	Under Review	Review of existing data, study plan, data collection and interpretation, writing and editing manuscript

I have not renumbered sections of submitted or published papers within the thesis.

Signed: [redacted]

Date: 12th April 2016

ACKNOWLEDGEMENTS

This PhD would not have been possible without immense support from my supervisors, wife, colleagues and family.

I thank Professor Ian Meredith for his guidance and mentorship throughout not only this PhD but my entire Cardiology training. Your pioneering knowledge in the field of Structural Heart intervention and ability to impart this knowledge has allowed me to grow in the field.

I thank Professor James Cameron for guiding me through the PhD process. For being an ever sensible sounding board at all stages of my research endeavours. Your frank guidance has allowed me to complete my PhD in a timely yet academically rigorous manner.

I would also like to thank all of my colleagues who have helped me along the journey with assistance in my research projects.

To my wife, Dr Suong Le, thank you for your constant, non faltering support. You have been there at every stage of this PhD, always willing to listen and offer advise. Without your love and understanding this journey would have been far more difficult.

Thesis Overview

The aortoventricular interface describes the functional syncytium between the left ventricle and proximal aorta, necessary for normal central haemodynamic operation. Normal function would be considered as providing for optimal passage of oxygenated blood delivered from the left ventricle through the aortic valve to the systemic circulation.

Non---optimal function of the aortic valve through congenital malformation or degenerative processes is associated with a clear constellation of clinical signs and symptoms and with a well established natural history. These can all be understood on the basis of loss of normal function. Narrowing of the aortic orifice results in decreased systemic blood pressure, syncope, decreased exercise ability, left ventricular remodelling compensating for increased wall stress, secondary mitral and atrial dysfunction and increased pulmonary pressures. Aortic incompetence with its well known features of left ventricular dilatation, exertional fatigue, dyspnoea and palpitations is also explained by the deranged haemodynamic effects due to loss of hydraulic separation (temporal and spatial) between the low and high pressure components across the aortoventricular interface.

The common connection between these clinical entities is the disruption of appropriate flow across the left ventricular outflow tract – aortic valve – proximal aorta anatomical continuum. In health the structure of this interface functions to provide optimally matched volume blood flow with appropriate direction and timing for optimal energy utilisation and supply. Disturbance in the normal anatomy and its associated

clinical symptoms or signs are well described but the failure in underlying function not usually acknowledged.

This thesis aims, in the first instance, to review and, thereafter, to investigate, the potential influence of anatomy and function on both sides of the aortoventricular interface in populations without aortic valve disease, with aortic valve stenosis and post---treatment. Assessment based on modern anatomical imaging technology provides a concrete structural representation of left ventricular – aortic mechanisms. This thesis will present work aimed at integrating structural assessment by computed tomography with assessment of clinical function in patients affected by stenosis of the aortic valve and following percutaneous aortic valve intervention.

Chapter 1

Chapter 1A – Introduction

The aortic valve has gained significant attention in the last decade, driven by the development of new treatment modalities such as transcatheter aortic valve replacement (TAVR) and surgical aortic valve repair for aortic valve disease. These developments together with the aging western population have resulted in an increasing prevalence of aortic valve pathology[1]. Development of appropriate treatment strategies and devices mandates an improved understanding of both the anatomical features of the aortic valve and the physiological environment in which it functions during both health and disease.

Assessing the aortic valve in isolation, however, ignores its integral relationship to adjacent structures. Awareness of the impact that left ventricular and aortic pathology has on the appropriate function of the aortic valve is vital in achieving a comprehensive understanding of aortic valve pathology. An abnormality in any of these associated structures is likely to result in an abnormality of the entire aortoventricular interface. The common connection between pathological processes at any level of the aortoventricular interface is the disruption of appropriate flow across the left ventricular outflow tract – aortic valve – aorta anatomical continuum.

Aortoventricular Interface

The aortic valve is positioned in series with the mitral valve, left ventricle, left ventricular outflow tract and proximal ascending aorta. In health this interface functions to provide appropriately matched blood flow of sufficient magnitude, direction and timing to achieve optimal energy utilisation and supply. If the valve is approached in isolation without consideration of these adjacent structures it is impossible to fully understand aortic valve

function, haemodynamics or clinical sequelae in the setting of either health or valvular pathology.

The multifaceted interactions between the structural components of the aortoventricular interface, using traditionally available imaging techniques, have been difficult to demonstrate due to intrinsic limitations of these imaging modalities. The ability to visualise 3---dimensional geometric relationships have been difficult and virtually impossible to do in real time. The advent of 4---dimensional imaging by echocardiography, computed tomography or magnetic resonance has allowed non---invasive anatomic and functional assessment[2].

4---dimensional imaging integrates the time domain to 3---dimensional images to allow visualisation of moving cardiac structures. This facilitates the assessment of the functional relationship between imaged structures in addition to the stationary geometric relationships seen by 3---dimensional imaging. While these techniques, especially that of 4---dimensional multidetector computed tomography (MDCT), are rapidly becoming accepted as the gold standard for anatomical assessment prior to cardiac intervention there remains little data on what constitutes a normal anatomical range for aortoventricular dimensions. This is especially important for newly proposed anatomic measurements such as the aortic valve basal plane, measurements on which suitability for contemporary treatments are being based. Without the knowledge of normative ranges development of new therapeutics and the potential impact of any therapeutic device on the components of the aortoventricular interface cannot be predicted.

Aortic Stenosis

Moderate to severe valvular heart disease affects 1 in 8 people over the age of 75 with moderate to severe aortic stenosis affecting more than 5%[1].

In the western world age related calcific degeneration of a trileaflet valve is the commonest cause of aortic stenosis, followed by calcific degeneration of a bicuspid aortic valve, with rheumatic disease now relatively uncommon. As the population ages the prevalence of aortic stenosis has continued to rise. Severe aortic stenosis is associated with the development of a classical symptom triad of exertional dyspnoea, angina and syncope.

Symptom development has traditionally been explained by a mismatch between cardiac output and cellular requirement. While such a depiction is convenient it is an overly simplified explanation with the disease process resulting in changes in the left ventricle (myocardial hypertrophy), aortic blood flow patterns and coronary blood flow that are equally important in the aetiology of the recognised symptomatology.

The healthy tri---leaflet aortic valve opens fully during ventricular systole to allow ejection of an adequate stroke volume to satisfy cellular metabolic requirements. The complete opening of the valve allows 'normal' flow patterns as the ejected stroke volume traverses the proximal aorta. 4---dimension flow magnetic resonance imaging has shown that flow through a normal tri---leaflet aortic valve into a non---dilated aortic root results in high---velocity systolic streamlines that align with the direction of predominant flow without significant secondary flow patterns[3]. Preservation of normal flow patterns is important, as the development of abnormal

flow patterns in the setting of aortic valve dysfunction has been implicated in the development of aortic pathology[3,4].

Insertion of a prosthesis within the aortoventricular interface and its potential to affect these normal flow patterns, particularly when such prostheses alter the geometry of the native anatomy, have not been described in vivo with existing evidence limited to assessment of surgical prostheses in vitro and utilising less sophisticated imaging modalities.

Importance of the Aortoventricular Interface in the Era of TAVR

Recognition that a significant minority of patients with symptomatic severe aortic stenosis did not undergo surgical management due to real or perceived operative risk, led to the development of less invasive catheter based techniques of aortic valve replacement[5]. These techniques have advanced and TAVR has become an accepted alternative treatment strategy to surgical aortic valve replacement in high surgical risk patients[6] and the preferred treatment modality in selected inoperable patients[7].

The advent of TAVR has led to a need to determine appropriate anatomy and device sizing prior to the procedure, which is a departure from intra---procedural direct measurement during surgical valve replacement. Much work has focused on the use of MDCT and echocardiography with general consensus that while these modalities are complementary, MDCT is the preferred measurement given the three dimensional complex geometry of the aortoventricular interface.

Reliance solely on annular dimensions has been shown to lead to increased adverse events such as pacing requirement[8], valve deformation, paravalvular aortic regurgitation[9], mitral regurgitation and device embolisation. Hence it has been recognised that anatomical measurements of the entire aortoventricular interface are imperative to successful TAVR. The interaction between these dimensions determines overall suitability rather than isolated measurements. Despite this there is no accepted normative data for MDCT derived measurement of most of these metrics.

While the importance of accurate pre---procedural imaging has become widely accepted and in most cases mandated similar imaging techniques can be equally important in assessing the interaction between TAVR device and the native anatomy. MDCT imaging studies following device deployment have indicated that device types behave differently following deployment with self---expandable devices tending to accommodate to the native anatomy so that they will remain slightly eccentric when deployed in an eccentric annulus[10] while balloon---expandable devices tend to circularise the native anatomy[11]. An awareness of this device/anatomy interaction is important in appropriately sizing prosthesis and potentially in device selection in anatomy that is at the extreme of eccentricity.

4---dimensional MDCT imaging provides a unique opportunity to utilise the high spatial resolution of the modality to image TAVR device leaflets which have been beyond the resolution of echocardiography, the usual modality by which post---procedural device function has been assessed. This has recently led to recognition that in a significant minority of patients, device leaflets may thicken over time and lead to a degree of leaflet restriction[12].

The time course, clinical sequelae and optimal treatment of this newly described phenomenon has not yet been fully elucidated.

The proven benefit of TAVR and increasing clinical need has also led to a rapid adoption of the technology and to an increase in the number of devices reaching research trial and clinical practice. New devices are generally associated with development of new design features which are aimed at reducing complications, improving efficacy and optimising operator comfort with the procedure. The majority of new devices, however, have been investigated in single arm trials. Their effect on native anatomy, comparative safety and efficacy with contemporary devices and incidence of newly described complications such as leaflet thickening generally not described. Hence, the net clinical benefit from adoption of new device iterations can not currently be quantitated.

Conclusion

Appropriate matching of cardiac output to cellular requirements is reliant on appropriate anatomical and physiological function of a number of cardiac structures. These structures form the individual components of the aortoventricular interface.

In the evolving era of aortic valve intervention attention must be focused not only on the anatomical and geometric relation between the aortoventricular interface components but also on the physiological mechanisms of the disease process. Once the relationships of the aortoventricular interface in the setting of health and disease have been defined similar imaging modalities can be utilised to assess the effects of transcatheter prostheses on the native anatomy, to compare device iterations and to screen for late complications.

This thesis aims to firstly determine normative ranges for aortoventricular interface component dimensions in health together with their geometric relations. Using 4 dimensional MDCT scanning the impact of a novel TAVR device, the Lotus Valve System, on native anatomy will be quantitated and subsequently its clinical utility compared to a contemporary TAVR device. The thesis will conclude by utilising the same imaging modality to assess the longer---term structural stability of the Lotus Valve System.

References

1. Nkomo VT, Gardin JM, Skelton TN, Gottdiener JS, Scott CG, Enriquez---Sarano M. Burden of valvular heart diseases: a population---based study. Lancet 2006;368:1005---11.
2. Ionasec RI, Voigt I, Georgescu B, et al. Personalized modeling and assessment of the aortic---mitral coupling from 4D TEE and CT. Medical image computing and computer---assisted intervention : MICCAI International Conference on Medical Image Computing and Computer---Assisted Intervention 2009;12:767---75.
3. Hope MD, Hope TA, Meadows AK, et al. Bicuspid aortic valve: four---dimensional MR evaluation of ascending aortic systolic flow patterns. Radiology 2010;255:53---61.
4. Fazel SS, Mallidi HR, Lee RS, et al. The aortopathy of bicuspid aortic valve disease has distinctive patterns and usually involves the transverse aortic arch. The Journal of thoracic and cardiovascular surgery 2008;135:901---7,7e1---2.
5. Cribier A, Eltchaninoff H, Bash A, et al. Percutaneous transcatheter implantation of an aortic valve prosthesis for calcific aortic stenosis: first human case description. Circulation 2002;106:3006---8.
6. Kodali SK, Williams MR, Smith CR, et al. Two---year outcomes after transcatheter or surgical aortic---valve replacement. N Engl J Med 2012;366:1686---95.
7. Makkar RR, Fontana GP, Jilaihawi H, et al. Transcatheter aortic---valve replacement for inoperable severe aortic stenosis. N Engl J Med 2012;366:1696---704.
8. Bleiziffer S, Ruge H, Horer J, et al. Predictors for new---onset complete heart block after transcatheter aortic valve implantation. JACC Cardiovascular interventions 2010;3:524---30.
9. Sherif MA, Abdel---Wahab M, Stocker B, et al. Anatomic and procedural predictors of paravalvular aortic regurgitation after implantation of the Medtronic CoreValve bioprosthesis. Journal of the American College of Cardiology 2010;56:1623---9.
10. Schultz CJ, Weustink A, Piazza N, et al. Geometry and degree of apposition of the CoreValve ReValving system with multislice computed tomography after implantation in patients with aortic stenosis. J Am Coll Cardiol 2009;54:911---8.
11. Willson AB, Webb JG, Gurvitch R, et al. Structural integrity of balloon---expandable stents after transcatheter aortic valve replacement: assessment by multidetector computed tomography. JACC Cardiovasc Interv 2012;5:525---32.
12. Makkar RR, Fontana G, Jilaihawi H, et al. Possible Subclinical Leaflet Thrombosis in Bioprosthetic Aortic Valves. N Engl J Med 2015;373:2015---24.

Chapter 1B – The Status of Transcatheter Aortic Valve Replacement in 2016

Monash University

Declaration for Thesis Chapter 1B

Transcatheter Aortic Valve Implantation – Yesterday, Today and Tomorrow

Declaration by candidate

In the case of Chapter 1B, the nature and extent of my contribution to the work was the following:

Nature of contribution	**Extent of contribution (%)**
Review of existing literature, planning study protocol, collection and interpretation of data writing manuscript, creation of figures, editing manuscript	80%

The following co---authors contributed to the work.

Name	**Nature of contribution**	**Extent of contribution (%)**
Prof Ian Meredith	Planning study protocol, interpretation of data, writing and editing manuscript	10%
Prof James Cameron	Planning study protocol, interpretation of data, writing and editing manuscript	10%

The undersigned hereby certify that the above declaration correctly reflects the nature and extent of the candidate's and co---authors' contributions to this work.

Candidate's Signature	[redacted]	**Date** 12/04/2016

Main Supervisor's Signature	[redacted]	**Date** 12/04/2016

Preface

Having reviewed the anatomy and function of the aortoventricular interface together with the effect of disease processes on normal form and function, the following work, published in *Heart, Lung and Circulation*, the journal of the Cardiovascular Society of Australia and New Zealand, addresses the history and current status of transcatheter aortic valve replacement (TAVR).

TAVR was first performed in 2002[1] and since that time has garnered widespread acceptance as a superior treatment modality to medical therapy[2,3] and at least equivalence to traditional surgical valve replacement[4,5] in appropriately selected high--- and extreme---risk patients. With more than 200 000 procedures estimated to have been performed worldwide the field of TAVR has seen a continued evolution in pre---procedural assessment, procedural techniques and post---procedural care.

The evidence base assessing the efficacy and safety of TAVR is large and continues to grow. The following work highlights trial and registry based data which has been instrumental in increasing procedural uptake and shaping procedural evolution with particular emphasis on Australian practice.

1. Cribier A, Eltchaninoff H, Bash A, et al. Percutaneous transcatheter implantation of an aortic valve prosthesis for calcific aortic stenosis: first human case description. Circulation 2002;106:3006---8.
2. Makkar RR, Fontana GP, Jilaihawi H, et al. Transcatheter aortic---valve replacement for inoperable severe aortic stenosis. N Engl J Med 2012;366:1696---704.
3. Yakubov SJ, Adams DH, Watson DR, et al. 2---Year Outcomes After Iliofemoral Self---Expanding Transcatheter Aortic Valve Replacement in Patients With Severe Aortic Stenosis Deemed Extreme Risk for Surgery. J Am Coll Cardiol 2015;66:1327---34.
4. Kodali SK, Williams MR, Smith CR, et al. Two---year outcomes after transcatheter or surgical aortic---valve replacement. N Engl J Med 2012;366:1686---95.
5. Reardon MJ, Adams DH, Kleiman NS, et al. 2---Year Outcomes in Patients Undergoing Surgical or Self---Expanding Transcatheter Aortic Valve Replacement. J Am Coll Cardiol 2015;66:113---21.

Heart, Lung and Circulation (2015) 24, 1149–1161
1443-9506/04/$36.00
http://dx.doi.org/10.1016/j.hlc.2015.07.017

REVIEW

Transcatheter Aortic Valve Implantation – Yesterday, Today and Tomorrow

R. Gooley, MBBS, FRACP [a,b*], J.D. Cameron, MBBS, MD, BE, MEngSc [a,b], I.T. Meredith, MBBS, BSc, PhD, FRACP [a,b]

[a]MonashHeart, Monash Health, Melbourne, Vic., Australia
[b]Monash Cardiovascular Research Centre, Monash University, Melbourne, Vic., Australia

Received 5 July 2015; received in revised form 21 July 2015; accepted 27 July 2015; online published-ahead-of-print 8 August 2015

Since the first transcatheter aortic valve implantation (TAVI) was performed by Alain Cribier and colleagues in 2002 [1], the technology has garnered global support with more than 200,000 devices implanted. The rapid adoption of this technology has been driven by the need for a less invasive treatment modality in a cohort of patients often denied conventional surgical valve replacement due to an unacceptably high perioperative risk, whether real or perceived [2]. This, together with evidence that the technology confers morbidity and mortality advantages compared to medical therapy [3,4] and at least equivalent outcomes to surgical valve replacement [5,6] in select cohorts, has seen clinical approval in more than 50 countries.

The last 13 years has seen an evolution of practises and equipment affecting almost every aspect of the TAVI procedure from pre-procedural assessment to device design and post-procedural care. The almost exponential rate of change has both benefits and risks. Benefits, in that impactful changes are translated into clinical practice very rapidly, but risks, in that meaningful comparative research studies potentially lag behind and can be outmoded by the time they are published. This instability may in turn delay regulatory review and approval processes that are based on such studies. The aim of this review is to provide an overview of the evolution of TAVI, its current clinical position and likely future directions.

Keywords Transcatheter Aortic Valve Implantation · Transcatheter Aortic Valve Replacement · Aortic Stenosis · Surgical Aortic Valve Replacement

Burden of Disease and Clinical Need

Aortic stenosis is a significant health epidemic in most western civilisations due to the ageing population. The estimated prevalence of aortic stenosis is >4% in those aged over 65 years and higher still in the very elderly. The percentage of Australia's population aged 65 years or older has increased from 11.8% in 1994 to 14.7% in 2014 with the proportion aged over 85 years also increasing from 1% to 1.9% [7]. This equates to an estimated 130,000 elderly and nearly 30,000 very elderly people in Australia with aortic stenosis.

Given its association with ageing, by the time aortic stenosis becomes clinically apparent patients often have comorbidities, which place them at increased perioperative risk. In this setting approximately 30% of patients with symptomatic severe aortic stenosis have historically not undergone corrective surgery as a consequence of real or perceived perioperative risk [2]. The advent of transcatheter aortic valve implanation (TAVI) offers an alternative, less invasive treatment option for these patients.

TAVI Versus Medical Therapy

Despite the first TAVI case being performed in 2002 the first randomised evidence supporting its efficacy and safety compared to medical therapy, the PARTNER 1B trial [3], was not published until eight years later. Until this point the burden

*Corresponding author at: MonashHeart, Monash Health, 246 Clayton Road, CLAYTON VIC 3168. Tel.: +03 9594 6666; fax: +03 9594 6239,

of evidence relied heavily on single centre experience together with multicentre and multinational registries.

PARTNER 1B

The PARTNER 1B [3] trial randomised 358 patients who were deemed to be unsuitable for surgical valve replacement due to extreme surgical risk to treatment with TAVI using the first-generation Sapien 22 or 24F system (Figure 1A) (Edwards Lifesciences, Irvine, CA, USA) versus optimal medical therapy. The trial included a highly select cohort with a case review committee accepting only 12% of subjects who had been identified by the 21 participating sites.

PARTNER 1B demonstrated superiority of TAVI with a 30.7% one year all cause mortality rate compared to 50.8% in the medical therapy arm, leading to a number needed to treat of only five people to prevent a single death ($p<0.001$). At two years the number needed to treat reduced further to 4.1 people with mortality rates of 43.3% and 67.6% respectively [8]. Importantly, it appeared that patients were not just living longer but were also healthier with a significantly lower rate of re-hospitalisation, 72.5% versus 35% ($p<0.0001$). This reduction in morbidity and mortality was found despite aggressive treatment in the medical therapy arm including balloon aortic valvuloplasty in 83.8%.

CoreValve US Pivotal Extreme-Risk Trial

The CoreValve US Pivotal Extreme Risk trial [4] enrolled 471 patients, at 45 centres in the United States of America, to receive the CoreValve (Figure 1B) (Medtronic, Minneapolis, MN, USA) by the femoral access route and an additional 147 patients treated by alternative access routes (subclavian or direct aortic). Due to the demonstrated benefit of TAVI

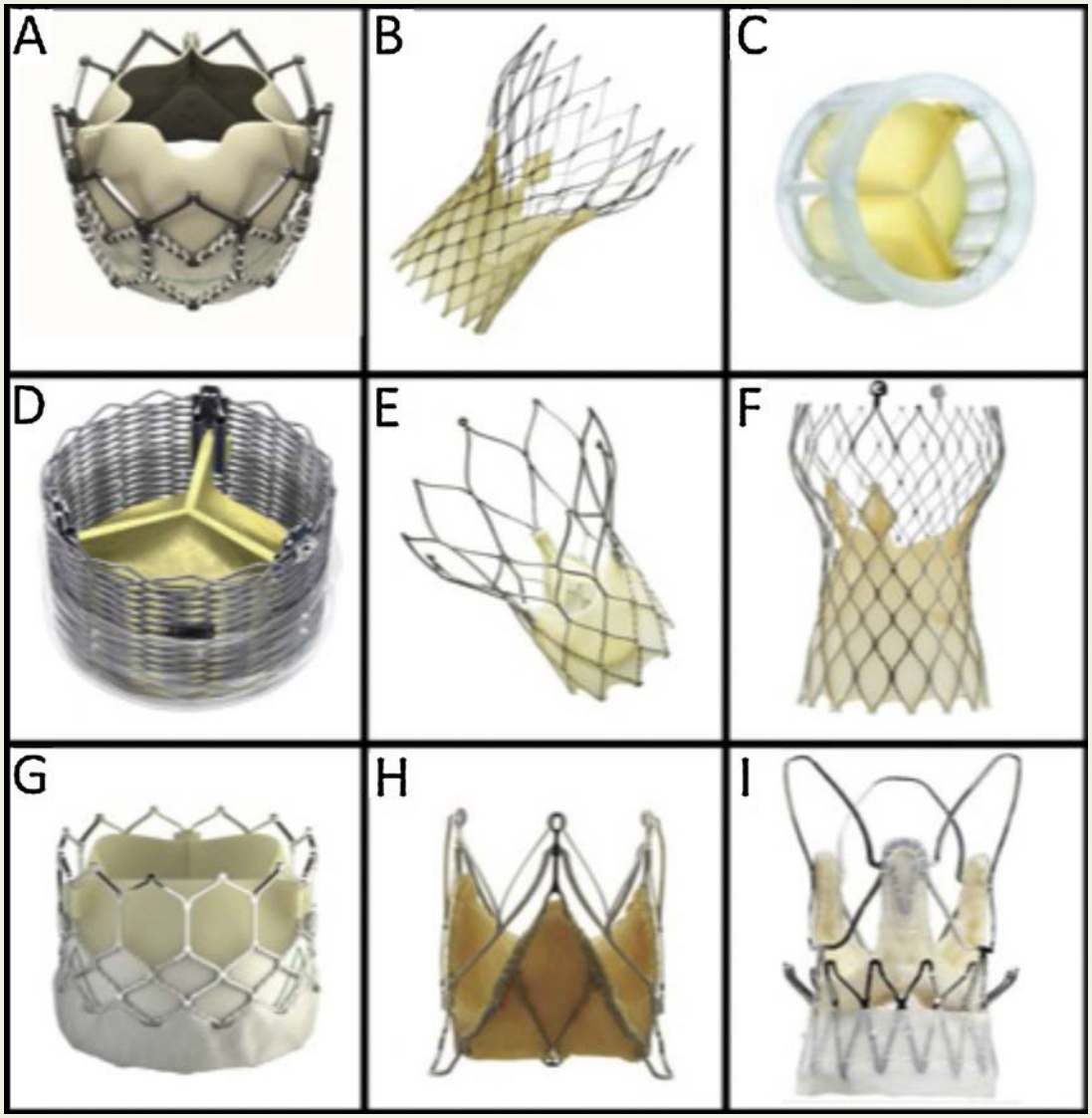

Figure 1 Current and new generation devices with CE Mark approval. At present only the Sapien and CoreValve devices have Therapeutic Good Administration approval for clinical use in Australia.
1A: Sapien, 1B: CoreValve, 1C: Direct Flow, 1D: Lotus, 1E: Portico, 1F: Evolut R, 1G: Sapien 3, 1H:JenaValve, 1I: Acurate TA.

compared to medical therapy in the PARTNER 1B trial, all patients received a transcatheter prosthesis with the results compared to a pre-determined objective performance goal of all cause mortality or major stroke at 12 months. The primary endpoint occurred in 26%, below the performance goal of 43% ($p<0.001$). There was a corresponding functional improvement of at least one New York Heart Association (NYHA) class in 90% of patients and at least two classes in 60%.

TAVI Registry Data

With only a limited number of randomised trials, there has been a reliance on registries in assessing the safety and efficacy data of this technology. Registry data has also allowed operators to benchmark their current clinical practice against contemporary, real-world experience.

Sapien and Sapien XT Registries

The Sapien and Sapien XT devices have been assessed in a number of registries with the SOURCE and SOURCE XT being among the largest. The SOURCE registry enrolled consecutive patients treated with the Sapien device at European centres. The one-year results for the first cohort of 1038 patients, treated at 32 centres between November 2007 and January 2009, demonstrated a survival rate of 81.1% in those treated by the trans-femoral route and 72.1% in an arguably more frail cohort treated by the trans-apical route [9]. Perhaps the most important finding from SOURCE was that independent risk factors for mortality extended beyond traditional surgical risk scores such as the Society of Thoracic Surgeons (STS) and EuroSCORE, to include variables such as renal disease, liver disease and smoking history.

The one-year SOURCE XT results for the first 2166 consecutive patients treated with the Sapien XT device show a further trend to treatment of patients with lower surgical risk scores, mean logistic EuroSCORE 20.4% [10]. The 19.5% one-year all-cause mortality rate was lower than the SOURCE cohort with relatively low rates of site-reported moderate or severe paravalvular aortic regurgitation (PAR), 6.2%. Multivariate predictors of mortality included liver disease and porcelain aorta, variables not included in either the EuroSCORE or STS score.

The Society of Thoracic Surgeons/American College of Cardiology Transcatheter Valve Therapy (TVT) Registry is a compulsory American registry tied to procedural funding. The results of the first 5,980 patients enrolled at 224 commercial sites were presented at ACC 2014 [11]. While the TVT Registry will include all TAVI devices this cohort included only Sapien devices due to its earlier commercial approval. At one-year the stroke rate was 3.6% and mortality 26.2%. These real world results are comparable, if not better than those seen in the highly selected PARTNER trials.

CoreValve Registries

The ADVANCE Registry enrolled 1015 patients treated with the CoreValve device at 44 centres in Europe, Asia and South America between March 2010 and July 2011. All centres were experienced in TAVI, having performed in excess of 40 cases prior to enrolling into the registry [12]. The mean logistic EuroSCORE was comparable to the SOURCE XT population at 19.4%. At one-year all-cause mortality was 17.9%, stroke was 4.5% and 13% of patients had moderate residual PAR with no cases of site-reported severe PAR. The ADVANCE registry results began to highlight an important difference between the CoreValve and Sapien devices with 29.3% of subjects requiring implantation of a permanent pacemaker.

Registry data has also been important in assessing longer-term device function and stability. The CoreValve Italian Registry reported three-year outcome data in 178 patients treated at 12 Italian centres [13]. The all-cause mortality at one, two and three years was 23.6, 30.3 and 34.8% respectively. There were no cases of valve failure, with preservation of valve area and haemodynamic performance. A subsequent analysis of 663 patients enrolled in the CoreValve Italian Registry was the first study to identify the important correlation between residual PAR and mortality with a hazard ratio for moderate or greater PAR of 3.79 [14]. A similar association has subsequently been identified in a number of other registries and trials leading to a global effort among device companies and clinical operators to reduce PAR [15,16].

Multi-device Registries

The FRANCE 2 registry enrols all patients undergoing TAVI at centres in France. Among 3195 patients treated at 34 centres between January 2010 and October 2011 approximately two-thirds received the Sapien device while the remainder were treated with the CoreValve [17]. The all-cause mortality rate was 9.7% at 30-days and 24% at one year with a one-year incidence of stroke of 4.1%. Predictors of mortality were increased EuroSCORE, NYHA class III or IV functional status, use of the trans-apical implantation approach and again higher residual PAR was found to independently predict outcomes. As this is a registry direct comparisons between the two device types are diffi but there were no obvious differences in procedural safety or effi y except for highlighting the higher rate of pacemaker implantation following treatment with the CoreValve device.

Australian Registries

The Australian and New Zealand Interventional communities have contributed significantly to the body of data supporting the safety and efficacy of TAVI. The Australia and New Zealand CoreValve Registry and Australian and New Zealand SOURCE (Edwards) Registry have shown that local results are in keeping with international results. The ANZ CoreValve Registry enrolled 540 patients at 10 centres with all-cause mortality rates of 4.1%, 11.9% and 21.2% at 30- days, one year and two years respectively. At 30 days the rate of stroke was 5.3% and pacemaker implantation occurred in 28.4% [18]. The ANZ Source Registry treated 132 people with the Sapien and Sapien XT valves at eight centres. At 30 days the all-cause mortality was 7.8% and at one year 18.3%. The 30-day stroke rate was 3.9% and permanent pacing was required in 4.7% [19].

TAVI versus SAVR

Despite a large number of single-arm TAVI trials and large-scale clinical registries there are currently only two published randomised trials comparing the efficacy and safety of TAVI to the current standard of care, surgical valve replacement (SVR).

PARTNER 1A

The PARTNER 1A [5] trial was the first ever randomised study of aortic valve replacement, surgical or transcatheter. Until this study was published the data supporting surgical aortic valve replacement relied on single arm registries and cohort studies compared to historically collected natural history data. This led to a dearth of class A recommendations in both the European Society of Cardiology and American College of Cardiology valvular heart disease guidelines.

The PARTNER 1A study compared the Sapien device to SAVR in 699 patients at 25 centres. All patients were deemed to be at high surgical risk based on a STS risk score greater than 10 and agreement by two study site surgeons that the estimated 30-day mortality risk was greater than 15%. In addition all patients were discussed at a case review committee, with only 34% of site-identified patients accepted for trial enrolment. An independent clinical events committee adjudicated all major adverse events.

At 12 months the primary outcome measure of all-cause mortality was non-inferior, 24.2% in the Sapien cohort and 26.8% in the SAVR cohort ($p<0.001$). It should be noted that the PARTNER trial was conducted at sites with well-established, high-volume cardiothoracic surgical programs and that the results in the surgical arm of the trial exceed that predicted by the STS scores, with a 30-day observed mortality of 6.5% compared to the STS predicted mortality of 11.7%. Hence, it could be argued that the trial compared experienced surgical valve replacement with relatively novice transcatheter valve replacement yet still found that in appropriately selected high-risk patients TAVI had equivalent overall safety and efficacy.

While the primary outcome measure of all-cause mortality was non-inferior, concerns were raised about the higher occurrence of some complications in the TAVI cohort. In particular, higher rates of neurological events (8.7% versus 4.3%, $p=0.03$) and of PAR (12.2% versus 0.9%, $p<0.0001$) were noted. While reported stroke rates have been lower in subsequent trials and registries this result highlighted the importance of increased research into procedural steps or interventions which may prevent stroke. The five-year results from PARTNER 1A show equivalence of the two cohorts in regard to all-cause mortality, 67.8% TAVI versus 62.4% SAVR, and convergence of the rate of neurological events with no significant difference remaining between the groups [20].

The importance of PAR was highlighted in the three-year PARTNER 1A results where a strong correlation was found between the degree of residual PAR and mortality [21]. While the three-year all-cause mortality rate was similar between the treatment groups, 44.2% in the TAVI cohort and 44.8% in the SAVR cohort, those patients with no or trivial PAR had a significantly lower rate (35.3%), than those with mild PAR (44.3%) and those with moderate or severe PAR (60.8%). A similar trend to poorer outcomes in those left with residual PAR had been suggested in earlier PARTNER data [22] and has been a significant driver for device iteration and development. Perhaps more concerning than the effect of PAR on mortality is that at three years only approximately half of enrolled patients were alive and free from a neurological event, emphasising the importance of appropriate patient selection.

COREVALVE US Pivotal High-Risk Trial

The randomised CoreValve US Pivotal High-risk trial [6] enrolled 795 high-risk patients in a 1:1 randomisation to TAVI with the CoreValve prosthesis or SAVR at 45 US centres. All patients were deemed to be at high surgical risk based on an estimated surgical mortality risk of 15% at 30-days. Given the recognised limitations of surgical risk scores used in isolation this assessment included the STS predicted risk of mortality score, frailty assessment and review of comorbidities not accounted for in these scoring systems. In addition a national screening committee reviewed all cases prior to study enrolment.

The trial demonstrated superiority of TAVI for the primary outcome measure of all-cause mortality at 12 months, 14.2% versus 19.1% ($p=0.04$). Similar to the surgical mortality results seen in the PARTNER 1A trial, the observed 30-day surgical mortality of 4.5% was below both the STS risk score prediction of 7.5% and significantly lower than the stated inclusion criteria of an expected 30-day mortality >15%. Despite these surgical results the trial demonstrated superiority of TAVI at one year with a further increase in absolute risk reduction at two years from 4.8% to 6.5% [23].

In contrast to the PARTNER 1A trial there was no significant difference in the rate of neurological events identified at one year (8.8% TAVI versus 12.6% SAVR, $p=0.10$). There was a higher rate of moderate or severe PAR in those treated with the CoreValve (9% versus 1.3% at 30-days, $P<0.001$) though at one year of follow-up this was not found to correlate with increased mortality.

Future Trials

A number of ongoing trials aim to compare TAVI devices to SAVR in varying cohorts. The PARTNER 2A trial will compare the newer Sapien XT iteration to SAVR in a more intermediate risk population while the SurTAVI study aims to compare the CoreValve device to SAVR also in an intermediate risk population.

Lessons Learnt from Registries and Trials

Patient Selection

Evolution of device technology and delivery techniques has eliminated most anatomical and clinical barriers to successful

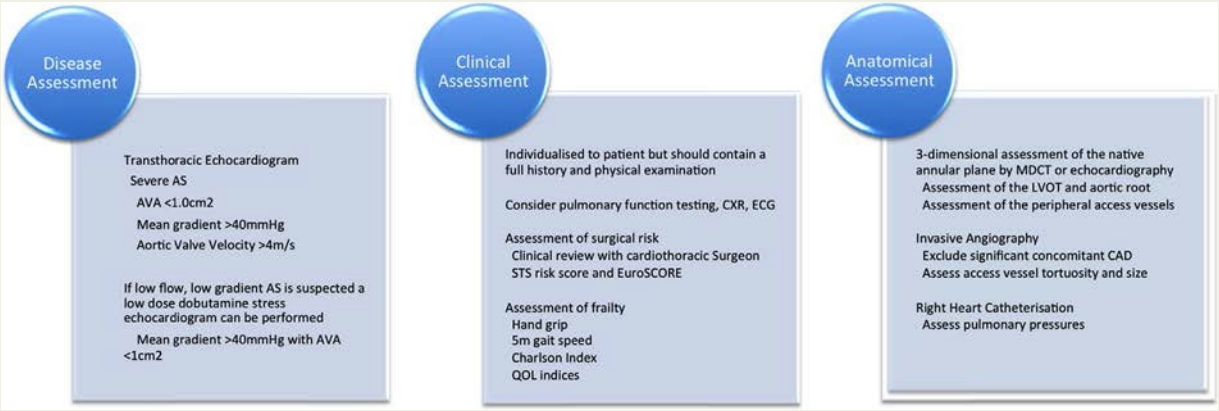

Figure 2 Requirements to accurately assess patient suitability for transcatheter aortic valve implantation.

TAVI, making the majority of patients eligible for treatment. Despite exhaustive patient assessment prior to trial recruitment one-year all-cause mortality rates range from 15 to 30% [3,4], while longer-term follow-up at three years suggests that mortality rates approach 50% [21]. There are also a significant number of patients who fail to gain an appreciable improvement in quality of life following the procedure [24].

Initial enrolment in clinical trials and registries relied heavily on established surgical risk scores such as the Society of Thoracic Surgeons Predicted Risk of Mortality score (STS PROM) [25] and EuroSCORE [26]. Both of these risk scores were derived from surgical populations and designed to estimate surgical rather than TAVI risk. The scores are also dependent on a relatively limited number of clinical variables. Multivariate analysis of a number of large registries and trials has, however, identified a number of other independent predictors of mortality such as age, renal disease, liver disease and frailty [24].

The importance of patient frailty has been shown in a number of trials where various indices such as the Katz index, handgrip and walk speed correlate with not only functional improvement but also mortality [27,28]. Indeed recent evidence has suggested that the Katz Index may more accurately determine procedural and 30-day mortality than either the STS or EuroSCORE, with a Katz Index <6 associated with a three-fold increase in procedural and 30-day mortality [29]. While it is apparent that frailty should be factored into patient selection, the ideal assessment tools and how they should be incorporated within an all-inclusive patient evaluation requires further research (Figure 2).

While a dedicated TAVI risk score is likely to emerge in the near future, current patient selection relies on assessment by a multi-disciplinary Heart Team including interventional cardiologists, non-invasive cardiologists, cardiothoracic surgeons, geriatricians, anaesthetists, clinical nurse specialists and primary care doctors (Figure 3). This ensures that all facets of a patient's medical, psychological and social situation will be accurately assessed and factored into decision-making.

Anatomical Assessment

Device sizing algorithms were initially based on two-dimensional (2D) echocardiographic imaging which failed to accurately represent the complex three-dimensional (3D), non-circular structure of the native aortoventricular interface [30]. With no true anatomical annulus the 'annular or basal plane' is now widely accepted as the short-axis plane through the nadir of each coronary cusp (Figure 4) [31]. In the majority of people this annular plane is an elliptical structure and hence 2D imaging has been found to either under-estimate or over-estimate the true size. While there has been much focus on the use of 3D anatomical assessment it is imperative that these dimensions are considered in the context of the proposed device as the interaction between prosthesis and native anatomy, such as the degree of annular circularisation, varies between device types [32–35].

Accurate sizing ensures that the native annulus is appropriately occupied so as to reduce complications such as device embolisation or PAR while simultaneously avoiding excess oversizing, which may result in complications such as annular injury [36] or increased rates of permanent pacing [37,38]. The application of MDCT based sizing algorithms has been shown in some cohorts to reduce the degree of PAR by more than half [39].

Access Sites and Vascular Injury

In a significant minority of patients concomitant peripheral arterial disease means that non-femoral access sites are required for passage of the delivery sheath. The subclavian artery can be used for peripheral deployment, with the left subclavian artery often providing a more favourable course than the right. When peripheral access is not available a surgical approach can be used either through a lateral thoracotomy and left ventricular apex puncture or through a hemi-sternotomy or right mini thoracotomy and cannulation of the ascending aorta. In more challeng- ing cases, when no safe alternative access site can be utilised, routes such as the carotid artery [40,41] or

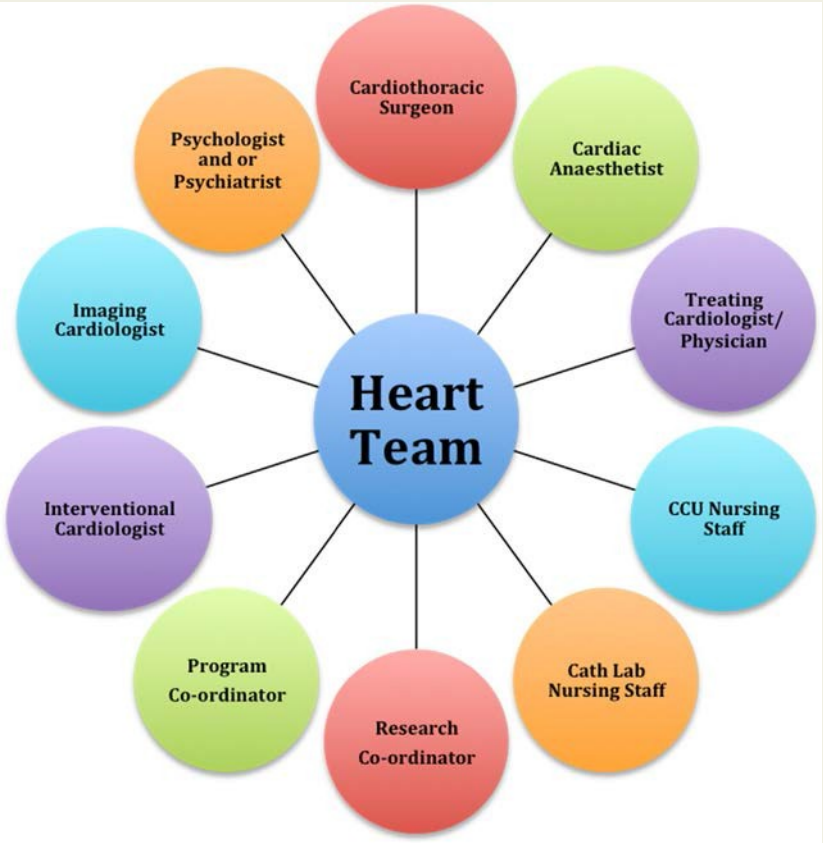

Figure 3 The Heart Team approach should include a wide range of healthcare providers to ensure all facets of patient health are considered in determining suitability for transcatheter aortic valve implantation.

puncture from the inferior vena cava into the descending aorta [42] have been reported.

Most current generation TAVI devices require delivery through large calibre sheathes that increase potential for major vascular complications which are not only associated with higher rates of bleeding, transfusion and renal failure but also increased mortality [43]. A number of factors have been identified which may predict vascular complications including oversizing of the access sheath relative to minimum vessel diameter and the presence of extensive vascular calcification [44]. The correlation between vascular injury and mortality has driven efforts to modify delivery systems and closure techniques. Many companies have focussed on reducing the sheath size such as the expandable Edwards e-sheath (Edwards Lifesciences, Irvine, CA, USA) or 14F inline sheath used with the next generation CoreValve Evolut R system (Figure 1F) (Medtronic, Minneapolis, MN, USA). The routine use of a balloon crossover technique, where final vascular closure is achieved during controlled balloon haemostasis has also been shown to mitigate the risk of vascular injury [45,46].

Stroke

Manipulation of the calcified aortic annulus during balloon valvuloplasty and device deployment caries a risk of debris embolisation and stroke. In addition, passage of delivery systems across the aortic arch may contribute to embolisation of atheromatous material. The PARTNER 1A trial suggested that the rate of neurological events was approximately double that seen in the surgical arm (8.7 versus 4.3%, p=0.03) [5] while studies utilising magnetic resonance cerebral imaging have demonstrated that the rates of new lesions reaches 70-90% [47–49]. The majority of these are 'clinically silent' although this may simply relate to inadequate detection.

Cerebral protection devices have been developed to deflect debris away from the cerebral vessels or capture it within filters. Studies of these devices to date have shown that the majority of patients continue to suffer new MRI detected lesions, however the volume of new lesions is reduced [50]. Whether reduction in lesion volume correlates with a reduction in clinical events has not been demonstrated. The CLEAN-TAVI study assessed the efficacy of the CLARET Montage filter system in a 100 patient randomised trial. Like other small trials there was a significant reduction in MR lesion volume but also a non-significant trend to reduction in neurological symptoms (24% versus 12%, p=0.118) [51]. The SENTINEL trial aims to enrol 284 patients though may still remain underpowered given the relatively low rates of clinically detected stroke in contemporary practice (Figure 5).

The CoreValve US Pivotal trial demonstrated a numerically lower rate of all stroke in the TAVI cohort compared to

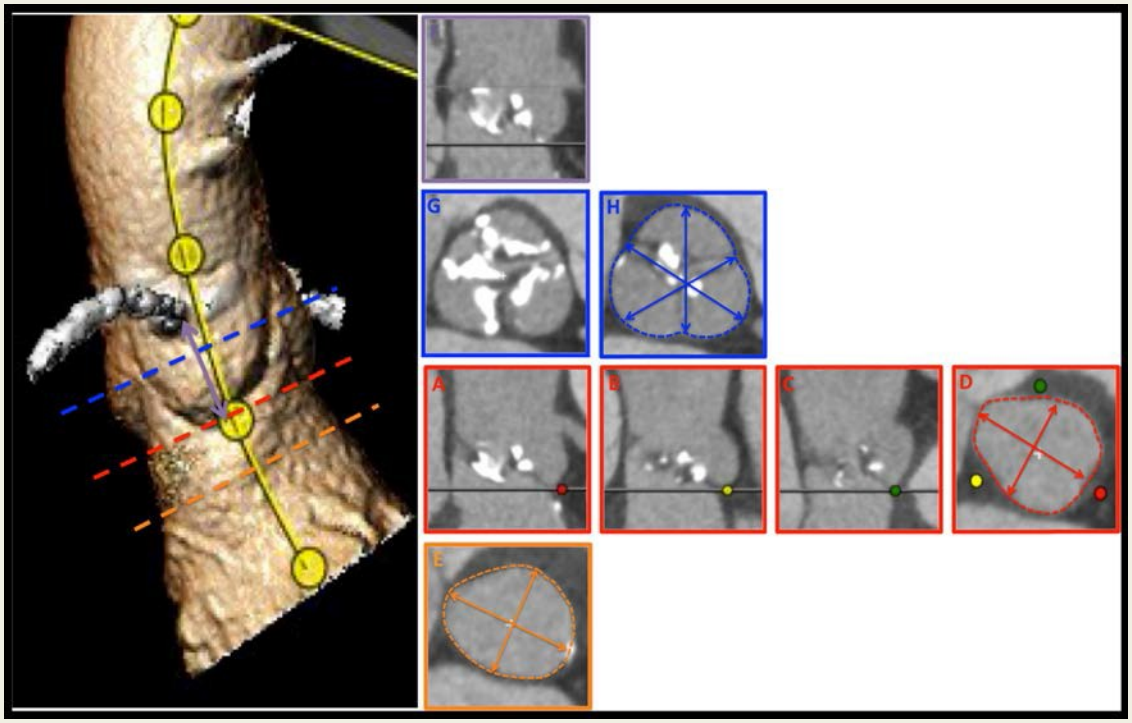

Figure 4 3-dimensional multi-detector row computed tomographic assessment of the entire aortoventricular interface is important in accurate sizing to ensure safe and effective transcatheter valve implantation. The nadir of each coronary cusp is identified (A, B, C) and the basal plane identified (D). Measurements are then taken along the centre line, in relation to the basal plane, at the level of the left ventricular outflow tract (E), coronary ostia (F) and sinuses of Valsalva (G, H).

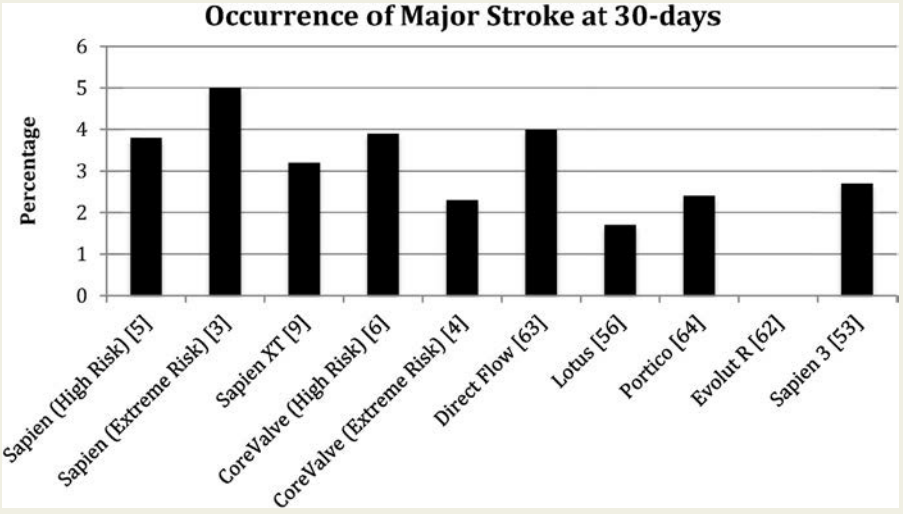

Figure 5 Reported occurrence of major or disabling stroke at 30-days.

the surgical arm, 4.9% versus 6.2%, though this difference was not statistically different (p=0.46) [5]. A large meta-analysis of more than 10,000 patients found a 30-day stroke rate of 3.3±1.8% with lower rates after trans-apical TAVI, 2.7±1.4% [52]. Even lower rates of stroke (1.5%) were recently reported in patients receiving the next generation Sapien 3 (Figure 1G) as part of the PARTNER II trial (Edwards Lifesciences, Irvine, CA, USA) [53]. The trial, which included a more intermediate risk cohort, also found that the rate of disabling stroke was less than 1%, a potentially acceptable level if this technology is extrapolated to a younger, less morbid population.

Para-prosthetic Aortic Regurgitation

Perhaps the Achilles' heal of TAVI has been PAR. Placement of a circular prosthesis in a non-circular native annulus results in residual interstices between the frame and native

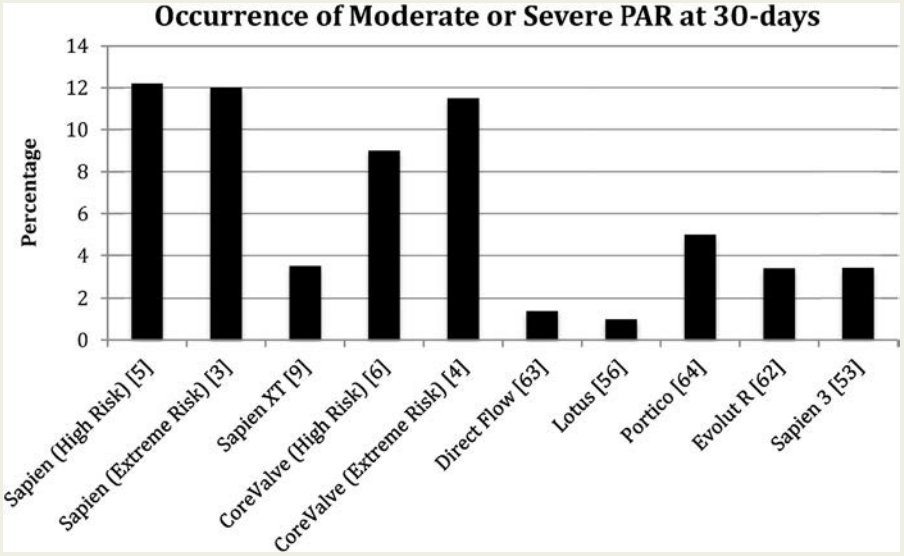

Figure 6 Reported paravalvular regurgitation rates at 30-days.

tissue through which blood can regurgitate into the left ventricle. In addition to annular eccentricity [54] the presence of significant calcification at the annular or sub-annular levels exacerbates this problem [16].

Recognition that the presence of even mild PAR conveys prognostic implications [15] has lead to increased efforts aimed at its reduction. Initial methods involved oversizing the TAVI prosthesis in an effort to occupy a greater annular area, increase prosthesis/tissue interaction and have the native annulus conform to the circular prosthesis. The use of 3D imaging has facilitated more accurate sizing and use of appropriate oversizing algorithms, resulting in lower rates of PAR (Figure 6) [55]. Oversizing devices, however, has the potential to increase complications such as annular injury, rupture and pacing requirement, particularly in heavily calcified annuli [36].

New generation devices have moved to include design features such as sealing membranes or skirts around the outer aspect of the valve frame to occupy these residual interstices and reduce PAR. Other devices use sealing rings or alterations of the frame cell size to better navigate and accommodate annular calcification. These design features may negate the need to excessively oversize the prosthesis and allow 'right sizing' rather than oversizing.

The Lotus Valve System (Figure 1D) (Boston Scientific, Marlborough, MA, USA) utilises a unique adaptive membrane around the outer valve frame designed to occupy residual interstices. The efficacy of this membrane was demonstrated in the REPRISE II trial with only 1% incidence of moderate PAR and no severe PAR as adjudicated by a core laboratory [56]. The Sapien 3 device (Edwards Lifesciences, Irvine, CA, USA) also has a sealing skirt around the outer aspect of the inflow frame segment contributing to the low rates of moderate (3.7%) and severe (0.1%) PAR observed in 1659 patients treated with the Sapien 3 as part of the PARTNER II study [53].

Pacing

The rate of permanent pacing following TAVI is variable and determined by patient, procedural and device factors. Male gender and existing conduction abnormalities [57] have been shown to independently predict the need for pacing together with procedural factors such as depth of implant [58] and intra-procedural atrioventricular block [57]. Device design also impacts pacing requirements with lower rates reported for the Sapien balloon expandable prosthesis than the self-expanding CoreValve. In a contemporary, non-randomised comparison of the CoreValve and Sapien devices at a number of European centres the pacing rates were 22.5% and 5.9% respectively [59].

The rate of new pacemaker insertion is trending down, driven by higher device positioning to avoid contact with the conducting tissue, less aggressive balloon pre-dilatation and a reduction in the degree of oversizing as more prosthesis sizes have become available (Figure 7). Delaying the insertion of permanent pacemakers may also reduce the overall requirement as normal conduction may return in the days following TAVI as tissue inflammation and oedema resolves [60].

Device Malpositioning and Embolisation

Correct valve position is important in reducing complications of TAVI as placement of the device above the annulus may result in PAR or device embolisation [61] due to incomplete annular sealing while placement excessively deep in the LVOT may increase the chance of cardiac conduction abnormalities. The ability to achieve accurate placement with current generation devices is limited. The balloon expandable

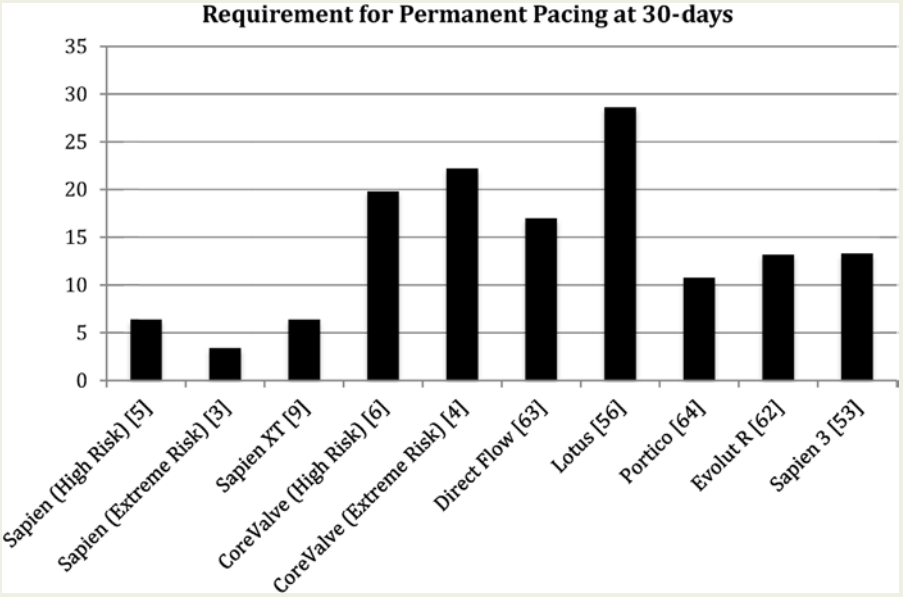

Figure 7 Reported need for new permanent pacemaker insertion at 30-days.

Sapien is positioned during rapid ventricular pacing to limit device movement while the balloon is inflated, after which no further device repositioning is possible. The self-expanding CoreValve prosthesis is more gradually released but device repositioning is still limited to forward or backward tension applied to the delivery system.

Many new generation devices have encompassed features that facilitate at least partial if not complete repositioning and or retrieval. Device function, stability and presence of complications such as PAR can be assessed prior to release of the device and any repositioning or change of device achieved with no or minimal trauma to the native tissue. The efficacy of the fully repositionable and retrievable Lotus Valve system was highlighted in the 120 patient REPRISE II trial where six patients had a prosthesis retrieved to enable device exchange resulting in 120 successful deployments with no device migration, embolisation, ectopic deployment or need for valve-in-valve [56] while the CoreValve Evolut R (Medtronic, Minneapolis, MN, USA), a new iteration of the Corevalve which allows resheathing and repositioning, achieved a 98.6% rate of successful single prosthesis deployment in the 60-patient CE Mark trial [62].

The Direct Flow (Figure 1C) (Direct Flow Medical Inc, Santa Rosa, CA, USA) transcatheter device employs a unique mechanism of deployment to facilitate full repositioning. The valve frame is inflated with pressurised saline and then assessed by fluoroscopy, angiography and echocardiography to ensure optimal positioning and correct sizing prior to exchange of the pressurised saline for a hard setting polymer. The device was assessed in the 100 patient single arm DISCOVER trial [63]. Survival was 99% at 30-days and 90% at one year, with all patients who were alive at one year having mild or less PAR.

The Portico (St Jude Medical, St Paul, MN, USA) TAVI device is a self-expanding, repositionable and retrievable prosthesis composed of a nitinol frame housing bovine pericardial leaflets (Figure 1E). The Portico CE Trial enrolled 100 patients at six European sites [64]. The primary endpoint of all cause mortality at 30 days was 2.9% with only 3.9% of subjects requiring more than a single prosthesis. At 30 days the rate of more than mild PAR was 3% with reduction in mean gradient from 45.8 to 8.7 mmHg and increase in the valve area from 0.6 cm^2 to 1.7 cm^2. The Portico Re-sheathable Transcatheter Aortic Valve System US IDE Trial commenced in May 2014 and randomises high or extreme surgical risk patients to TAVI with the Portico device or a commercially available TAVI device at 40 sites.

Expanding Indications For TAVI

TAVI for Degenerated Aortic Bioprostheses

The rate of structural valve dysfunction in surgical aortic bioprostheses, stenosis or regurgitation, approaches 15-25% at 15 years and 40% at 20 years [65,66], however durability is probably lower when implanted in a younger cohort [67]. By the time of device failure the patient cohort is older, with a greater burden of comorbidities and increased frailty. This has led to interest in inserting TAVI prostheses within degenerated surgical prostheses in order to avoid the morbidity associated with repeat sternotomy. In this setting the majority of experience has been with the CoreValve and Sapien devices. While no randomised comparison has been made of the efficacy and safety of these two devices in this setting, results of both devices are good [68,69]. TAVI devices have also been

used in the mitral position with success when surgical prostheses or annuloplasty rings fail [70].

TAVI in TAVI

Placement of a TAVI device within another TAVI device has been widely reported, predominantly in the acute or subacute setting to treat significant PAR or correct a malpositioned device. New generation devices such as the Lotus, Evolut R and Direct flow prostheses that allow device interrogation prior to repositioning or release have seen the rates of 'TAVI in TAVI' decline significantly.

Aortic Regurgitation and Bicuspid Aortic Stenosis

TAVI devices were initially used solely for the treatment of age related, calcific aortic stenosis. Significant aortic regurgitation or bicuspid morphology excluded patients from most trials as aortic annular and root dilatation together with geometric changes that accompany these conditions, were felt to make accurate positioning difficult, increase frame distortion and result in higher rates of PAR.

The JenaValve (Figure 1H) (JenaValve Inc, Munich, Germany) a transapical prosthesis was the first TAVI device to receive CE mark for the treatment of severe aortic regurgitation. It is composed of three nitinol 'feelers', which are positioned into the coronary cusps to achieve correct anatomical alignment with the native valve commissures and clipping of the native leaflets. This active fixation may allow for a more stable device position in enlarged aortic anatomy as is often seen in the setting of AR. The valve was examined in a single-arm, 73-patient study at seven German centres [71]. The trial's primary endpoint of 30-day mortality was 7.6% with 89.6% procedural success. There was a 6% rate of conversion to open surgery, 3% incidence of stroke and 9.1% permanent pacemaker requirement. Other new generation devices with sealing membranes and skirts may also see favourable results in the setting of predominant aortic regurgitation.

While patients with bicuspid valves have generally been excluded from large trials, an increasing number of such patients have been successful treated by TAVI [72,73]. Because bicuspid aortic stenosis often presents at a younger age, in patients without significant comorbidities, extrapolation of TAVI to this cohort must be made cautiously. In such patients, given the lack of supporting data, surgical AVR generally remains the treatment of choice.

Younger and Lower Risk

While the initial PARTNER 1A and 1B trials enrolled elderly high and extreme surgical risk patients with an average STS risk score of 11.8±3.3% and 11.6±6.0% respectively, more contemporary trials have shown a trend to treatment of lower risk patients with the average STS risk score in the CoreValve US Pivotal trial only 7.3±3.0%. The Partner 2A and SurTAVI trials are designed to specifically assess the safety and efficacy of TAVI in an intermediate risk cohort.

This is a clinically important issue, as large-scale registries have shown a trend to treatment of lower risk patients, driven by both patient preference for less invasive treatments but also clinician awareness of futility in some high and extreme risk patients. Such drift in clinical practice must, however, be supported by robust trial evidence of immediate and sustained safety and efficacy. The lowering of overall STS risk scores by way of excluding treatment of extremely high-risk patients in whom TAVI may be futile, is however, highly appropriate and should be encouraged.

Current Australian Practise

There are currently no formal Australian requirements for operators or centres wishing to perform TAVI. In the United States of America, the 2012 'multi-society expert consensus statement' recommended that TAVI be limited to centres with experience in structural heart disease, with all heart team members available on site, with experience in MDCT and TTE imaging and with appropriately configured catheterisation or operating theatres [74]. They further recommended that TAVI centres should perform in excess of 1,000 cardiac catheterisations, 400 coronary interventions and 50 surgical aortic valve replacements (10 high risk) per year. It was recommended that individual TAVI cardiol- ogists had performed 100 structural heart procedures and TAVI surgeons had performed 100 surgical aortic valve replacements, 10 of which were high risk, prior to commencing a TAVI program. In order to maintain a critical volume of procedures it was recommended that centres perform an average of two cases per month.

The Cardiac Society of Australia and New Zealand and the Australia and New Zealand Society of Cardiac and Thoracic Surgeons recently published recommendations for operator and institutional requirements [75]. That statement mirrors the recommendations above with a strong focus on a Heart Team approach and limiting the technology to centres with operator and institutional experience in treating high-risk cardiac patients. The recommendations also propose that clinical outcomes should be monitored through a national database, which the two societies are currently securing resources to implement.

While recommendations for TAVI programs are being formed there is still only limited access to the technology in Australia. In Australia the Therapeutic Goods Administration has approved the first-generation, 24F Edwards Sapien device and in May this year the Medtronic CoreValve for treatment of high-risk patients. Funding for these procedures is, however, still limited with no State or Federal programs. Access to new generation devices is likely even further afield as the time lag between device development, clinical trial and regulatory approval has proven to be protracted.

Conclusions

TAVI has gained widespread acceptance as an alternative treatment modality for high surgical risk patients with symptomatic severe aortic stenosis and is the preferred treatment

modality for appropriately selected extreme surgical risk patients.

The use of new generation devices with the ability to reposition and retrieve during deployment is likely to become more commonplace, driven by operator ease, preference and lower rates of peri-procedural complications in single-arm trials. Randomised trials comparing these devices to earlier generation prostheses will hopefully identify any superiority in efficacy or safety.

Clinical practice has seen a drift in treatment indications to a slightly lower risk and younger patients. While any drift of indication without sufficient evidence must be made cautiously, evidence by way of the SurTAVI and Partner 2A trials will hopefully be available soon. With new devices and increased experience we will hopefully see a reduction in what are already modest complication rates. Such a reduction in complication rates is imperative before TAVI is seen as an acceptable treatment alternative in lower risk, younger patients in whom surgical AVR already has a proven long-term track record of very low morbidity and mortality.

Thirteen years since the first clinical case of transcatheter aortic valve implantation the evidence base for efficacy and safety is impressive. Unfortunately the regulatory process in many countries including Australia lags behind current evidence, potentially denying timely and contemporary treatment to a substantial cohort of patients. Health and government agencies must work with device manufacturers and healthcare providers to ensure that potentially life-saving and life-changing TAVI technologies are available in a safe yet timely manner.

Acknowledgements

Dr Robert Gooley receives a postgraduate scholarship from the National Health and Medical Research Council of Australia.

References

[1] Cribier A, Eltchaninoff H, Bash A, Borenstein N, Tron C, Bauer F, et al. Percutaneous transcatheter implantation of an aortic valve prosthesis for calcific aortic stenosis: first human case description. Circulation 2002;106(24):3006–8.

[2] Iung B, Cachier A, Baron G, Messika-Zeitoun D, Delahaye F, Tornos P, et al. Decision-making in elderly patients with severe aortic stenosis: why are so many denied surgery? European Heart Journal 2005;26(24):2714–20.

[3] Leon MB, Smith CR, Mack M, Miller DC, Moses JW, Svensson LG, et al. Transcatheter aortic-valve implantation for aortic stenosis in patients who cannot undergo surgery. The New England Journal of Medicine 2010;363(17):1597–607.

[4] Popma JJ, Adams DH, Reardon MJ, Yakubov SJ, Kleiman NS, Heimansohn D, et al. Transcatheter aortic valve replacement using a self-expanding bioprosthesis in patients with severe aortic stenosis at extreme risk for surgery. Journal of the American College of Cardiology 2014;63(19):1972–81.

[5] Smith CR, Leon MB, Mack MJ, Miller DC, Moses JW, Svensson LG, et al. Transcatheter versus surgical aortic-valve replacement in high-risk patients. The New England Journal of Medicine 2011;364(23):2187–98.

[6] Adams DH, Popma JJ, Reardon MJ, Yakubov SJ, Coselli JS, Deeb GM, et al. Transcatheter aortic-valve replacement with a self-expanding prosthesis. The New England Journal of Medicine 2014;370(19):1790–8.

[7] Statistics ABo. Population By Age and Sex, Australia, States and Territories. Canberra, Australia: Australian Federal Government; 2014.

[8] Makkar RR, Fontana GP, Jilaihawi H, Kapadia S, Pichard AD, Douglas PS, et al. Transcatheter aortic-valve replacement for inoperable severe aortic stenosis. The New England Journal of Medicine 2012;366(18):1696–704.

[9] Thomas M, Schymik G, Walther T, Himbert D, Lefevre T, Treede H, et al. One-year outcomes of cohort 1 in the Edwards SAPIEN Aortic Bioprosthesis European Outcome (SOURCE) registry: the European registry of transcatheter aortic valve implantation using the Edwards SAPIEN valve. Circulation 2011;124(4):425–33.

[10] Schymik G, Lefevre T, Bartorelli AL, Rubino P, Treede H, Walther T, et al. European Experience With the Second-Generation Edwards SAPIEN XT Transcatheter Heart Valve in Patients With Severe Aortic Stenosis: 1-Year Outcomes From the SOURCE XT Registry. JACC Cardiovascular Interventions 2015;8(5):657–69.

[11] Holmes DR, editor. One-Year Outcomes from the STS/ACC Transcatheter Valve Therapy (TVT Registry. *American College of Cardiology*. Washington DC 2014.

[12] Linke A, Wenaweser P, Gerckens U, Tamburino C, Bosmans J, Bleiziffer S, et al. Treatment of aortic stenosis with a self-expanding transcatheter valve: the International Multi-centre ADVANCE Study. European Heart Journal 2014;35(38):2672–84.

[13] Barbanti M, Ussia GP, Cannata S, Giarratana A, Sgroi C, Tamburino C. 3-year outcomes of self-expanding Corevalve prosthesis - The Italian Registry. Annals of Cardiothoracic Surgery 2012;1(2):182–4.

[14] Tamburino C, Capodanno D, Ramondo A, Petronio AS, Ettori F, Santoro G, et al. Incidence and predictors of early and late mortality after transcatheter aortic valve implantation in 663 patients with severe aortic stenosis. Circulation 2011;123(3):299–308.

[15] Patsalis PC, Konorza TF, Al-Rashid F, Plicht B, Riebisch M, Wendt D, et al. Incidence, outcome and correlates of residual paravalvular aortic regurgitation after transcatheter aortic valve implantation and importance of haemodynamic assessment. EuroIntervention: journal of EuroPCR in collaboration with the Working Group on Interventional Cardiology of the European Society of Cardiology 2013;8(12):1398–406.

[16] Athappan G, Patvardhan E, Tuzcu EM, Svensson LG, Lemos PA, Fraccaro C, et al. Incidence, predictors, and outcomes of aortic regurgitation after transcatheter aortic valve replacement: meta-analysis and systematic review of literature. Journal of the American College of Cardiology 2013;61(15):1585–95.

[17] Eltchaninoff H, Prat A, Gilard M, Leguerrier A, Blanchard D, Fournial G, et al. Transcatheter aortic valve implantation: early results of the FRANCE (FRench Aortic National CoreValve and Edwards) registry. European Heart Journal 2011;32(2):191–7.

[18] Meredith IT, Walton A, Walters DL, Pasupati S, Muller DW, Worthley SG, et al. Mid-term Outcomes in Patients Following Transcatheter Aortic Valve Implantation in the CoreValve Australia and New Zealand Study. Heart, Lung and Circulation 2014.

[19] Walters DL, Sinhal A, Baron D, Pasupati S, Thambar S, Yong G, et al. Initial experience with the balloon expandable Edwards-SAPIEN Transcatheter Heart Valve in Australia and New Zealand: the SOURCE ANZ registry: outcomes at 30 days and one year. International Journal of Cardiology 2014;170(3):406–12.

[20] Mack MJ, Leon MB, Smith CR, Miller DC, Moses JW, Tuzcu EM, et al. 5-year outcomes of transcatheter aortic valve replacement or surgical aortic valve replacement for high surgical risk patients with aortic stenosis (PARTNER 1): a randomised controlled trial. Lancet 2015.

[21] Thourani V, editor. Three-Year Outcomes after Transcatheter or Surgical Aortic Valve Replacement in High-Risk Patients with Severe Aortic Stenosis. *ACC 2013*. San Francisco 2013.

[22] Kodali S, Pibarot P, Douglas PS, Williams M, Xu K, Thourani V, et al. Paravalvular regurgitation after transcatheter aortic valve replacement with the Edwards sapien valve in the PARTNER trial: characterizing patients and impact on outcomes. European Heart Journal 2015;36(7):449–56.

[23] Reardon M, editor. A randomized Comparison of Self-expanding Transcatheter and Surgical Aortic Valve Replacment in Patients with Severe Aortic Stenosis Deemed at increased Risk for Surgery 2-Year Outcomes. *ACC2015*. San Diego 2015.

[24] Arnold SV, Reynolds MR, Lei Y, Magnuson EA, Kirtane AJ, Kodali SK, et al. Predictors of poor outcomes after transcatheter aortic valve replacement: results from the PARTNER (Placement of Aortic Transcatheter Valve) trial. Circulation 2014;129(25):2682–90.

[25] Shahian DM, He X, Jacobs JP, Rankin JS, Welke KF, Edwards FH, et al. The STS AVR+CABG composite score: a report of the STS Quality

Measurement Task Force. The Annals of Thoracic Surgery 2014;97(5): 1604–9.
[26] Saffioti S, Burzotta F, Coluccia V, Trani C, Bruno P, Massetti M, et al. Usefulness of EuroSCORE systems for risk stratification. J Cardiovasc Med (Hagerstown) 2014.
[27] Stortecky S, Schoenenberger AW, Moser A, Kalesan B, Juni P, Carrel T, et al. Evaluation of multidimensional geriatric assessment as a predictor of mortality and cardiovascular events after transcatheter aortic valve implantation. JACC Cardiovascular Interventions 2012; 5(5):489–96.
[28] Green P, Woglom AE, Genereux P, Daneault B, Paradis JM, Schnell S, et al. The impact of frailty status on survival after transcatheter aortic valve replacement in older adults with severe aortic stenosis: a single-center experience. JACC Cardiovascular Interventions 2012;5(9):974–81.
[29] Puls M, Sobisiak B, Bleckmann A, Jacobshagen C, Danner BC, Hunlich M, et al. Impact of frailty on short- and long-term morbidity and mortality after transcatheter aortic valve implantation: risk assessment by Katz Index of activities of daily living. EuroIntervention: journal of EuroPCR in collaboration with the Working Group on Interventional Cardiology of the European Society of Cardiology 2014;10(5):609–19.
[30] Binder RK, Webb JG, Willson AB, Urena M, Hansson NC, Norgaard BL, et al. The Impact of Integration of a Multidetector Computed Tomography Annulus Area Sizing Algorithm on Outcomes of Transcatheter Aortic Valve Replacement: A Prospective, Multicenter, Controlled Trial. Journal of the American College of Cardiology 2013.
[31] Achenbach S, Schuhback A, Min JK, Leipsic J. Determination of the aortic annulus plane in CT imaging-a step-by-step approach. JACC Cardiovascular Imaging 2013;6(2):275–8.
[32] Willson AB, Webb JG, Gurvitch R, Wood DA, Toggweiler S, Binder R, et al. Structural integrity of balloon-expandable stents after transcatheter aortic valve replacement: assessment by multidetector computed tomography. JACC Cardiovascular Interventions 2012;5(5):525–32.
[33] Delgado V, Ng AC, van de Veire NR, van der Kley F, Schuijf JD, Tops LF, et al. Transcatheter aortic valve implantation: role of multi-detector row computed tomography to evaluate prosthesis positioning and deployment in relation to valve function. European Heart Journal 2010;31 (9):1114–23.
[34] Schultz CJ, Weustink A, Piazza N, Otten A, Mollet N, Krestin G, et al. Geometry and degree of apposition of the CoreValve ReValving system with multislice computed tomography after implantation in patients with aortic stenosis. Journal of the American College of Cardiology 2009;54(10):911–8.
[35] Gooley RP, Cameron JD, Meredith IT. Assessment of the geometric interaction between the lotus transcatheter aortic valve prosthesis and the native ventricular aortic interface by 320-multidetector computed tomography. JACC Cardiovascular Interventions 2015;8(5):740–9.
[36] Barbanti M, Yang TH, Rodes Cabau J, Tamburino C, Wood DA, Jilaihawi H, et al. Anatomical and procedural features associated with aortic root rupture during balloon-expandable transcatheter aortic valve replacement. Circulation 2013;128(3):244–53.
[37] Bleiziffer S, Ruge H, Horer J, Hutter A, Geisbusch S, Brockmann G, et al. Predictors for new-onset complete heart block after transcatheter aortic valve implantation. JACC Cardiovascular Interventions 2010;3(5): 524–30.
[38] Binder RK, Webb JG, Toggweiler S, Freeman M, Barbanti M, Willson AB, et al. Impact of post-implant SAPIEN XT geometry and position on conduction disturbances, hemodynamic performance, and paravalvular regurgitation. JACC Cardiovascular Interventions 2013;6(5):462–8.
[39] Binder RK, Webb JG, Willson AB, Urena M, Hansson NC, Norgaard BL, et al. The impact of integration of a multidetector computed tomography annulus area sizing algorithm on outcomes of transcatheter aortic valve replacement: a prospective, multicenter, controlled trial. Journal of the American College of Cardiology 2013;62(5):431–8.
[40] Arbatli H, Yilmaz O, Cikrikcioglu M. Alternative safer approach through the carotid artery for transcatheter aortic valve implantation. The Journal of Thoracic and Cardiovascular Surgery 2011;141(3):847. author reply -8.
[41] Azmoun A, Amabile N, Ramadan R, Ghostine S, Caussin C, Fradi S, et al. Transcatheter aortic valve implantation through carotid artery access under local anaesthesia. European Journal of Cardio-thoracic Surgery: official journal of the European Association for Cardio-thoracic Surgery 2014.
[42] Martinez-Clark PO, Singh V, Cadena JA, Cucalon Reyes AM, Gallegos C, Dager A, et al. Transcaval Retrograde Transcatheter Aortic Valve Replacement for Patients With No Other Access: First-in-Man Experience With CoreValve. JACC Cardiovascular Interventions 2014;7(9):1075–7.
[43] Genereux P, Webb JG, Svensson LG, Kodali SK, Satler LF, Fearon WF, et al. Vascular complications after transcatheter aortic valve replacement: insights from the PARTNER (Placement of AoRTic TraNscathetER Valve) trial. Journal of the American College of Cardiology 2012; 60(12):1043–52.
[44] Toggweiler S, Gurvitch R, Leipsic J, Wood DA, Willson AB, Binder RK, et al. Percutaneous aortic valve replacement: vascular outcomes with a fully percutaneous procedure. Journal of the American College of Cardiology 2012;59(2):113–8.
[45] Sharp AS, Michev I, Maisano F, Taramasso M, Godino C, Latib A, et al. A new technique for vascular access management in transcatheter aortic valve implantation. Catheterization and Cardiovascular Interventions: official journal of the Society for Cardiac Angiography & Interventions 2010;75(5):784–93.
[46] Genereux P, Kodali S, Leon MB, Smith CR, Ben-Gal Y, Kirtane AJ, et al. Clinical outcomes using a new crossover balloon occlusion technique for percutaneous closure after transfemoral aortic valve implantation. JACC Cardiovascular Interventions 2011;4(8):861–7.
[47] Kahlert P, Knipp SC, Schlamann M, Thielmann M, Al-Rashid F, Weber M, et al. Silent and apparent cerebral ischemia after percutaneous transfemoral aortic valve implantation: a diffusion-weighted magnetic resonance imaging study. Circulation 2010;121(7):870–8.
[48] Rodes-Cabau J, Dumont E, Boone RH, Larose E, Bagur R, Gurvitch R, et al. Cerebral embolism following transcatheter aortic valve implantation: comparison of transfemoral and transapical approaches. Journal of the American College of Cardiology 2011;57(1):18–28.
[49] Fairbairn TA, Mather AN, Bijsterveld P, Worthy G, Currie S, Goddard AJ, et al. Diffusion-weighted MRI determined cerebral embolic infarction following transcatheter aortic valve implantation: assessment of predictive risk factors and the relationship to subsequent health status. Heart 2012;98(1):18–23.
[50] Rodes-Cabau J, Kahlert P, Neumann FJ, Schymik G, Webb JG, Amarenco P, et al. Feasibility and Exploratory Efficacy Evaluation of the Embrella Embolic Deflector System for the Prevention of Cerebral Emboli in Patients Undergoing Transcatheter Aortic Valve Replacement: The PROTAVI-C Pilot Study. JACC Cardiovascular Interventions 2014; 7(10):1146–55.
[51] Linke A, editor. CLEAN-TAVI: A prospective, randomized trial of cerebral embolic protection in high-risk patients with aortic stenosis undergoing transcatheter aortic valve replacement. *TCT 2014*. Washington DC 2014.
[52] Eggebrecht H, Schmermund A, Voigtlander T, Kahlert P, Erbel R, Mehta RH. Risk of stroke after transcatheter aortic valve implantation (TAVI): a meta-analysis of 10,037 published patients. EuroIntervention: journal of EuroPCR in collaboration with the Working Group on Interventional Cardiology of the European Society of Cardiology 2012;8(1):129–38.
[53] Kodali S, editor. Sapien 3: Thirty-day outcomes. San Diego; 2015.
[54] Wong DT, Bertaso AG, Liew GY, Thomson VS, Cunnington MS, Richardson JD, et al. Relationship of aortic annular eccentricity and paravalvular regurgitation post transcatheter aortic valve implantation with CoreValve. The Journal of Invasive Cardiology 2013;25(4):190–5.
[55] Hansson NC, Thuesen L, Hjortdal VE, Leipsic J, Andersen HR, Poulsen SH, et al. 3-Dimensional multidetector computed tomography versus conventional 2-dimensional transesophageal echocardiography for annular sizing in transcatheter aortic valve replacement: Influence on post-procedural paravalvular aortic regurgitation. Catheterization and Cardiovascular Interventions: official journal of the Society for Cardiac Angiography & Interventions 2013.
[56] Meredith IT, Dumonteil WD, Worthley N, Tchetche SG, Manoharan D, Blackman G, et al. Transcatheter Aortic Valve Replacement for Severe Symptomatic Aortic Stenosis Using a Repositionable Valve System: 30-Day Primary Endpoint Results From the REPRISE II Study. J Am Coll of Cardiol 2014;64(13):1339–48.
[57] Siontis GC, Juni P, Pilgrim T, Stortecky S, Bullesfeld L, Meier B, et al. Predictors of permanent pacemaker implantation in patients with severe aortic stenosis undergoing TAVR: a meta-analysis. Journal of the American College of Cardiology 2014;64(2):129–40.
[58] Munoz-Garcia AJ, Hernandez-Garcia JM, Jimenez-Navarro MF, Alonso-Briales JH, Dominguez-Franco AJ, Fernandez-Pastor J, et al. Factors predicting and having an impact on the need for a permanent pacemaker after CoreValve prosthesis implantation using the new Accutrak delivery catheter system. JACC Cardiovascular Interventions 2012;5(5):533–9.
[59] Chieffo A, Buchanan GL, Van Mieghem NM, Tchetche D, Dumonteil N, Latib A, et al. Transcatheter aortic valve implantation with the Edwards SAPIEN versus the Medtronic CoreValve Revalving system devices: a multicenter collaborative study: the PRAGMATIC Plus Initiative

(Pooled-RotterdAm-Milano-Toulouse In Collaboration). Journal of the American College of Cardiology 2013;61(8):830–6.
[60] Simms AD, Hogarth AJ, Hudson EA, Worsnop VL, Blackman DJ, O'Regan DJ, et al. Ongoing requirement for pacing post-transcatheter aortic valve implantation and surgical aortic valve replacement. Interactive Cardiovascular and Thoracic Surgery 2013;17(2):328–33.
[61] Makkar RR, Jilaihawi H, Chakravarty T, Fontana GP, Kapadia S, Babaliaros V, et al. Determinants and outcomes of acute transcatheter valve-in-valve therapy or embolization: a study of multiple valve implants in the U.S. PARTNER trial (Placement of AoRTic TraNscathetER Valve Trial Edwards SAPIEN Transcatheter Heart Valve). Journal of the American College of Cardiology 2013;62(5):418–30.
[62] IT M, editor. Early Results from the CoreValve Evolut R CE Study. *American College of Cadiology 2015*; 2015.
[63] Schofer J, Colombo A, Klugmann S, Fajadet J, DeMarco F, Tchetche D, et al. Prospective multicenter evaluation of the direct flow medical transcatheter aortic valve. Journal of the American College of Cardiology 2014;63(8):763–8.
[64] Manoharan G, Spence MS, Rodes-Cabau J, Webb JG. St Jude Medical Portico valve. EuroIntervention: journal of EuroPCR in collaboration with the Working Group on Interventional Cardiology of the European Society of Cardiology 2012;8(Suppl Q):Q97–101.
[65] Banbury MK, Cosgrove 3rd DM, White JA, Blackstone EH, Frater RW, Okies JE. Age and valve size effect on the long-term durability of the Carpentier-Edwards aortic pericardial bioprosthesis. The Annals of Thoracic Surgery 2001;72(3):753–7.
[66] David TE, Armstrong S, Maganti M. Hancock II bioprosthesis for aortic valve replacement: the gold standard of bioprosthetic valves durability? The Annals of Thoracic Surgery 2010;90(3):775–81.
[67] McClure RS, Narayanasamy N, Wiegerinck E, Lipsitz S, Maloney A, Byrne JG, et al. Late outcomes for aortic valve replacement with the Carpentier-Edwards pericardial bioprosthesis: up to 17-year follow-up in 1,000 patients. The Annals of Thoracic Surgery 2010;89(5):1410–6.
[68] Eggebrecht H, Schafer U, Treede H, Boekstegers P, Babin-Ebell J, Ferrari M, et al. Valve-in-valve transcatheter aortic valve implantation for degenerated bioprosthetic heart valves. JACC Cardiovascular Interventions 2011;4(11):1218–27.
[69] Dvir D, Webb JG, Bleiziffer S, Pasic M, Waksman R, Kodali S, et al. Transcatheter aortic valve implantation in failed bioprosthetic surgical valves. JAMA: The Journal of the American Medical Association 2014;312 (2):162–70.
[70] Seiffert M, Conradi L, Baldus S, Schirmer J, Knap M, Blankenberg S, et al. Transcatheter mitral valve-in-valve implantation in patients with degenerated bioprostheses. JACC Cardiovascular Interventions 2012;5(3): 341–9.
[71] Treede H, Mohr FW, Baldus S, Rastan A, Ensminger S, Arnold M, et al. Transapical transcatheter aortic valve implantation using the JenaValve system: acute and 30-day results of the multicentre CE-mark study. European Journal of Cardio-thoracic Surgery: official journal of theEuropean Association for Cardio-thoracic Surgery 2012;41(6): e131–8.
[72] Wijesinghe N, Ye J, Rodes-Cabau J, Cheung A, Velianou JL, Natarajan MK, et al. Transcatheter aortic valve implantation in patients with bicuspid aortic valve stenosis. JACC Cardiovascular Interventions 2010; 3(11):1122–5.
[73] Bauer T, Linke A, Sievert H, Kahlert P, Hambrecht R, Nickenig G, et al. Comparison of the effectiveness of transcatheter aortic valve implantation in patients with stenotic bicuspid versus tricuspid aortic valves (from the German TAVI Registry). The American Journal of Cardiology 2014;113(3):518–21.
[74] Tommaso CL, Bolman 3rd RM, Feldman T, Bavaria J, Acker MA, Aldea G, et al. Multisociety (AATS, ACCF, SCAI, and STS) expert consensus statement: operator and institutional requirements for transcatheter valve repair and replacement, part 1: transcatheter aortic valve replacement. Journal of the American College of Cardiology 2012;59(22): 2028–42.
[75] Walters DL, Webster M, Pasupati S, Walton A, Muller D, Stewart J, et al. Position statement for the operator and institutional requirements for a transcatheter aortic valve implantation (TAVI) program. Heart, Lung and Circulation 2015;24(3):219–23.

Chapter 1C – The Lotus Transcatheter Aortic Valve Prosthesis: A Novel TAVR Device

Monash University

Declaration for Thesis Chapter 1C

The Lotus Transcatheter Aortic Valve: A Next---Generation Repositionable, Resheathable and Recapturable Prosthesis

Declaration by candidate

In the case of Chapter 1C, the nature and extent of my contribution to the work was the following:

Nature of contribution	Extent of contribution (%)
Review of existing literature, planning study protocol, collection and interpretation of data writing manuscript, creation of figures, editing manuscript	80%

The following co---authors contributed to the work.

Name	Nature of contribution	Extent of contribution (%)
Prof Ian Meredith	Planning study protocol, interpretation of data, writing and editing manuscript	10%
Dr Paul Antonis	Planning study protocol, interpretation of data, writing and editing manuscript	10%

The undersigned hereby certify that the above declaration correctly reflects the nature and extent of the candidate's and co---authors' contributions to this work.

Candidate's Signature	[redacted]	**Date** 12/04/2016

Main Supervisor's Signature	[redacted]	**Date** 12/04/2016

Preface

While the previous work described the evolution of TAVR to its current position as a standard treatment modality for appropriately selected patients with aortic stenosis, it also highlighted a number of limitations intrinsic to current generation transcatheter devices.

This has led to an increasing number of 'new generation' devices entering trial and clinical practice. Each device has been designed with features purported to either increase safety, improve efficacy, increase ease of implantation or indeed in most cases achieve all three. As with most facets of medical engineering, however, gains in one procedural aspect may be offset by losses in another. The Lotus Valve System is a new---generation mechanically---expanded device which includes a number of novel design features such as full repositionability, re---sheathability, a pre---shaped delivery catheter and an external adaptive seal.

The following work, published in *Interventional Cardiology*, reviews the unique constellation of design features and the resultant clinical utility of the Lotus Valve System. This work formed one of the first clinical reviews of this technology. Throughout this thesis assessment of the Lotus Valve System by MDCT imaging will be used to highlight its interaction with the aortoventricular interface anatomy and how this translates to differences in its safe and effective clinical utilisation.

Interventional Cardiology

The Lotus transcatheter aortic valve: a next-generation repositionable, resheathable and recapturable prosthesis

Symptomatic severe aortic stenosis occurs in 2–4% of people aged over 65 years, with calcific degeneration being the predominant etiology in the developed world. Surgical valve replacement has been and remains the gold-standard treatment modality, yet a significant number of high-risk individuals are denied or refuse this potentially life-saving treatment. Transcatheter aortic valve replacement has proven efficacy in this high-risk cohort. Current-generation transcatheter aortic valve replacement devices, however, have significant limitations. The Lotus transcatheter device represents an evolution of this technology that allows full resheathing, repositioning and retrieval, which together with features designed to minimize para-prosthetic regurgitation address a number of the limitations of first-generation devices.

Keywords: AORTIC STENOSIS s "OSTON 3CIENTIIC ,OTUS VALVE s TRANSCATHETER AORTIC VALVE REPLACEMENT s TRANSCATHETER AORTIC VALVE IMPLANTATION s VALVULAR HEART DISEASE

Robert Gooley*[,1,2], Paul Antonis[1,2] & Ian Meredith[1,2]
[1]-ONASH(EART, -ONASH (EALTH, #LAYTON, !USTRALIA
[2]-ONASH #ARDIOVASCULAR 2ESEARCH #ENTRE, -ONASH 5NIVERSITY, #LAYTON, !USTRALIA
*!UTHOR FOR CORRESPONDENCE:
4EL.: +61 3 9594 6666
&AX: +61 3 9594 6239
ROBERTGOOLEY HOTMAIL.COM

Background

Aortic stenosis due to calcific degeneration occurs with a prevalence of 2 – 4% among people over 65 years. While surgical aortic valve replacement remains the gold-standard treatment, a significant number of patients decline or are denied surgery due to actual or perceived risks [1]. Transcatheter aortic valve replacement (TAVR) is an accepted treatment alternative in appropriately selected high-risk patients [2] and nonsurgical candidates [3].

Second-generation TAVR devices have been developed with design features aimed to overcome some of the limitations observed with fi st-generation devices. The Lotus prosthesis utilizes a unique method of deployment, which together with other device features aims to improve procedural safety and efficacy. The device demonstrates early function following implantation, and is fully repositionable, resheathable and retrievable. The clinical efficacy and safety of the Lotus device has been assessed in the REPRISE clinical trial program.

Current devices & limitations

An increasing number of TAVR devices are entering trial and clinical practice. The majority of worldwide experience, however, remains with the Sapien (Edwards Lifesciences, CA, USA) and CoreValve (Medtronic, MN, USA) devices. Both devices have proven efficacy and safety in high- and extreme-risk patients but a number of limitations remain [4].

Second-generation devices have been designed to overcome some of these limitations. The Portico (St Jude Medical, MN, USA) and Direct Flow (Direct Flow Medical Inc., CA, USA) have received approval (CE mark) for clinical use in Europe while a number of others remain in trial phase.

Positioning

Achieving an optimal deployment posi- tion is imperative, as it has been shown to correlate with outcomes such as degree of para-prosthetic aortic regurgitation (PAR) and pacing requirement. First-generation devices, however, are not truly repositionable or recapturable.

Future Medicine part of fsg

Slight repositioning of the CoreValve is possible via indirect tension on the delivery catheter, although this increases the risk of inadvertent device migration or embolization. Once the balloon expandable, Sapien valve is deployed it cannot be further maneuvered percutaneously. Accurate positioning is, therefore, reliant on initial placement and the use of rapid ventricular pacing during deployment to maximize device stability.

The Portico device is retrievable to the point of device functionality although it remains incompletely expanded in the outflow portion. The Direct Flow prosthesis can be fully expanded into its final position prior to exchange of the pressurized saline for the permanent polymer. This affords the ability to assess the functioning device and reposition or remove the prosthesis if required.

Para-PAR

PAR following TAVR with current-generation devices correlates with morbidity and mortality [2]. PAR results from a number of factors. First, placement of circular TAVR devices within noncircular native annuli often results in residual paravalve interstices [5,6]. Further to this, the presence of eccentric or protuberant calcification at the level of the annulus or sub-annular level can prohibit complete sealing.

Efforts to reduce PAR with first-generation devices focused on oversizing the prosthesis in order to create better apposition between valve frame and annulus circumferentially. This practice, however, may increase the risk of annular injury/rupture, the need for pacing, sinus obliteration and coronary occlusion [7,8]. Second-generation devices utilize features such as sealing skirts or more precise placement to overcome PAR.

Conduction disturbance

Reported rates of requirement for pacing following TAVR vary between studies and between device types. Contemporary pacing rates are generally declining although rates following CoreValve implantation are still reported at 10 – 25% [9–11] and following Sapien at 4 – 8% [11–13]. The reduction in pacing requirement has been driven by improved device positioning, avoidance of excessive oversizing and higher operator thresholds for pacemaker implantation [9,10,14].

Stroke & transient ischemic attacks

The reported rates of new neurological events have declined [2,15]. This has been variably attributed to improved operator technique, selective avoidance of procedural steps (e.g., predilatation and postdilation) and lower profile devices [16].

Despite this, contemporary MRI studies have demonstrated very high rates of subclinical cerebral lesions [17,18]. Studies investigating the efficacy of embolic protection devices have likewise shown high rates of MRI detected lesions, although with a suggestion that the volume of such lesions may be reduced [19]. This has not yet translated to a proven reduction in clinical neurological events.

With the advent of repositionable and resheath- able devices concerns have/were raised that increased manipulation of the device in the annulus may result in higher rates of stroke. To date, this has not been demonstrated in reported clinical trials. It is possible that nontraumatic resheathing mechanisms may actually result in less debris embolization than gross traction, which is often applied to first-generation devices in an attempt to repositioning.

Lotus transcatheter valve design

The Lotus transcatheter prosthesis is a novel device with a number of features designed to improve ease of use, efficacy and safety (Figure 1).

Frame

The frame of the prosthesis is braided from a single nitinol wire, the ends of which are joined by a radio-opaque, tantalum marker. The tantalum marker is positioned at the mid-frame height and acts as a fluoroscopic aid for accurate valve positioning. The orientation of the tantalum marker also assists the operator in understanding delivery catheter orientation and thus allowing the operator to maneuver the catheter if necessary when dealing with tortuous anatomy.

Leaflets

Three bovine pericardial leaflets are hand-sewn onto the valve frame. The leaflets are positioned within the inflow portion of the frame to achieve a true annular position once deployed.

Adaptive seal

A blended polymer membrane surrounds the lower half of the Lotus device. As the device shortens and radially expands this membrane concertinas and occupies any small interstices that may remain between the annulus and the frame that could result in PAR.

Delivery catheter & premounted valve

The Lotus prosthesis is pre-mounted on the Convex Catheter™, which reduces device preparation time in the catheterization laboratory (Figure 2). The catheter is preshaped and has a lubricious coating, which together allow steerable passage through peripheral tortuosity and across the aortic arch. The preshaped catheter also aids coaxial positioning of the device in the aortic flow plane. On unsheathing, the valve func-

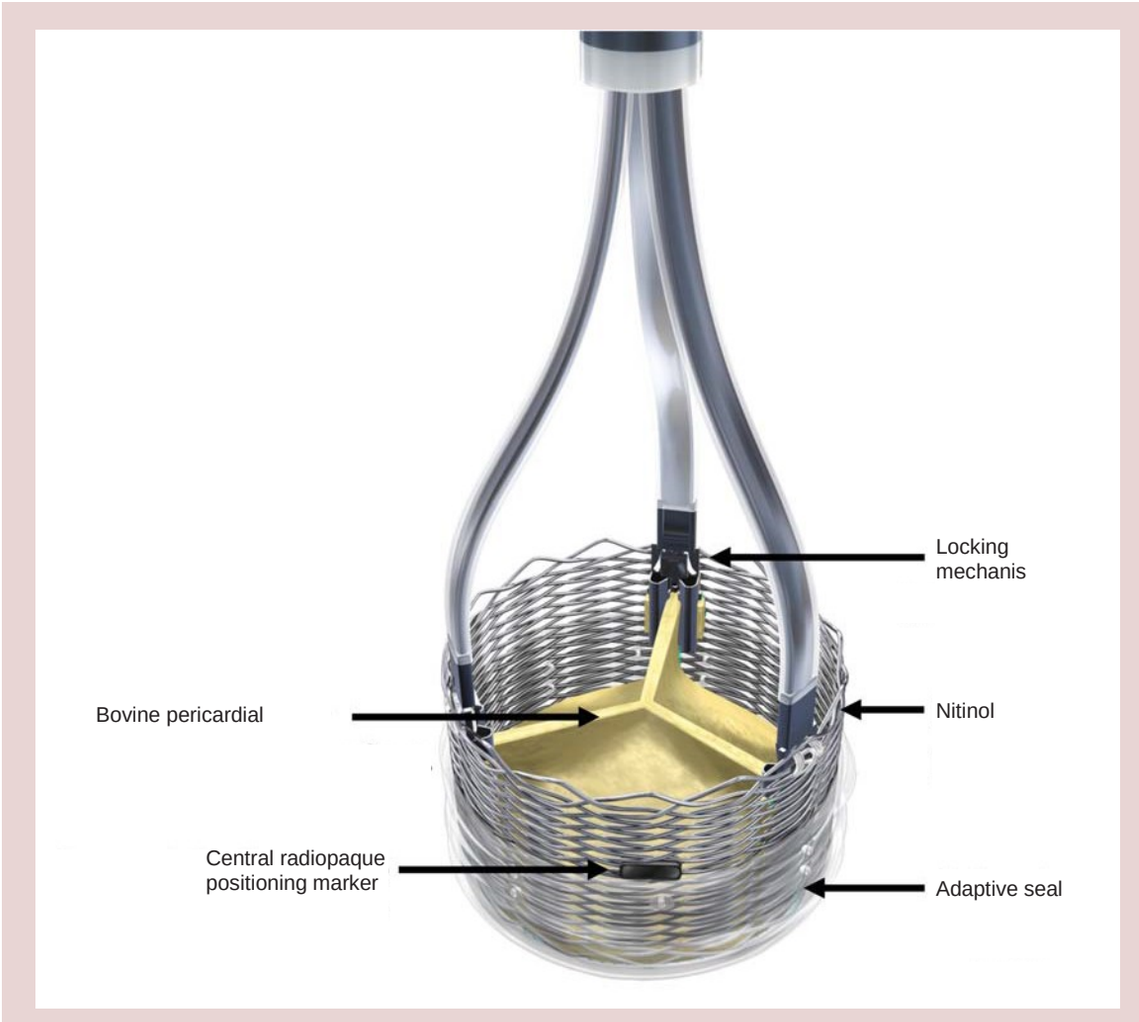

Figure 1. The Lotus transcatheter prosthesis with its unique design features.

tions immediately, thus reducing the likelihood of hemodynamic instability. Rapid pacing is not required.

The 23-mm Lotus system is compatible with an 18-Fr proprietary femoral sheath while the 27-mm Lotus system requires a 20-Fr proprietary femoral sheath. At present, due to the pre-shaped Convex Catheter, the device is only deployed from the femoral route.

Locking mechanism

The Lotus prosthesis is neither balloon nor self-expanding but utilizes a unique controlled mechanical expansion mechanism. Counterclockwise rotation of the Lotus controller results in shortening of the prosthesis along three mandrels, which are spaced evenly around the frame. This brings the ventricular and aortic portions of the locking mechanism together. As the frame shortens from its constrained form to the final height of 19 mm, it radially expands to its final diameter of 23 or 27 mm (Figure 3).

The device is fully repositionable, resheathable and retrievable even from the fully expanded and locked position. This allows complete assessment of the expanded device by fluoroscopy, angiography and/or echocardiography prior to final release.

REPRISE trials

The clinical efficacy and safety of the Lotus device is currently being investigated in the REPRISE clinical trial program [20].

REPRISE I

REPRISE I, a first-in-man feasibility trial, enrolled 11 patients at three Australian centers. The primary end point was clinical procedural success at discharge or 7 days, defined as successful device implantation without in-hospital major cardiovascular or cerebrovascular events using Valve Academic Research Consortium definitions [21].

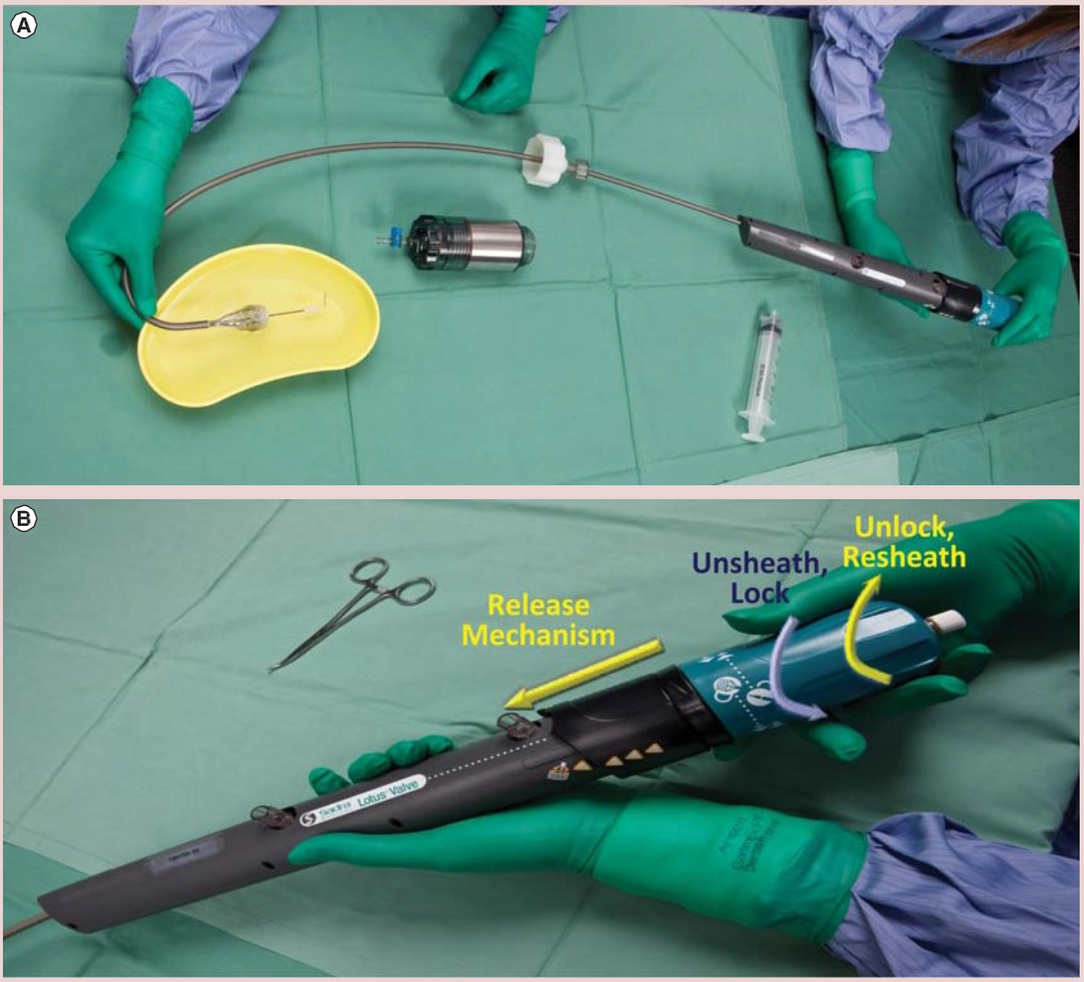

Figure 2. The premounted Lotus transcatheter aortic valve prosthesis. (A) The Lotus transcatheter prosthesis is premounted on the Convex Catheter™, saving device preparation time. **(B)** Controlled mechanical expansion is achieved by counterclockwise rotation of the Lotus controller. Clockwise rotation allows resheathing, repositioning or retrieval. The safety collar protects the release ring and prevents premature release.

The results of REPRISE I through 1-year postprocedure were recently published [20]. All patients were female and received a 23-mm device. The mean Society of Thoracic Surgeons score was 4.9 ± 2.5 and mean logistic EuroSCORE 9.5 ± 4.4. All patients were deemed to be high risk by institutional Heart Teams.

The primary end point was met in nine of 11 patients (81.8%) at discharge. One patient suffered a major stroke and one patient had a mean trans-prosthesis gradient of 22 mmHg, which while functioning nor- mally with a valve area of 1.6 cm^2 was above the speci- fied Valve Academic Research Consortium threshold of 20 mmHg for device success.

There were very low rates of PAR with only two cases deemed mild, one trivial and the remainder none. Four patients (36.4%) required implantation of a permanent pacemaker. There was a reduction in mean aortic gradient from 53.9 ± 20.9 to 13.7 ± 3.7 mmHg at discharge and an increase in aortic valve area from 0.68 ± 0.19 to 1.53 ± 0.18 cm^2.

All patients were alive at 12 months with no additional strokes. The observed changes in mean aortic gradient and aortic valve area at discharge were sustained.

REPRISE II & REPRISE II Extension

The REPRISE II CE mark trial enrolled 120 patients at Australian and European centers. It was a single-arm study with similar inclusion criteria to REPRISE I but with the addition of a 27-mm device. The primary performance end point was mean aortic pressure gradient at 30 days and the primary safety end point was all-cause mortality at 30 days.

The primary end point results were presented at Transcatheter Cardiovascular Therapeutics 2013. More

than half (56.7%) of participants were female. The mean Society of Thoracic Surgeons score was 7.1 ± 4.6 and mean EuroSCORE II 6.9 ± 5.8. These risk scores are in keeping with those in the recently published CoreValve IDE trial [22] and many contemporary registries. To ensure that subjects were at high surgical risk, however, a number of frailty indices including gait speed, handgrip strength, Charlson Index and Katz Index were collected.

The performance end point was met with a reduction in mean gradient from 46.4 ± 15.0 to 11.5 ± 5.2 mmHg ($p < 0.001$ compared with a performance goal of 18.0 mmHg) and an increase in aortic valve area from 0.7 ± 0.2 cm^2 to 1.7 ± 0.4 cm^2. There were five (4.2%) deaths at 30 days and two (1.7%) disabling strokes.

Permanent pacemaker implantation was required in 34 patients (28.6%) with approximately half of these cases occurring in the setting of significant oversizing [23]. Of 103 echocardiograms performed at 30 days, 96 were evaluable for PAR. None of the patients had severe PAR, 1% had moderate, 16% had mild, 5% had trivial and 78% had no PAR as adjudicated by an independent core laboratory.

The REPRISE II trial included an evaluation of the device by the implanting investigators. The investigators considered the major advantages of the Lotus prosthesis, as demonstrated in the REPRISE trials, to be early valve function during the implantation process and very low PAR rates. The investigators attributed the latter to the ability to accurately position and reposition the device as well as the influence of the adaptive seal.

The REPRISE II Extension study is ongoing with plans to extend the REPRISE II cohort by 130 patients.

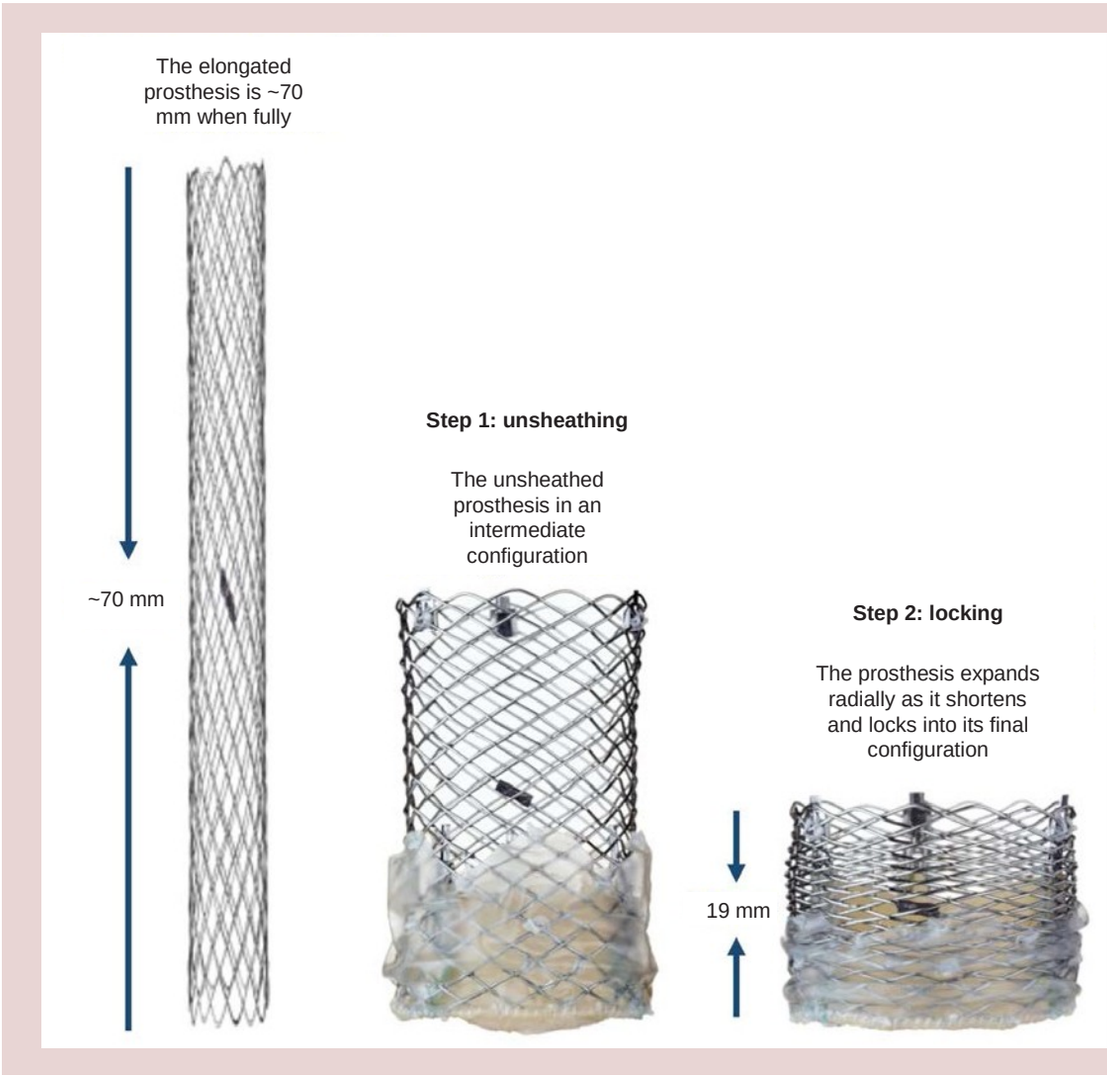

Figure 3. During controlled mechanical expansion the Lotus device shortens from approximately 70 mm to its final height of 19 mm as it radially expands to it's final diameter of 23 or 27 mm.

REPRISE III

REPRISE III is a planned global randomized pivotal study that will compare the Lotus device to a contemporary competitor device. Enrollment is planned to commence in 2014, and will also include a 25-mm diameter valve.

Respond

The Lotus device obtained CE mark in October 2013 and the first commercial device was implanted in November 2013. Real-world safety and efficacy data will be collected in the post-market RESPOND study, which will also include a 25-mm diameter valve and is expected to commence in 2014.

Procedural details

Preprocedural anatomical assessment is critical to efficacious and safe valve deployment. Patients undergo echocardiographic, angiographic and multidetector computed tomographic assessment to determine anatomical suitability while institutional Heart Teams and an independent clinical review committee adjudicate clinical suitability.

A description of the Lotus transcatheter valve system has previously been published [24]. The Lotus transcatheter device is deployed via the femoral access route. The 23-mm device is delivered via an 18-Fr proprietary Lotus introducer while the 27-mm device requires a 20-Fr Lotus introducer.

In the REPRISE I and REPRISE II trials, an initial balloon valvuloplasty was performed, although this is not mandated in commercial use. The preshaped Convex Catheter delivery system is used to steer through any peripheral tortuosity and across the aortic arch. At this point the catheter shape allows coaxial positioning of the device in the aortic flow plane. The prosthesis is gradually deployed by counterclockwise rotation of the Lotus controller. This results in shortening and radial expansion of the prosthesis. The mid-frame height tantalum marker is used to guide positioning during this deployment phase (Figure 4).

The unique locking mechanism of the Lotus device facilitates partial or complete resheathing and hence repositioning or retrieval. The prosthesis can, therefore, be assessed for anatomical and functional integrity while in the fully expanded position and any fine adjustments

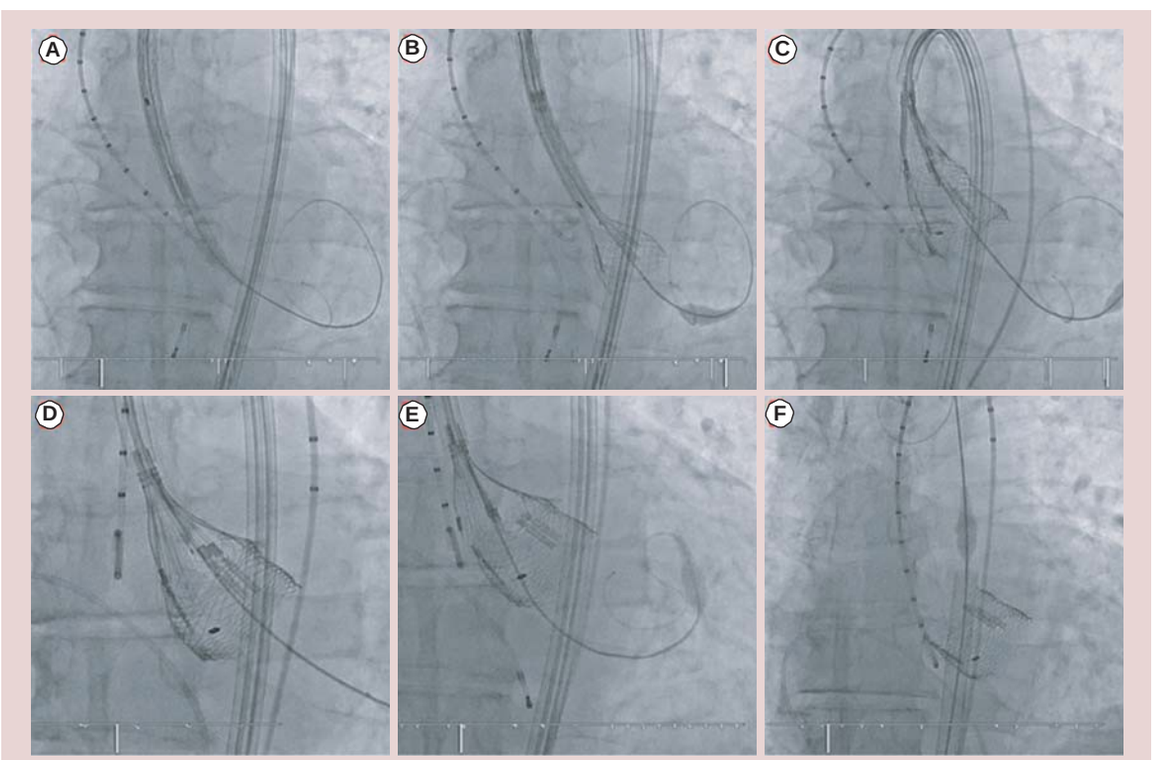

Figure 4. An example of the typical deployment steps as seen fluoroscopically. (A) The delivery catheter is positioned across the aortic valve following initial balloon valvuloplasty. **(B)** The device is unsheathed by counterclockwise rotation of the Lotus controller. **(C)** The device is unsheathed until the mid-frame Tantalum marker reaches the mid-leaflet position. **(D)** The locking posts on the inflow portion of the valve come together with the locking buckles on the outflow portion of the valve. Even in this locked position the valve is fully resheathable. **(E)** The valve is released from the delivery catheter. **(F)** The nose cone is recaptured and the delivery system removed.

Table 1. Comparison of Lotus with US FDA/CE mark transcatheter aortic valve replacement device s.

	Approval	Frame	Leaflets	Sheath size (Fr)	Prosthesis size (mm)	Annulus size (mm)	Mechanism of deployment	Access site	Ref.
Medtronic CoreValve	US FDA CE mark	Nitinol	Porcine Pericardium	18	23 26 29 31	18–20 20–23 23–27 26–29	Self-expanding	Femoral Subclavian Direct aortic	[25]
Edwards Sapien XT	FDA CE mark	CoCr	Bovine Pericardium	16† 18† 20†	23 26 29	18–22 21–25 24–27	Balloon expandab le	Femoral Apical Direct aortic	[26]
Direct Flow Medical Inc. TAV System	CE mark	Dacron Polymer	Bovine Pericardium	18	25 27 29	21–24 24–26 26–28	Pressurized inflation of inflow and outflow rings	Femoral	[27]
St Jude Medical Portico	CE mark	Nitinol	Bovine Pericardium	18	23 25	19–21 21–23	Self-expanding	Femoral	[28]
Boston Scientific LOTUS	CE mark	Nitinol	Bovine Pericardium	18 20	23 25‡ 27	19–23 23–27	Mechanically expanded	Femoral	[20]

†2EPRESENTS SIZE OF %DWARDS' PROPRIETARY EXPANDABLE SHEATH (E3HEATH).
‡25-MM ,OTUS PROSTHESIS WILL BE AVAILABLE IN THE SECOND QUARTER OF 2014.
#O#R: #OBALT CHROMIUM; 4!62: 4RANSCATHETER AORTIC VALVE REPLACEMENT.

made prior to final release. If the position needs to be altered, simple clockwise rotation of the Lotus controller results in partial or full resheathing, at which point the position can be optimized or the device removed.

Alternative devices

The Lotus device enters the commercial market in Europe at a time when other second generation devices have also become available along with the existing first generation CoreValve and Sapien prostheses (Table 1).

How the Lotus device fits in contemporary practice

The Lotus 23- and 27-mm devices are currently CE mark-approved for use in Europe. The Lotus device is not approved for clinical use in the USA although the planned REPRISE III IDE trial will enroll at centers in the USA with the aim of obtaining US FDA approval.

Conclusion

The Lotus prosthesis is a second-generation fully resheathable, repositionable and retrievable TAVR device. Through the REPRISE suite of trials it has proven to have very high rates of device and procedural success with an excellent safety and efficacy profile. A modest pacing rate may be reduced with the advent of further device sizes negating the degree of oversizing. The near absence of significant PAR, in the reported trials to date, suggests that this previous Achilles heel of TAVR may have been overcome.

Future perspective

TAVR is currently limited to treatment of high and extreme surgical risk populations. The extrapola- tion of current generation TAVR devices to lower risk cohorts has been limited by modest yet signifi- cant complication rates. The Lotus valve represents a next-generation device that may overcome some of these obstacles through its ability to be fully reposi- tioned and retrieved in order to achieve ideal posi- tioning and to allow function interrogation prior to release. This together with design features such as the adaptive seal, which has proven in the REPRISE suit of trials to contribute to very low rates of signifi- cant PAR, may result in improved outcomes and the extrapolation of TAVR into a broader population.

Financial & competing interests disclosure

) -EREDITH AND 0 !NTONIS REPORT RECEIVING CONSULTING FEES FROM "OSTON 3CIENTIIC.)N ADDITION TO THE PEER-REVIEW PROCESS, WITH THE AUTHOR(S) CONSENT, THE MANUFACTURER OF THE PRODUCT(S) DISCUSSED IN THIS ARTICLE WAS GIVEN THE OPPORTUNITY TO REVIEW THE MANUSCRIPT FOR FACTUAL ACCURACY. #HANGES WERE MADE AT THE DISCRETION OF THE AUTHOR(S) AND BASED ON SCIENTIIC OR EDITORIAL MERIT ONLY. 4HE AUTHORS HAVE NO OTHER RELEVANT AFILIATIONS OR INANCIAL INVOLVEMENT WITH ANY ORGANIZATION OR ENTITY WITH A INANCIAL INTEREST IN OR INANCIAL CONmICT WITH THE SUBJECT MATTER OR MATERIALS DISCUSSED IN THE MANUSCRIPT APART FROM THOSE DISCLOSED.

- O WRITING ASSISTANCE WAS UTILIZED IN THE PRODUCTION OF THIS MANUSCRIPT.

Executive summary

Background
- Transcatheter aortic valve replacement (TAVR) is an acceptable treatment modality in high- and extreme-risk patients.
- The Lotus TAVR prosthesis is a new-generation device that has CE mark in Europe.

Current devices & limitations
- First-generation devices have modest yet significant complication rates.
- Para-prosthetic regurgitation is associated with increased morbidity and mortality.
- Pacing requirement varies between 3 and approximately 25% in contemporary studies.
- Stroke rates are declining and to date have not been shown to be significantly higher with repositionable devices.

Lotus transcatheter valve design
- The first fully resheathable, repositionable and retrievable TAVR prosthesis.
- Utilizes a unique mechanical expansion and locking mechanism.
- Nitinol frame and bovine pericardial leaflets.
- Adaptive seal surrounds the inflow portion of the valve frame and is designed to reduce para-prosthetic aortic regurgitation.

Clinical efficacy
- The REPRISE suite of trials have shown high procedural and device success.
- Near absence of significant para-prosthetic aortic regurgitation.

Procedural details
- The 23-mm device is delivered through an 18-Fr sheath and the 27-mm device through a 20-Fr sheath.
- A 25-mm device is planned for release in the second quarter of 2014.
- The device is currently only indicated for transfemoral delivery.

Alternative devices
- The Medtronic CoreValve Revalving System, Edwards Sapien, Direct Flow Medical and St Jude Medical Portico TAVR devices have obtained CE Mark approval in Europe.
- The Edwards Sapien and Medtronic CoreValve devices have US FDA approval.

Conclusion
- The Lotus prosthesis is a fully resheathable, repositionable and retrievable TAVR device.
- The Lotus has demonstrated excellent efficacy and safety in the REPRISE suite of trials.
- Modest pacing rates may be reduced as more device sizes become available, reducing the degree of oversizing.

References

1 Iung B, Cachier A, Baron G *et al.* Decision-making in elderly patients with severe aortic stenosis: why are so many denied surgery? *Eur. Heart J.* 26, 2714 – 2720 (2005).

2 Kodali SK, Williams MR, Smith CR *et al.* Two-year outcomes after transcatheter or surgical aortic-valve replacement. *N. Engl. J. Med.* 366, 1686 – 1695 (2012).

3 Makkar RR, Fontana GP, Jilaihawi H *et al.* Transcatheter aortic-valve replacement for inoperable severe aortic stenosis. *N. Engl. J. Med.* 366, 1696 – 1704 (2012).

4 Khatri PJ, Webb JG, Rodes-Cabau J *et al.* Adverse effects associated with transcatheter aortic valve implantation: a meta-analysis of contemporary studies. *Ann. Int. Med.* 158, 35 – 46 (2013).

5 Sherif MA, Abdel-Wahab M, Stocker B *et al.* Anatomic and procedural predictors of paravalvular aortic regurgitation after implantation of the Medtronic CoreValve bioprosthesis. *J. Am. Coll. Cardiol.* 56, 1623 – 1629 (2010).

6 Wong DT, Bertaso AG, Liew GY *et al.* Relationship of aortic annular eccentricity and paravalvular regurgitation post transcatheter aortic valve implantation with CoreValve. *J. Invasive Cardiol.* 25, 190 – 195 (2013).

7 Barbanti M, Yang TH, Rodes Cabau J *et al.* Anatomical and procedural features associated with aortic root rupture during balloon-expandable transcatheter aortic valve replacement. *Circulation* 128, 244 – 253 (2013).

8 Eker A, Sozzi FB, Civaia F, Bourlon F. Aortic annulus rupture during transcatheter aortic valve implantation: safe aortic root replacement. *Eur. J. Cardiothorac. Surg.* 41, 1205 (2012).

9 Khawaja MZ, Rajani R, Cook A *et al.* Permanent pacemaker insertion after CoreValve transcatheter aortic valve implantation: incidence and contributing factors (the UK CoreValve Collaborative). *Circulation* 123, 951 – 960 (2011).

10 Munoz-Garcia AJ, Hernandez-Garcia JM, Jimenez-Navarro MF *et al.* Factors predicting and having an impact on the need for a permanent pacemaker after CoreValve prosthesis implantation using the new Accutrak delivery catheter system. *JACC Cardiovasc. Interv.* 5, 533 – 539 (2012).

11 Chieffo A, Buchanan GL, Van Mieghem NM *et al.* Transcatheter aortic valve implantation with the Edwards SAPIEN versus the Medtronic CoreValve Revalving system devices: a multicenter collaborative study: the PRAGMATIC Plus Initiative (Pooled-RotterdAm-Milano-Toulouse In Collaboration). *J. Am. Coll. Cardiol.* 61, 830 – 836 (2013).

12 Laynez A, Ben-Dor I, Barbash IM *et al.* Frequency of conduction disturbances after Edwards SAPIEN percutaneous valve implantation. *Am. J. Cardiol.* 110, 1164 – 1168 (2012).

13 Webb JG, Altwegg L, Boone RH *et al.* Transcatheter aortic valve implantation: impact on clinical and valve-related outcomes. *Circulation* 119, 3009 – 3016 (2009).

14 Bleiziffer S, Ruge H, Horer J *et al.* Predictors for new-onset complete heart block after transcatheter aortic valve implantation. *JACC Cardiovasc. Interv.* 3, 524 – 530 (2010).

15 Cao C, Ang SC, Indraratna P *et al.* Systematic review and meta-analysis of transcatheter aortic valve implantation versus surgical aortic valve replacement for severe aortic stenosis. *Ann. Cardiothorac. Surg.* 2, 10 – 23 (2013).

16 Eggebrecht H, Schmermund A, Voigtlander T, Kahlert P, Erbel R, Mehta RH. Risk of stroke after transcatheter aortic valve implantation (TAVI): a meta-analysis of 10,037 published patients. *EuroIntervention* 8, 129 – 138 (2012).

17 Kahlert P, Knipp SC, Schlamann M *et al.* Silent and apparent cerebral ischemia after percutaneous transfemoral aortic valve implantation: a diffusion-weighted magnetic resonance imaging study. *Circulation* 121, 870 – 878 (2010).

18 Ghanem A, Muller A, Nahle CP *et al.* Risk and fate of cerebral embolism after transfemoral aortic valve implantation: a prospective pilot study with diffusion-weighted magnetic resonance imaging. *J. Am. Coll. Cardiol.* 55, 1427 – 1432 (2010).

19 Rodes Cabau J. PROTAVI-C Pilot Study. Prospective randomised outcome study in patients undergoing TAVI to examine cerebral ischaemia or bleeding complications. Presented at: *EuroPCR 2013*. Paris, France, 21 – 24 May 2013.

20 Meredith IT, Worthley SG, Whitbourn RJ *et al.* Transfemoral aortic valve replacement with the repositionable Lotus Valve System in high surgical risk patients: the REPRISE I study. *EuroIntervention* 9, 1264 – 1270 (2014).

21 Kappetein AP, Head SJ, Genereux P *et al.* Updated standardized endpoint definitions for transcatheter aortic valve implantation: the Valve Academic Research Consortium-2 consensus document. *J. Thorac. Cardiovasc. Surg.* 145,6 – 23 (2013).

22 Adams DH, Popma JJ, Reardon MJ *et al.* Transcatheter aortic-valve replacement with a self-expanding prosthesis. *N. Engl. J. Med.* 370, 1790 – 1798 (2014).

23 Dumonteil N. Need for permanent pacemaker following implantation of the repositionable second-generation LOTUS device for transcatheter aortic valve replacement: results from the pivotal REPRISE II trial. *J. Am. Coll. Cardiol.* 62, B39 (2013).

24 Gooley R, Lockwood S, Antonis P, Meredith IT. The SADRA Lotus Valve System: a fully repositionable, retrievable prosthesis. *Minerva Cardioangiol.* 61, 45 – 52 (2013).

25 Linke A, Wenaweser P, Gerckens U *et al.* *et al.* Treatment of aortic stenosis with a self-expanding transcatheter valve: the international multi-centre ADVANCE study. *Eur. Heart J.* doi:10.1093/eurheartj/ehu162 (2014) (Epub ahead of print).

26 Freeman M, Webb JG. Edwards Sapien and Edwards Sapien XT transcatheter heart valves for the treament of severe aortic stenosis. *Expert Rev. Med. Devices* 9(6), 563 – 569 (2012).

27 Schofer J, Colombo A, Klugmann S *et al.* Prospective multicenter evaluation of the direct flow medical transcatheter aortic valve. *J. Am. Coll. Cardiol.* 63(8), 763 – 768 (2014).

28 Manoharan G, Spence MS, Rodes-Cabau J *et al.* St Jude Medical Portico valve. *EuroIntervention* 8(Suppl. Q), Q97 – Q101 (2012).

Chapter 2: Quantification of Normative Ranges of Aortoventricular Interface Dimensions Using MDCT Imaging in Patients Without Aortic Valve Disease

Monash University

Declaration for Thesis Chapter 2

Quantification of Normative Ranges and Baseline Predictors of Aortoventricular Interface Dimensions Using Multi---Detector Computed Tomographic Imaging in Patients Without Aortic Valve Disease

Declaration by candidate

In the case of Chapter 2, the nature and extent of my contribution to the work was the following:

Nature of contribution	Extent of contribution (%)
Review of existing literature, planning study protocol, collection and interpretation of data writing manuscript, creation of figures, editing manuscript	80%

The following co---authors contributed to the work.

Name	Nature of contribution	Extent of contribution (%)
Prof James Cameron	Planning study protocol, interpretation of data, writing and editing manuscript	5%
Dr Jennifer Soon	Collection of data, writing and editing manuscript	2%
Mr Duncan Loi	Collection of data, writing and editing manuscript	2%
Ms Gauri Chitale	Collection of data, writing and editing manuscript	2%
Ms Rifath Syeda	Collection of data, writing and editing manuscript	2%
Prof Ian Meredith	Planning study protocol, interpretation of data, writing and editing manuscript	7%

The undersigned hereby certify that the above declaration correctly reflects the nature and extent of the candidate's and co---authors' contributions to this work.

Candidate's Signature	[redacted]	**Date** 12/04/2016

Main Supervisor's Signature	[redacted]	**Date** 12/04/2016

Preface

Disease at the interface of the left ventricle and aorta may result from disease in the left ventricular outflow tract, aortic valve and/or the aortic root. Diagnosis of these disease processes is generally achieved by echocardiographic imaging which has the advantage of providing both anatomical and functional information in relation to each component of the aortoventricular interface and the flow of blood through it. The 2---dimensional nature of echocardiographic imaging, however, limits the ability to completely image and assess the aortoventricular interface and its complex geometry. These limitations have become acutely highlighted with the advent of TAVR and the need for pre---procedural imaging.

In this context 3---dimensional MDCT assessment has become the gold standard pre---procedural imaging modality. MDCT imaging is now the preferred pre---procedural sizing modality for all trial and commercial TAVR devices. A standardised MDCT assessment technique of identifying the annular plane and performing further aortoventricular interface measurements in relation to this plane has also been accepted as the gold standard. Despite this accepted standard and inclusion in societal guidelines there have been no published normative ranges for aortoventricular interface dimensions.

The following work, published in *European Journal of Radiology*, is the first study to utilise the basal plane technique to perform standardised and reproducible assessment of the entire aortoventricular interface in patients without aortic valve disease to quantify normative ranges and baseline predictors of these dimensions. These normative ranges provide a basis

for future trial and clinical practice along with an indication of population ranges which need to be accommodated in future transcatheter aortic valve iterations.

European Journal of Radiology 84 (2015) 1737–1744

Contents lists available at ScienceDirect

European Journal of Radiology

journal homepage: www.elsevier.com/locate/ejrad

Quantification of normative ranges and baseline predictors of aortoventricular interface dimensions using multi-detector computed tomographic imaging in patients without aortic valve disease

Robert P. Gooley[a,b,*], James D. Cameron[a,b], Jennifer Soon[a,b], Duncan Loi[b], Gauri Chitale[b], Rifath Syeda[b], Ian T. Meredith[a,b]

[a] MonashHeart, Monash Health, Melbourne 3168, Australia
[b] Monash Cardiovascular Research Centre, Department of Medicine (MMC), Monash University, Melbourne 3168, Australia

article info

Article history:
Received 4 October 2014
Received in revised form 12 May 2015
Accepted 22 May 2015

Keywords:
Aortic annulus
Aortoventricular interface
Normative ranges
Aortic root
Multi-detector computed tomography

abstract

Background: Multidetector computed tomographic (MDCT) assessment of the aortoventricular interface has gained increased importance with the advent of minimally invasive treatment modalities for aortic and mitral valve disease. This has included a standardised technique of identifying a plane through the nadir of each coronary cusp, the basal plane, and taking further measurements in relation to this plane. Despite this there is no published data defining normal ranges for these aortoventricular metrics in a healthy cohort.

This study seeks to quantify normative ranges for MDCT derived aortoventricular dimensions and evaluate baseline demographic and anthropomorphic associates of these measurements in a normal cohort.

Methods: 250 consecutive patients undergoing MDCT coronary angiography were included. Aortoventricular dimensions at multiple levels of the aortoventricular interface were assessed and normative ranges quantified. Multivariate linear regression was performed to identify baseline predictors of each metric.

Results: The mean age was 59 ± 12 years. The basal plane was eccentric (EI = 0.22 ± 0.06) while the left ventricular outflow tract was more eccentric (EI = 0.32 ±0.06), with no correlation to gender, age or hypertension. Male gender, height and body mass index were consistent independent predictors of larger aortoventricular dimensions at all anatomical levels, while age was predictive of supra-annular measurements.

Conclusions: Male gender, height and BMI are independent predictors of all aortoventricular dimensions while age predicts only supra-annular dimensions. Use of defined metrics such as the basal plane and formation of normative ranges for these metrics allows reference for clinical reporting and for future research studies by using a standardised measurement technique.

1. Introduction

Pre-procedural MDCT assessment of the aortoventricular interface has gained increasing importance with the advent of new technologies such as minimally invasive surgery and catheter based interventions. In order to standardise pre-procedural measurements of the aortic valve, a structure without a true anatomic annulus, the novel basal plane metric through the nadir of each aortic valve cusp has been adopted [1].

At the same time an increasing number of otherwise healthy people are undergoing incidental CT angiographic imaging of the aortoventricular interface during tests such as CT coronary angiography and aortography. Despite the widespread acceptance of the

Abbreviations: MDCT, multidetector computed tomography; AS, aortic stenosis; BMI, body mass index; ECG, electrocardiograph; D_{min}, minimum diameter; D_{max}, maximum diameter; EI, eccentricity index; TAVR, transcatheter aortic valve replacement; LVOT, left ventricular outflow tract; SOV, sinus of valsalva.

* Corresponding author at: MonashHeart, Monash Health, 246 Clayton Road, Clayton, Vic. 3168, Australia. [redacted]

http://dx.doi.org/10.1016/j.ejrad.2015.05.029
0720-048X/

novel basal plane metric and its use in a number of comparative studies within the field of transcatheter aortic valve implantation (TAVI), its normal range in a healthy unselected cohort has not previously been published. Importantly measurements used for anatomical assessment prior to TAVI are generally acquired during systole and hence cannot be extrapolated to the healthy cohort where imaging, especially during CT coronary angiography, is acquired during diastole. Use of data from a cohort with aortic valve pathology can also not be extended to a normative cohort as the impact of the disease process itself on aortoventricular interface geometry is not known.

Further measurements of the aortoventricular interface are often taken in reference to the basal plane at the level of the left ventricular outflow tract (LVOT), sinus of valsalva (SOV), ascending aorta and coronary artery ostia. As such normal ranges for these metrics, using the technique of identifying a short axis plane through the coronary cusp nadirs, have also not been reported in a cohort without significant aortic valve disease.

This study aims to quantify diastolic normative ranges for aortoventricular interface metrics in a healthy population. A thorough understanding of the complex native geometry, together with demographic and anthropomorphic predictors of dimensions at all levels of the aortoventricular interface allows quantification of diastolic normal ranges for both clinical reference and future research.

2. Methods

2.1. Population

Two hundred and fifty consecutive patients undergoing MDCT coronary angiography at a single tertiary cardiac centre between April and June 2012 were eligible for inclusion. All patients were referred for assessment of coronary artery anatomy in the setting of low to intermediate risk chest pain syndromes. All scans were visually assessed by an independent MDCT operator to ensure adequate clinical quality.

Patients were excluded if they had a history of cardiac or aortic surgery. Aortic valve disease was further excluded in 71.2% of patients based on a transthoracic echocardiogram performed within 6 months of the index scan. In addition all MDCT scans were assessed and patients excluded if leaflet or annular calcification was identified or bicuspid morphology was present.

Ethical approval was obtained from the institutional Human Research Ethics Committee.

2.2. Baseline data

Patient baseline demographic and anthropomorphic data (Table 1) was collected and entered into a dedicated database. Patients were considered to have hypertension and/or hypercholesterolemia if formally diagnosed by their treating physician or they were on pharmacological treatment consistent with either condition. A family history of ischaemic heart disease was documented if a first degree relative had an initial diagnosed episode aged less than 60 years. A body mass index (BMI) greater than 25 was classified overweight and greater than 30 considered obese.

2.3. Imaging

All MDCT examinations were performed utilising a Toshiba Aquilion One 320-detector row scanner (Toshiba Medical Systems, Japan). In accordance with standard imaging protocols at our institution patients received beta-blockade to achieve a target heart rate of 50–60 bpm. Scans were performed using prospective ECG gating with a temporal window between 75 and 85% of the R–R interval.

Table 1
Baseline characteristics ($n = 250$).

	Male ($n = 123$)	Female ($n = 127$)	P-value
Demographic and anthropometric data			
Age (years)	57.4 ± 12.1	59.7 ± 11.4	0.131
Ethnicity, n (%)			
Caucasian	102 (82.9)	99 (78.0)	0.475
Asian	17 (13.8)	22 (17.3)	0.417
Other	4 (3.3)	6 (4.7)	0.209
Height (cm)	175.7 ± 8.1	160.4 ± 8.3	<0.001
Weight (kg)	86.9 ± 17.7	75.0 ± 16.8	<0.001
BMI* (kg/m^2)	28.1 ± 5.3	29.1 ± 6.1	0.165
BSA† (m^2)	2.0 ± 0.2	1.8 ± 0.2	<0.001
Cardiovascular risk factors, n (%)			
Overweight/obese	96 (78.0)	98 (77.2)	0.739
Smoker	46 (37.4)	29 (22.8)	0.658
Diabetes mellitus	19 (15.4)	22 (17.3)	0.735
Hypertension	56 (45.5)	74 (58.3)	0.057
Hypercholesterolemia	60 (48.8)	71 (55.9)	0.311
Family history	58 (47.2)	64 (50.4)	0.615

* Body mass index.
† Body surface area.

Collimation was individualised to achieve a z-axis that visualised the entire coronary tree with 0.5 mm slice thickness. Gantry rotation speed was 275 ms per rotation, tube voltage 100–120 kV and tube current individualised to body habitus.

Intravenous contrast (Omnipaque 350, GE Healthcare, USA) was administered via an 18-gauge antecubital vein as a 70 ml bolus followed by a 50 ml saline bolus at a rate of 6 ml/s. Scanning acquisition was triggered manually by monitoring for contrast density >300HU in the descending aorta to ensure adequate contrast opacification.

2.4. MDCT analysis

Scans were analysed using the 3Mensio valve analysis program (3Mensio, Bilthoven, The Netherlands). The aortic valve basal plane was defined by identifying the nadir of each aortic valve cusp and constructing a short-axis plane through these points. The minimum diameter (D_{min}), maximum diameter (D_{max}), perimeter and area (Fig. 1A) were measured in the basal plane short-axis view.

All further measurements were made in reference to the basal plane along a system-generated centreline. The LVOT was measured in the short-axis 4 mm below the basal plane. Minimum and maximum diameters, perimeter and area were measured at this point (Fig. 1B). The SOV width, perimeter and area were measured at the widest point of the sinuses (Fig. 1C) and the ascending aorta measured at 40 mm above the basal plane (Fig. 1D). The height of each coronary sinus was measured from the basal plane to the sinotubular junction in a stretched multi-planar image. The height of each coronary artery was measured from the basal plane to the lowest border of the ostia in the stretched multi-planar image (Fig. 1E). The angulation of the aortic valve plane was measured in relation to the horizontal.

The circularity of the basal plane, LVOT and ascending aorta was quantified using the eccentricity index (EI); $EI = 1 - (D_{min}/D_{max})$. A value approaching 0 indicating circularity while if the EI approaches 1 the structure is more eccentric [2].

Fifty randomly selected MDCT scans were re-measured by the primary operator (RG) and by a second blinded experienced operator (JS) to quantify the reproducibility of the measurements.

2.5. Statistical analysis

Categorical variables were expressed as frequencies and percentages while continuous variables were expressed as means ± standard deviations. The presence of normality

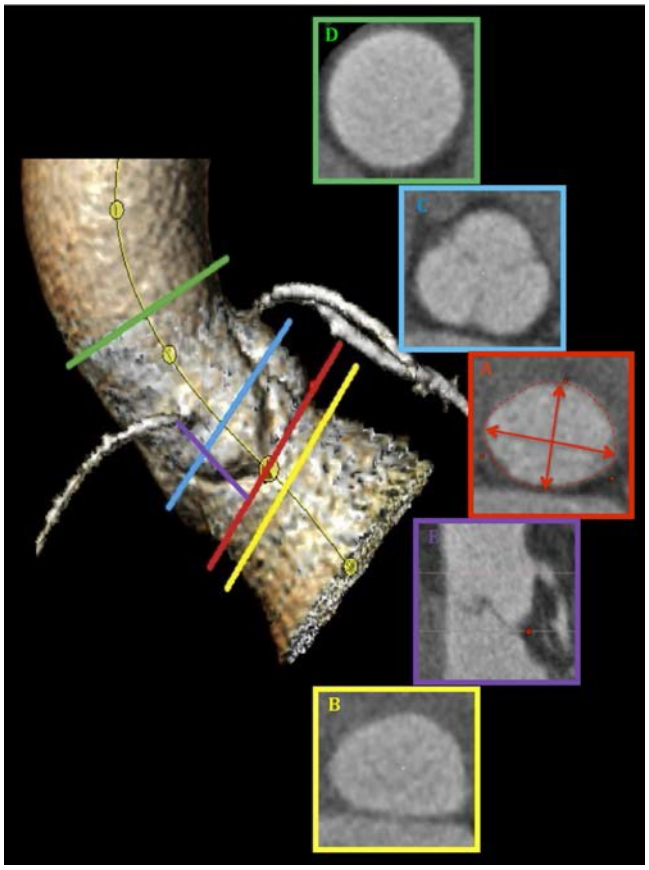

Fig. 1. Aortic root assessment using the 3Mensio valve analysis program. (A) – Basal plane formed by identifying a plane through the nadir of each coronary cusp and D_{min}, D_{max}, perimeter and area were assessed in the short axis. (B) – LVOT with D_{min}, D_{max}, perimeter and area measurements. (C) – SOV width, perimeter and area were measured at the widest point. (D) – Ascending aorta with D_{min}, D_{max}, perimeter and area measurements. (E) – The height of each coronary ostia was measured from the basal plane.

was assessed by graphical inspection and confirmed by the Shapiro–Wilk test. Normative ranges were quantified as two standard deviations above and below the mean.

The correlation between baseline patient characteristics and aortic root measurements was assessed using a multivariate linear regression model. Only variables with a *P*-value <0.2 on univariate analysis were included in the multivariate analysis. A backward sequential regression was performed and significant co-variables assessed for co-linearity.

Intra-observer and inter-observer variability was assessed using intra-class correlation coefficient and Bland–Altman plots.

Statistical analysis was performed using IBM SPSS Statistics version 21.0 (IBM Corporation, NY, USA).

3. Results

3.1. Population

250 consecutive patients who were referred to our single tertiary cardiac centre for MDCT imaging were included. All patients were deemed by an experienced reader to have interpretable images with adequate contrast opacification and minimal temporal artefact. No patients were excluded.

The mean age of the cohort was 58.55 years, ranging from 14 to 86 years. There was an even gender distribution (49.2% male) and cardiovascular risk factor prevalence was in keeping with a population undergoing coronary artery assessment. The majority of patients were from a caucasian background (80.4%) with a significant minority of Asian descent (15.6%) and only a small number from other ethnic backgrounds (Table 1).

3.2. MDCT 3Mensio assessment

3.2.1. Basal plane

The spread of measurements was normally distributed for each metric (Fig.2 – basal plane metrics with others shown in Supplementary Fig. 1). The mean basal plane D_{min} was 21.18 ± 2.41 mm, D_{max} 27.35 ± 2.89 mm, perimeter 76.84 ± 7.59 mm and area 451.63 ± 95.36 mm^2. Two dimensional basal plane measurements (D_{min}, D_{max}, perimeter and area) were significantly larger in males while there was no statistical difference in the degree of eccentricity by gender. 95% normative ranges for all dimensions are given in Table 2.

Supplementry material related to this article found, in the online version, at http://dx.doi.org/10.1016/j.ejrad.2015.05.029

3.2.2. Left ventricular outflow tract

The LVOT exhibited greater eccentricity than the aortic annulus with mean D_{min} of 19.25 ± 2.61 mm and D_{max} of 28.32 ± 3.27 mm resulting in a mean EI of 0.32 ± 0.06 (Table 2). The mean LVOT perimeter was 77.66 ± 9.79 mm and area 440.11 ± 100.73 mm^2. Males had larger two-dimensional measurements than females while there was no difference in degree of eccentricity.

Most patients (97.2%) had a greater degree of eccentricity at the level of the LVOT than at the basal plane (Fig. 3) with an overall mean difference of 0.10. There was no association between advancing age and degree of eccentricity at either level.

3.2.3. Sinus of valsalva

While males had larger SOV dimensions there was no significant difference between the individual sinus widths (left 31.95 ±n3.62 mm, right 30.75 ± 3.63 mm, non 31.75 ± 3.62 mm). The mean sinus height was 22.73 ± 3.43 mm (Table 2).

3.2.4. Ascending aorta

The ascending aorta was found to be essentially circular in both males and females with D_{min} 30.08 ± 3.56 mm and D_{max} 31.08 ± 3.80 mm generating a population mean EI of only 0.03 ± 0.02 (men = 0.03 ± 0.02, women = 0.03 ± 0.02).

3.2.5. Height of the coronary ostia

201 subjects (80.4%) had a right coronary artery arising higher (18.04 ± 2.95 mm) than the left coronary artery (14.97 ± 3.56 mm).

3.2.6. Aorto-ventricular angulation

There was no gender related difference in the degree of angulation between the horizontal and the aortic valve plane (men = 45.99 ± 8.34°, women = 46.65 ± 8.21°).

3.3. Multivariate assessment

Multivariate linear regression identified male gender, height and BMI as consistent independent predictors of larger dimensions at the annular, LVOT, SOV and ascending aortic levels. Advancing age was identified as an independent predictor of increased dimen- sions only in supra-annular locations with increased dimensions at the SOV, ascending aorta and height of the coronary arteries (Table 3).

3.4. Reproducibility

Intra-observer variability was consistently good for each measured dimension using the 3Mensio semi-automated system. There

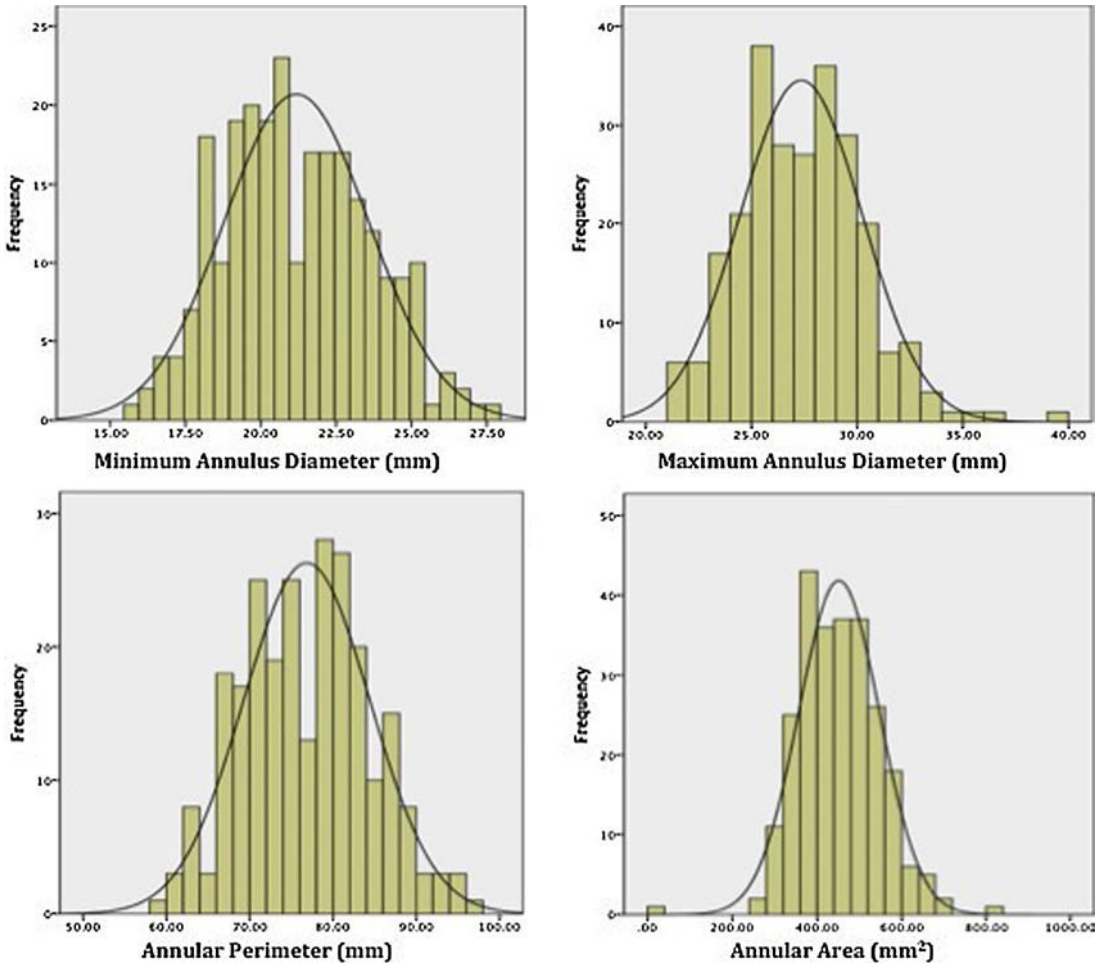

Fig. 2. Basal plane dimensions were normally distributed as demonstrated by histogram.

was consistently high intra-observer reliability with intra-class correlation values of greater than 0.9 for all measured variables. Inter-observer variability was similarly high for all measurements. Intra-class correlation was greater than 0.9 for all variables other than the height of the non-coronary cusp which remained high at 0.833 (Table 4). These results were confirmed by Bland Altman analysis (Fig. 4 and Supplementary Fig. 2).

Supplementry material related to this article found, in the online version, at http://dx.doi.org/10.1016/j.ejrad.2015.05.029

3.5. Anatomic suitability for contemporary transcatheter procedures

When sizing algorithms for two contemporary transcatheter aortic valve prostheses were strictly applied to this cohort of younger patients without aortic valve disease eight subjects were found to have annular dimensions that were larger than the suggested sizing criteria for the CoreValve transcatheter prostheses and one subject had an annulus diameter less than the minimum.

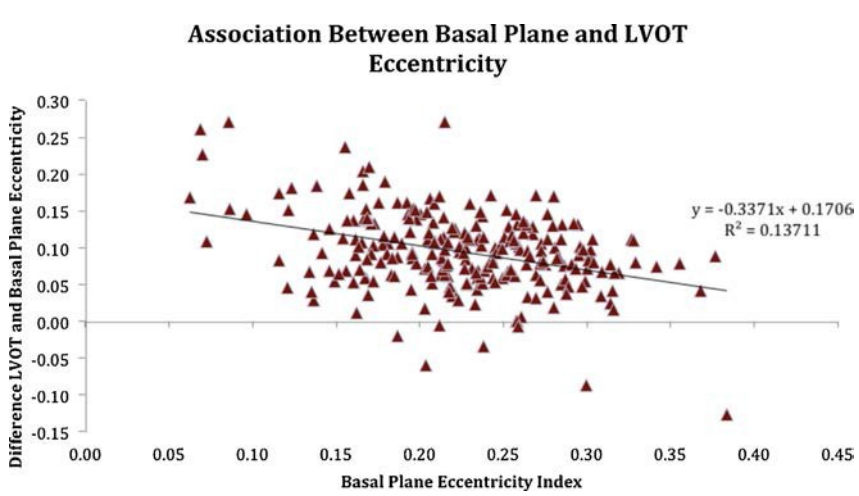

Fig. 3. Variability in eccentricity at the LVOT and basal plane levels.

Table 2
95% normative ranges.

Variable	Male (n = 123) Mean ± SD	Male (n = 123) 95% normative range	Female (n = 127) Mean ± SD	Female (n = 127) 95% normative range	P-value
Aortic basal plane					
Minimum diameter (mm)	22.54 ± 2.10	18.34–26.74	19.86 ± 1.90	16.06–23.66	<0.001
Maximum diameter (mm)	29.02 ± 2.52	23.98–34.06	25.73 ± 2.23	21.27–30.19	<0.001
Eccentricity index	0.22 ± 0.06	0.10–0.34	0.23 ± 0.05	0.13–0.33	0.435
Perimeter (mm)	81.46 ± 6.17	69.12–93.8	72.37 ± 6.00	60.37–84.37	<0.001
Area (mm^2)	505.43 ± 90.18	325.07–685.79	399.52 ± 67.32	264.88–534.16	<0.001
Left ventricular outflow tract					
Minimum diameter (mm)	20.65 ± 2.34	15.97–25.33	17.89 ± 2.10	13.69–22.09	<0.001
Maximum diameter (mm)	30.14 ± 2.86	24.42–35.86	26.55 ± 2.63	21.29–31.81	<0.001
Eccentricity index	0.31 ± 0.07	0.17–0.45	0.33 ± 0.06	0.21–0.45	0.126
Perimeter (mm)	82.42 ± 9.89	62.64–102.2	73.05 ± 7.15	58.75–87.35	<0.001
Area (mm^2)	495.49 ± 92.41	310.67–680.31	386.47 ± 76.74	232.99–539.95	<0.001
Sinus of valsalva					
Left coronary width (mm)	34.13 ± 3.06	28.01–40.25	29.85 ± 2.80	24.25–35.45	<0.001
Right coronary width (mm)	32.89 ± 3.12	26.65–39.13	28.68 ± 2.79	23.10–34.26	<0.001
Non coronary width (mm)	33.82 ± 3.14	27.54–40.10	29.75 ± 2.85	24.05–35.45	<0.001
Perimeter (mm)	116.03 ± 10.57	94.89–137.17	101.99 ± 9.67	82.65–121.33	<0.001
Area (mm^2)	976.81 ± 179.24	618.33–1335.29	749.69 ± 144.97	459.75–1039.63	<0.001
Sinus heights					
Left coronary cusp (mm)	24.52 ± 3.39	17.74–24.52	21.17 ± 2.85	15.47–26.87	<0.001
Right coronary cusp (mm)	24.73 ± 2.92	18.89–30.57	21.29 ± 2.69	15.91–26.67	<0.001
Non coronary cusp (mm)	24.26 ± 3.14	17.98–30.54	20.56 ± 2.61	15.34–25.78	<0.001
Ascending aorta					
Minimum diameter (mm)	30.94 ± 3.35	24.24–37.64	29.24 ± 3.56	22.12–36.36	<0.001
Maximum diameter (mm)	31.96 ± 3.68	24.60–39.32	30.23 ± 3.74	22.75–37.71	<0.001
Eccentricity index	0.03 ± 0.02	0.00–0.07	0.03 ± 0.02	0.00–0.07	0.644
Coronary heights					
Left (mm)	16.02 ± 3.72	8.58–23.46	13.95 ± 3.08	7.79–20.11	<0.001
Right (mm)	19.32 ± 3.03	13.26–25.38	16.80 ± 2.26	12.28–21.32	<0.001
Angulation					
Aortoventricular angle (degrees)	45.99 ± 8.34	29.31–62.67	46.65 ± 8.21	30.23–63.07	0.533

Similarly nine subjects were found to have annuli that were too large for currently available Sapien XT prostheses and one subject was too small.

When the height of the coronary ostia above the basal plane was assessed as an isolated variable without regard for sinus dimensions, 22 subjects had a coronary artery that arose lower than

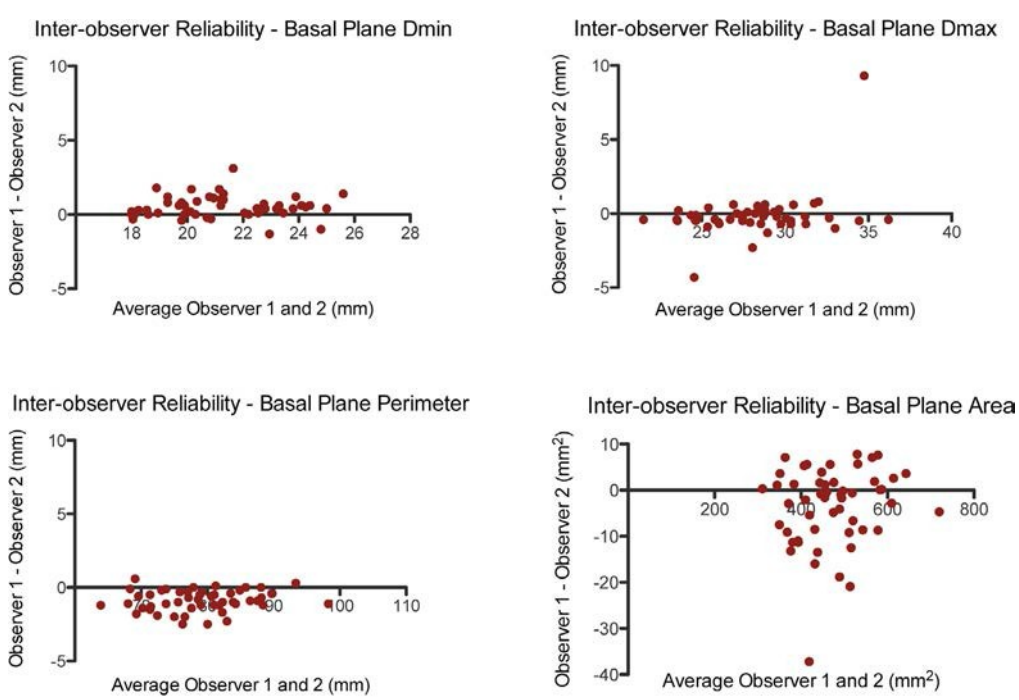

Fig. 4. Bland Altman graphs for each basal plane metrics showing high inter-observer correlation.

Table 3
Multivariate linear regression analysis.

Variable	♦ Coefficient	SE	CI	*P*-value
Basal plane				
D_{min}				
Male	1.569	0.315	0.950–2.189	<0.001
Height	0.082	0.014	0.054–0.110	<0.001
BMI	0.101	0.020	0.061–0.141	<0.001
D_{max}				
Male	1.731	0.358	1.025–2.436	<0.001
Height	0.106	0.016	0.074–0.138	<0.001
BMI	0.141	0.024	0.094–0.189	<0.001
Asian	-0.402	0.151	−0.700–−0.104	0.008
Perimeter				
Male	5.097	0.912	3.300–6.894	<0.001
Height	0.540	0.162	0.222–0.859	0.001
BMI	1.111	0.449	0.226–1.995	0.014
Asian	−1.027	0.384	−1.884–−0.271	0.008
Area				
Male	60.524	12.408	36.085–84.964	<0.001
Height	3.162	0.565	2.048–4.276	<0.001
BMI	4.140	0.796	2.571–5.708	<0.071
LVOT				
D_{min}				
Male	1.506	0.353	0.811–2.200	<0.001
Height	0.089	0.016	0.058–0.120	<0.001
BMI	0.112	0.023	0.067–0.156	<0.001
D_{max}				
Male	2.315	0.438	1.453–3.177	<0.001
Height	0.092	0.020	0.053–0.131	<0.001
BMI	1.55	0.028	0.099–0.210	<0.001
Perimeter				
Male	4.686	1.372	1.983–7.388	0.001
Height	0.335	0.062	0.213–0.457	<0.001
BMI	0.419	0.088	0.245–0.592	<0.001
Area				
Male	55.630	13.092	29.843–81.416	<0.001
Height	3.789	0.590	2.627–4.951	<0.001
BMI	4.893	0.845	3.228–6.559	<0.001
SOV				
Width LCC				
Male	2.664	0.472	1.735–3.593	<0.001
Age	0.048	0.015	0.018–0.078	0.018
Height	0.119	0.022	0.076–0.161	<0.001
BMI	0.128	0.032	0.064–0.191	<0.001
Width RCC				
Male	2.709	0.482	1.759–3.659	<0.001
Age	0.042	0.016	0.012–0.073	0.007
Height	0.111	0.022	0.067–0.154	<0.001
BMI	0.124	0.033	0.059–0.188	<0.001
Width NCC				
Male	2.644	0.497	1.665–3.623	<0.001
Age	0.046	0.016	0.015–0.077	0.004
Height	0.105	0.023	0.060–0.150	<0.001
BMI	0.069	0.032	0.006–0.133	0.032
Perimeter				
Male	9.162	1.658	5.896–12.427	<0.001
Age	0.178	0.053	0.073–0.283	0.001
Height	0.359	0.076	0.209–0.509	<0.001
BMI	0.343	0.113	0.120–0.565	0.003
Area				
Male	148.635	26.804	95.893–201.432	<0.001
Age	2.415	0.850	0.740–4.090	0.005
Ht	5.736	1.228	3.318–8.155	<0.001
BMI	4.777	1.742	1.346–8.208	0.007
Height LCC				
Male	2.469	0.520	1.445–3.494	<0.001
Age	0.009	0.019	0.028–0.046	0.048
Height	0.050	0.023	0.004–0.096	0.034
BMI	2.456	0.964	1.457–4.372	0.024

Table 3 (*Continued*)

Variable	♦ Coefficient	SE	CI	*P*-value
Height RCC				
Male	2.659	0.403	1.866–3.451	<0.001
Age	0.031	0.015	0.002–0.061	0.037
Height				
BMI	3.364	0.865	1.659–5.068	<0.001
Height NCC				
Male	2.318	0.483	1.367–3.268	<0.001
Age	0.036	0.016	0.005–0.066	0.022
Height				
BMI	10.855	2.746	5.446–16.264	<0.001
Coronary heights				
LMCA				
Male	1.234	0.583	0.086–2.381	0.035
Age	0.032	0.019	0.004–0.069	0.043
Height	0.537	0.194	0.156–0.918	0.006
BMI	0.728	0.294	0.149–1.307	0.014
RCA				
Male	1.465	0.450	0.579–2.351	0.001
Age	0.038	0.015	0.008–0.067	0.012
Height	0.075	0.021	0.034–0.116	<0.001
BMI	0.054	0.029	0.004–0.112	0.036
Ascending aorta				
D_{min}				
Male	1.308	0.473	0.377–2.239	0.006
Age	0.087	0.018	0.051–0.123	<0.001
Height	1.388	0.427	0.546–2.229	0.001
BMI	3.095	1.011	1.104–5.086	0.002
D_{max}				
Male	1.249	0.504	0.257–2.241	0.014
Age	0.099	0.020	0.060–0.137	<0.001
Height	1.387	0.455	0.490–2.283	0.003
BMI	3.594	1.077	1.472–5.716	0.001
Perimeter				
Male	3.522	1.541	0.487–6.557	0.023
Age	0.298	0.060	0.180–0.415	<0.001
Height	3.885	1.393	1.142–6.628	0.006
BMI	10.887	3.296	4.396–17.379	0.001
Area				
Male	48.174	25.013	1.094–97.443	0.055
Age	5.029	0.970	3.118–6.940	<0.001
Height	56.041	22.608	11.510–100.572	0.014
BMI	177.686	53.499	72.309–283.064	0.001
Aorto-ventricular angle				
Age	0.171	0.044	0.084–0.258	<0.001
Height	-0.134	0.068	−0.268–−0.001	0.048
BMI	8.596	3.177	2.338–14.854	0.007

recommended for CoreValve insertion. Fourteen subjects would be excluded from Sapien XT insertion due to inadequate coronary artery take off height based on sizing recommendations.

Overall 6% of this cohort would be anatomically unsuitable for implantation of either the CoreValve or Sapien XT prostheses based on current anatomical sizing recommendations.

4. Discussion

With the advent of new surgical and catheter based treatment modalities for disease of the aorta and aortic valve direct intra-procedural sizing is often not practical. This has lead to an increased reliance on pre-procedural imaging. In fields such as TAVI there has been an evolution from two-dimensional echocardiographic assessment of only the aortic annulus to MDCT derived three-dimensional assessment of the entire aortoventricular interface [1,3–5]. This change to MDCT based pre-procedural assessment has been shown to correlate with reduced complications and improved outcomes [6–10]. The aortic valve does not have a true anatomic

annulus and as such new metrics have been developed to stan-

Table 4
Intra and inter-observer reliability.

Variable	Inter-observer variability		Intra-observer variability	
	Intra-class correlation	95% confidence interval	Intra-class correlation	95% confidence interval
Aortic basal plane				
Minimum diameter	0.956	0.849–0.982	0.958	0.911–0.988
Maximum diameter	0.938	0.892–0.965	0.964	0.935–0.991
Perimeter	0.994	0.902–0.998	0.992	0.900–0.999
Area	0.934	0.883–0.962	0.957	0.921–0.976
Left ventricular outflow tract				
Minimum diameter	0.945	0.785–0.978	0.937	0.845–0.976
Maximum diameter	0.970	0.912–0.987	0.993	0.979–0.996
Perimeter	0.967	0.561–0.991	0.991	0.989–0.997
Area	0.989	0.965–0.995	0.995	0.991–0.998
Sinus of valsalva				
Left coronary width	0.964	0.895–0.984	0.978	0.959–0.987
Right coronary width	0.961	0.839–0.985	0.985	0.974–0.992
Non coronary width	0.944	0.896–0.969	0.990	0.979–0.995
Perimeter	0.962	0.534–0.989	0.993	0.987–0.998
Area	0.995	0.992–0.997	0.989	0.963–0.994
Sinus heights				
Left coronary cusp	0.925	0.857–0.959	0.997	0.993–0.999
Right coronary cusp	0.954	0.920–0.974	0.995	0.990–0.998
Non coronary cusp	0.833	0.705–0.905	0.995	0.988–0.997
Ascending aorta				
Minimum diameter	0.994	0.989–0.996	0.990	0.985–0.994
Maximum diameter	0.996	0.993–0.998	0.996	0.994–0.998
Coronary heights				
Left	0.948	0.909–0.971	0.937	0.912–0.958
Right	0.922	0.863–0.956	0.978	0.958–0.986
Angulation				
Aortoventricular angle	0.943	0.899–0.968	0.969	0.953–0.983

dardise measurements. In particular the basal plane, a short-axis plane through the nadir of each aortic valve cusp has been used to represent the aortic annulus.

While novel MDCT derived metrics such as the basal plane have been widely embraced in the field of catheter based valve intervention they are not routinely applied to assessment of the aortoventricular interface when it is imaged in a 'normal' population such as during CT coronary angiography. This may be driven by the limited data on quantification of normal ranges for these metrics to allow standardised reporting. The limited data available in the published literature either pre-dates the use of these new metrics or focuses solely on assessment of patients with aortic valve pathology [11,12] without regard for what constitutes the normal ranges of aortic root measurements in a healthy population. Unfortunately extrapolation of such data to a normal cohort is not possible as anatomical assessment prior to catheter based interventions is generally performed in systole while aortic root imaging in health, especially during CT coronary angiography, is performed in diastole. In addition the effect of aortic valve pathology on aortoventricular interface geometry must be considered.

We found that the basal plane is eccentric with a mean EI of 0.22 while the LVOT is more eccentric with a mean EI of 0.32. Eccentricity at the level of the LVOT is often due to increased prominence of the basal septum which can occur when the LV has had prolonged exposure to high after-load such as with advanced age or hypertension. In our cohort, however, we were not able to identify independent predictors of LVOT/annular discordance by multivariate regression (Table 3) or collinear analysis (Fig. 3).

Our finding of significant eccentricity at the annular and particularly LVOT levels highlights the importance of reporting perimeter and to a lesser extent area measurements. The perimeter of an ellipse does not alter when it is circularised and hence is often a more reliable pre-procedural measurement. Perimeter measurements may also negate the problem of LVOT geometric variance during the cardiac cycle, where the LVOT may be significantly more eccentric in diastole. Previous studies comparing annular dimensions in patients with severe aortic stenosis found that perimeter and area derived dimensions varied by less than 2 mm, and as little as 0.6 mm, throughout the cardiac cycle [13,14]. The variation in ascending aortic dimensions is much less predictable and may vary in either direction during the cardiac cycle [15]. Focus on perimeter and area derived dimensions may, therefore, reduce the clinical need to perform full R–R interval scans to capture diastole and systole, which simultaneously increases radiation exposure. Our study has demonstrated high intra and inter-observer concordance using semi-automated analysis for all measured metrics, with concordance rates similar to previously published studies [16,17].

By multivariate analysis we have demonstrated baseline characteristics that are independently associated with aortic root dimensions. Male gender, increased height and a larger BMI were each independently associated with greater dimensions at each level of the aortic root complex. Interestingly advanced age was only predictive for increased supra-annular dimensions. The pathophysiology behind this age related change is unclear. The effect of age on aortic wall stiffness has previously been documented and thought to be due to changes related to elastin fibre quality and orientation within the arterial wall [18]. It is possible that this disruption and fragmentation of elastin is responsible for the observed increase in SOV and ascending aorta dimensions. Similar anthropomorphic predictors have been found in other published studies that assessed only thoracic aorta dimensions [19,20].

Beyond the need for normal ranges in health this population offers other potential clinical uses. We are already seeing a drift in the use of new technologies such as TAVI into younger and lower-risk cohorts such as the one we have presented. Using this data future TAVI devices may be tailored to be population

specific and more closely imitate the normal geometric patterns we have described. While this cohort did not have aortic valve disease comparison of their aortoventricular dimensions to current manufacturer sizing recommendations for Sapien XT and CoreValve prostheses would see up to 6% excluded from TAVI, a procedure with proven morbidity and mortality benefit [21]. The most frequent dimension that would lead to exclusion from TAVI implantation is insufficient coronary artery height. While it is now recognised that this measure should not be assessed in isolation but rather considered in the context of SOV capacity and calcification distribution, it highlights the need for improved awareness of normal geometry in device development. Awareness of what constitutes normal anatomic range for each variable is important for future development of population specific TAVI devices that maintain or imitate native aortic root anatomy.

We have quantified diastolic normative ranges for MDCT derived aortoventricular dimensions using a standardised technique with high reproducibility. This represents the largest cohort of participants without aortic valve pathology in the published literature that has undergone complete aortoventricular inter- face MDCT assessment. The normative ranges we have defined together with the demographic and anthropomorphic predictors of each dimension may form a basis for clinical reporting and future research comparisons between study populations and this normal cohort.

4.1. Limitations

While we endeavoured to study a 'normal' cohort, participants were undergoing a cardiac MDCT scan to assess their coronary anatomy in the setting of possible ischaemic chest pain. This results in possible selection bias that may exist among patients referred with chest pain. Our broad age range (14–86 years) and spread of anthropomorphic variables suggest that any such selection bias would be small. Some measurements such as annular eccentricity have been shown to alter throughout the cardiac cycle. The inclusion of area and perimeter measurements, which do not vary greatly, somewhat negates this. Full cardiac cycle scanning would allow complete R–R interval interpretation but would expose participants to higher radiation doses. This study, rather, provides diastolic normative ranges as diastolic images are more commonly acquired in patients undergoing coronary CT angiography.

5. Conclusion

Gender, height, BMI and age are independent predictors of MDCT derived aortoventricular interface metrics. Normative ranges quantified in this study may act as a reference for clinical reporting and future investigational work.

Conflicts of interest

The authors do not have any conflicts to declare in relation to this work.

Acknowledgments

Dr Robert Gooley receives a research scholarship from the National Health and Medical Research Council of Australia.

The other authors have no financial acknowledgments.

References

[1] S. Achenbach, A. Schuhback, J.K. Min, J. Leipsic, Determination of the aortic annulus plane in ct imaging-a step-by-step approach, JACC Cardiovasc. Imaging. 6 (2013) 275–278.

[2] D.T. Wong, A.G. Bertaso, G.Y. Liew, V.S. Thomson, M.S. Cunnington, J.D. Richardson, et al., Relationship of aortic annular eccentricity and paravalvular regurgitation post transcatheter aortic valve implantation with CoreValve, J. Invasive Cardiol. 25 (2013) 190–195.

[3] D. Al-Hassan, P. Blanke, J. Leipsic, Multidetector computed tomography in transcatheter aortic valve implantation. Where we stand, Minerva Cardioangiol. 61 (2013) 407–427.

[4] O. Husser, A. Holzamer, M. Resch, D.H. Endemann, J. Nunez, V. Bodi, et al., Prosthesis sizing for transcatheter aortic valve implantation – comparison of three dimensional transesophageal echocardiography with multislice computed tomography, Int. J. Cardiol. (2013).

[5] A. Hutter, A. Opitz, S. Bleiziffer, H. Ruge, I. Hettich, D. Mazzitelli, et al., Aortic annulus evaluation in transcatheter aortic valve implantation, Catheter. Cardiovasc. Interv.: Off. J. Soc. Cardiac Angiogr. Interventions 76 (2010) 1009–1019.

[6] R.K. Binder, J.G. Webb, A.B. Willson, M. Urena, N.C. Hansson, B.L. Norgaard, et al., The impact of integration of a multidetector computed tomography annulus area sizing algorithm on outcomes of transcatheter aortic valve replacement: a prospective, multicenter, controlled trial, J. Am. Coll. Cardiol. (2013).

[7] G. Athappan, E. Patvardhan, E.M. Tuzcu, L.G. Svensson, P.A. Lemos, C. Fraccaro, et al., Incidence, predictors, and outcomes of aortic regurgitation after transcatheter aortic valve replacement: meta-analysis and systematic review of literature, J. Am. Coll. Cardiol. 61 (2013) 1585–1595.

[8] M.A. Sherif, M. Abdel-Wahab, B. Stocker, V. Geist, D. Richardt, R. Tolg, et al., Anatomic and procedural predictors of paravalvular aortic regurgitation after implantation of the medtronic corevalve bioprosthesis, J. Am. Coll. Cardiol. 56 (2010) 1623–1629.

[9] S. Bleiziffer, H. Ruge, J. Horer, A. Hutter, S. Geisbusch, G. Brockmann, et al., Predictors for new-onset complete heart block after transcatheter aortic valve implantation, JACC Cardiovasc. Interventions 3 (2010) 524–530.

[10] M. Barbanti, T.H. Yang, J. Rodes Cabau, C. Tamburino, D.A. Wood, H. Jilaihawi, et al., Anatomical and procedural features associated with aortic root rupture during balloon-expandable transcatheter aortic valve replacement, Circulation 128 (2013) 244–253.

[11] M. Akhtar, E.M. Tuzcu, S.R. Kapadia, L.G. Svensson, R.K. Greenberg, E.E. Roselli, et al., Aortic root morphology in patients undergoing percutaneous aortic valve replacement: evidence of aortic root remodeling, J. Thoracic Cardiovasc. Surg. 137 (2009) 950–956.

[12] L. Buellesfeld, S. Stortecky, B. Kalesan, S. Gloekler, A.A. Khattab, F. Nietlispach, et al., Aortic root dimensions among patients with severe aortic stenosis undergoing transcatheter aortic valve replacement, JACC Cardiovasc. Interventions 6 (2013) 72–83.

[13] P. Blanke, M. Russe, J. Leipsic, J. Reinohl, U. Ebersberger, P. Suranyi, et al., Conformational pulsatile changes of the aortic annulus: impact on prosthesis sizing by computed tomography for transcatheter aortic valve replacement, JACC Cardiovasc. Interventions 5 (2012) 984–994.

[14] L. Lehmkuhl, B. Foldyna, K. Von Aspern, C. Lucke, M. Grothoff, S. Nitzsche, et al., Inter-individual variance and cardiac cycle dependency of aortic root dimensions and shape as assessed by ecg-gated multi-slice computed tomography in patients with severe aortic stenosis prior to transcatheter aortic valve implantation: is it crucial for correct sizing, Int. J. Cardiovasc. Imaging 29 (2013) 693–703.

[15] L.M. de Heer, R.P. Budde, W.P. Mali, A.M. de Vos, L.A. van Herwerden, J. Kluin, Aortic root dimension changes during systole and diastole: evaluation with ecg-gated multidetector row computed tomography, Int. J. Cardiovasc. Imaging 27 (2011) 1195–1204.

[16] V. Delgado, A.C. Ng, J.D. Schuijf, F. van der Kley, M. Shanks, L.F. Tops, et al., Automated assessment of the aortic root dimensions with multidetector row computed tomography, Ann. Thoracic Surg. 91 (2011) 716–723.

[17] J. de Vaan, L. Verstraeten, P. de Jaegere, C. Schultz, The 3mensio valves multimodality workstation, Eurointervention: J. EuroPCR Collab. Working Group Interventional Cardiol. Eur. Soc. Cardiol. 7 (2012) 1464–1469.

[18] M.F. O'Rourke, W.W. Nichols, Aortic diameter, aortic stiffness, and wave reflection increase with age and isolated systolic hypertension, Hypertension 45 (2005) 652–658.

[19] A. Wolak, H. Gransar, L.E. Thomson, J.D. Friedman, R. Hachamovitch, A. Gutstein, et al., Aortic size assessment by noncontrast cardiac computed tomography: normal limits by age, gender, and body surface area, JACC Cardiovasc. Imaging 1 (2008) 200–209.

[20] S.S. Mao, N. Ahmadi, B. Shah, D. Beckmann, A. Chen, L. Ngo, et al., Normal thoracic aorta diameter on cardiac computed tomography in healthy asymptomatic adults: impact of age and gender, Acad. Radiol. 15 (2008) 827–834.

[21] R.R. Makkar, G.P. Fontana, H. Jilaihawi, S. Kapadia, A.D. Pichard, P.S. Douglas, et al., Transcatheter aortic-valve replacement for inoperable severe aortic stenosis, New Engl. J. Med. 366 (2012) 1696–1704.

Chapter 3: The Geometric Interaction Between a Novel TAVR Device and the Native Aortic Annulus

Monash University

Declaration for Thesis Chapter 3

Assessment of the Geometric Interaction Between the Lotus Transcatheter Aortic Valve Prosthesis and the Native Ventricular Aortic Interface by 320---Multidetector Computed Tomography

Declaration by candidate

In the case of Chapter 3, the nature and extent of my contribution to the work was the following:

Nature of contribution	**Extent of contribution (%)**
Review of existing literature, planning study protocol, collection and interpretation of data writing manuscript, creation of figures, editing manuscript	80%

The following co---authors contributed to the work.

Name	**Nature of contribution**	**Extent of contribution (%)**
Prof Ian Meredith	Planning study protocol, interpretation of data, writing and editing manuscript	10%
Prof James Cameron	Planning study protocol, interpretation of data, writing and editing manuscript	10%

The undersigned hereby certify that the above declaration correctly reflects the nature and extent of the candidate's and co---authors' contributions to this work.

Candidate's Signature	[redacted]	**Date** 12/04/2016

Main Supervisor's Signature	[redacted]	**Date** 12/04/2016

Preface

The work published in chapter 2 has quantified aortoventricular interface dimensions and identified baseline anthropomorphic and demographic predictors of these dimensions. Having formed a baseline for the population norms in relation to MDCT derived dimensions the following work, published in *JACC Cardiovascular Interventions*, moves to assess how a novel transcatheter aortic valve prosthesis alters this anatomy.

The geometric interaction between a TAVR prosthesis and the native anatomy is variable and important to describe and quantify as it may impact on prosthesis iteration, device sizing and deployment techniques. Self---expanding prostheses have been demonstrated on post---implantation imaging studies to accommodate to the native annular shape[1] more than balloon---expandable devices which tend to dominate and circularise the annulus[2]. As outlined in Chapter 1C, however, the Lotus valve is a new---generation device with a unique controlled mechanical expansion mechanism which will likely result in unique geometric interactions which have not previously been described.

The work demonstrates that the Lotus valve results in high rates of annular circularisation and near complete device expansion. Quantification of this interaction has helped in the formation of an appropriate sizing algorithm for the device.

1. Schultz CJ, Weustink A, Piazza N, et al. Geometry and degree of apposition of the CoreValve ReValving system with multislice computed tomography after implantation in patients with aortic stenosis. J Am Coll Cardiol 2009;54:911---8.
2. Willson AB, Webb JG, Gurvitch R, et al. Structural integrity of balloon---expandable stents after transcatheter aortic valve replacement: assessment by multidetector computed tomography. JACC Cardiovasc Interv 2012;5:525---32.

JACC: CARDIOVASCULAR INTERVENTIONS
VOL. 8, NO. 5, 2015

ISSN 1936-8798/$36.00
PUBLISHED BY ELSEVIER INC.
http://dx.doi.org/10.1016/j.jcin.2015.03.002

Assessment of the Geometric Interaction Between the Lotus Transcatheter Aortic Valve Prosthesis and the Native Ventricular Aortic Interface by 320-Multidetector Computed Tomography

Robert P. Gooley, MD, James D. Cameron, MD, Ian T. Meredith, AM, MD

ABSTRACT

OBJECTIVES This study sought to assess the geometric interaction between the Lotus Valve System transcatheter aortic prosthesis (Boston Scientific, Natick, Massachusetts) and the native aortoventricular interface using multidetector computed tomography (MDCT).

BACKGROUND The interaction between transcatheter aortic valve prostheses and native anatomy is variable, although potentially predictable. The Lotus transcatheter device uses a novel mechanical means of expansion, the effect of which on native anatomic geometry has not previously been described.

METHODS Forty patients treated with the Lotus prosthesis were enrolled. The patients underwent 320-MDCT imaging before and after implantation. Prosthesis dimensions and relevant interaction parameters, including circularity and expansion, were assessed. The degree of paraprosthetic regurgitation (PAR) and prosthesis gradient were measured by transthoracic echocardiography at the same time points.

RESULTS The mean baseline annular eccentricity index (EI) was 0.21 ± 0.06 and left ventricular outflow tract EI was 0.31 ± 0.09. The deployed prostheses had high rates of circularity with a mean EI across all device segments of 0.06 ± 0.04. In noncircular device deployment, an EI > 0.1 was identified in 25% of prostheses and was associated with greater native annular eccentricity at baseline compared with circular devices (0.24 ± 0.04 vs. 0.19 ± 0.06, p ¼ 0.01). The median percent of expansion was 97.5 ± 3.8% in the inflow portion of the prosthesis. Twenty-five percent of prostheses were <90% expanded in at least 1 segment with a numerical, but not statistically significant, association between oversizing and underexpansion. No correlation was found between device underexpansion and the mean transprosthesis gradient or between noncircularity and PAR.

CONCLUSIONS The Lotus prosthesis results in nearly full device expansion and circularization of the native basal plane. Awareness of the anatomic interaction between this unique device and the native architecture may help in the formulation of appropriate device-specific sizing algorithms. (J Am Coll Cardiol Intv 2015;8:740–9) © 2015 by the American College of Cardiology Foundation.

Transcatheter aortic valve replacement (TAVR) has gained widespread acceptance as a treatment for suitably selected high- and extreme-risk patients with symptomatic severe aortic stenosis. An increasing number of devices are entering research and clinical practice, often with unique features designed to reduce recognized complications, improve efficacy, and increase ease of use.

From the MonashHeart, Monash Health, Clayton, Victoria, Australia; and Monash Cardiovascular Research Centre, Department of Medicine (MMC), Monash University, Clayton, Victoria, Australia. Dr. Meredith is a consultant for and is on the Speakers Bureau of Boston Scientific; and is on the Advisory Board of Strategic. Dr. Gooley received a scholarship from the National Health and Medical Research Council of Australia for his research. Dr. Cameron has reported that he has no relationships relevant to the contents of this paper to disclose.

Manuscript received October 20, 2014; revised manuscript received February 23, 2015, accepted March 3, 2015.

Successful TAVR relies on accurate pre-procedural imaging to appropriately size the transcatheter prosthesis. Improved pre-procedural sizing, including the use of 3-dimensional multiple detector computed tomography (MDCT)–based screening, has contributed to a reduction in complications such as paraprosthetic aortic regurgitation (PAR) (1–3), pacing requirement (4), device embolization, and annular injury (5).

Although much focus has been on 3-dimensional pre-procedural assessment, equally important in ensuring procedural efficacy and safety is an awareness of the interaction that a given TAVR device might have with the native anatomy. Self-expanding prostheses such as the CoreValve (Medtronic, Minneapolis, Minneapolis), when positioned in a noncircular native annulus, tend to remain slightly eccentric (6). Balloon-expandable prostheses, how- ever, such as the SAPIEN valve (Edwards Lifesciences, Irvine, California) tend to circularize even an eccen- tric native annulus (7,8).

Awareness of this variability in device-annulus interaction is important in determining what degree of prosthesis oversizing is efficacious yet safe. Deploying a device of slightly larger area or perimeter than the native annulus, i.e., oversizing, has been used with the current generation of devices to ensure device stability and help minimize PAR (1). This approach must be balanced against overdistention of the annulus and outflow tract with an increased risk of annular injury and/or pacing requirement. Oversizing may equally result in an underexpanded or noncircular prosthesis, which may, in turn, lead to accelerated valve wear.

The interaction of the Lotus Valve System (Boston Scientific, Natick, Massachusetts) with its unique expansion and locking mechanism (9) (Figure 1A) with the native annulus has not previously been described. Description and quantification of this relationship will help in the development of appropriate sizing algorithms for this novel device.

METHODS

POPULATION. Forty patients undergoing TAVR using the Lotus Valve System at our cardiac center were prospectively enrolled. All patients were being treated for symptomatic severe aortic stenosis and had been deemed to be at high surgical risk by the institution's heart team. An independent case review committee reviewed all cases before acceptance into the trial. All patients met the previously reported inclusion and exclusion criteria for the Boston Scientific REPRISE (Repositionable Percutaneous Replacement of Stenotic Aortic Valve Through Implantation of Lotus Valve System) trials (10). This study formed a single-center substudy within the REPRISE trials. Ethics approval was obtained from the institutional Human Research Ethics Committee.

IMAGING. All subjects underwent retrospectively electrocardiography-gated, 320-MDCT imaging of the aortic root before device implantation. Twenty-five patients subsequently underwent imaging at 32.7 ± 1.2 days, and 15 patients underwent imaging at 384.5 ± 11.4 days after implantation. All scans were performed on a Toshiba Aquilion One 320-detector row scanner (Toshiba Medical Systems, Otawara, Japan). No heart rate control was used. Seventeen scans were performed using prospective electrocardiographic gating with a temporal window between 75% and 85% of the R-R interval, whereas 23 scans used a retrospective (full R-R interval) window. Collimation was individualized to achieve a z-axis that encompassed the entire aortic root. The slice thickness was 0.5 mm. The gantry rotation speed was 275 ms per rotation, the tube voltage was 100 to 120 kV, and the tube current individualized to body habitus.

MDCT ANALYSIS. Pre-procedural imaging. All scans were analyzed using the 3Mensio Structural Heart analysis program, version 7 (3Mensio, Bilthoven, the Netherlands) and the Vitrea Fx workstation (Vital Images, Minneapolis, Minnesota).

The aortic valve basal plane was defined as the short-axis plane through the nadir of each coronary cusp. The minimal diameter (D_{min}), maximal diameter (D_{max}), perimeter, and area were measured in this short axis. The circularity of the basal plane was expressed as the eccentricity index [EI ¼ 1 – (D_{min}/D_{max})]. This metric was previously demonstrated to correlate with post-procedural aortic regurgitation (3).

The left ventricular outflow tract (LVOT) was assessed in the short-axis 4 mm below the basal plane, perpendicular to the center line. Minimal and maximal diameters, perimeter, and area were measured at this level, with the eccentricity expressed as the EI. The sinus of Valsalva width, perimeter, and area were measured at the widest point of the sinus. The height of each coronary sinus was measured from the basal plane to the sinotubular junction in a stretched multiplanar image. The coronary artery heights were measured from the basal plane to the lowest border of each coronary ostia in a stretched multiplanar image. The angulation of the aortic valve plane was measured in relation to the horizontal plane.

ABBREVIATIONS AND ACRONYMS

EI = eccentricity index

LVOT = left ventricular outflow tract

MDCT = multidetector computed tomography

PAR = paraprosthetic aortic regurgitation

TAVR = transcatheter aortic valve replacement

JACC: CARDIOVASCULAR INTERVENTIONS VOL. 8, NO. 5, 2015
APRIL 27, 2015: 740–9

FIGURE 1 Lotus TAVR Prosthesis

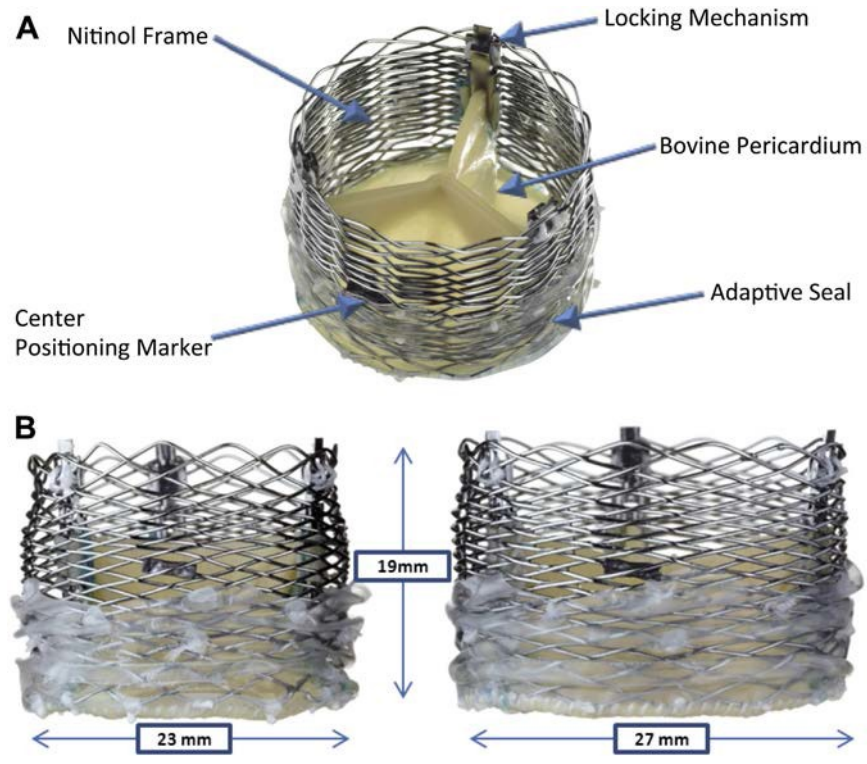

Lotus Valve System transaortic valve replacement (TAVR) prosthesis (Boston Scientific, Natick, Massachusetts). (A) Components. (B) Lotus prosthesis dimensions.

The degree of calcification at the level of the LVOT and basal plane was semiquantitatively graded as none, mild (1 nodule protruding <5 mm and covering <10% of the perimeter), moderate (2 nodules or 1 nodule protruding more than 5 mm or covering more than 10% of the perimeter), or severe (multiple nodules or a single nodule protruding more than 1 cm or covering more than 20% of the perimeter), and the distribution of calcification in relation to the coronary cusps was assessed as previously reported (5).

Prostheses were sized on the basis of baseline MDCT measurements and manufacturer recommendations for the REPRISE trials. Two device sizes were available, 23 mm was used for derived annular diameters 18 to 23 mm and 27 mm was used for derived annular diameters 23 to 27 mm (Figure 1B).

Post-procedural imaging. The same MDCT scanning protocol was used for post-procedural 320-MDCT scans. The prosthesis was identified, and a short axis plane was positioned through the aortic aspect of the 3 locking mechanisms. The locking mechanisms were chosen because they remain at a stable outflow position, whereas the inflow edge of the frame may adopt a more variable depth along its circumference when the device is oversized. A center line perpendicular to the prosthesis was generated.

The maximal and minimal prosthesis diameters were measured in the short axis at 3 levels (inflow, mid-prosthesis, outflow). At each level, the circularity, expressed as the EI, was calculated with an EI > 0.10 considered to be noncircular, in keeping with previously published studies investigating other TAVR devices. The percent of expansion of the device (MDCT-derived prosthesis area/nominal prosthesis area × 100) was also calculated at each level, with a percent of expansion <90% considered underdeployed. The prosthesis frame height and depth of implant in relation to the nadir of the sinus of Valsalva were measured in the stretched multiplanar image.

The height of the coronary arteries was measured from the inflow edge of the TAVR prosthesis, noting whether the stent frame extended beyond their origin. In instances in which the coronary arteries were behind the stent frame, the difference between cross-sectional area of the sinus of Valsalva and the

cross-sectional area of the prosthesis at the level of the coronary artery was measured. This gave an estimate of the adequacy of the sinus volume to accommodate the prosthesis but avoid coronary obstruction.

The degree of prosthesis-tissue interaction at the level of the annulus and LVOT was qualitatively assessed, and the percent of prosthesis circumference nonapposed was calculated.

The 23 scans performed with a retrospective protocol were analyzed in systole (20% to 30% R-R interval) and diastole (75% to 85% R-R interval) to assess for prosthesis deformation during the cardiac cycle. A blinded observer assessed the leaflet mobility and thickness in these scans using multiplanar 3-dimensional reformations on the Vitrea Fx work platform (Vital Images). Comparison was made between circular and noncircular prostheses and between the 30-day and 1-year time points.

TRANSTHORACIC ECHOCARDIOGRAPHY. All patients underwent transthoracic echocardiography at baseline and at the same time point as the post-procedural MDCT scan. All transthoracic echocardiography scans were performed using a Vivid 7 (GE Healthcare, Milwaukee, Wisconsin). An independent echocardiography core laboratory assessed all scans for measurement of transprosthesis gradient and degree of PAR.

STATISTICAL ANALYSIS. Categorical variables were expressed as frequencies and percents, and continuous variables were expressed as means and SDs. Categorical variables were compared using a chi-square test, and nonparametric continuous variables were compared using the paired-sample *t* test. A 2-sided p value <0.05 was considered statistically significant. Statistical analysis was performed using IBM SPSS Statistics version 22.0 (IBM Corporation, New York, New York).

RESULTS

POPULATION. Forty patients (32.5% male) who were undergoing TAVR using the Lotus Valve System were prospectively enrolled. The mean age was 83.5 ± 5.0 years, and the mean Society of Thoracic Surgeons mortality risk score was 5.7 ± 1.2%. Baseline characteristics are outlined in Table 1.

All patients had successful implantation of a single Lotus prosthesis. Eighteen patients (45.0%) received a 27-mm device, and the remainder were treated with a 23-mm device.

MDCT ASSESSMENT. Baseline assessment. An experienced computed tomography cardiologist adjudicated all scans to be of good quality with adequate contrast opacification and minimal temporal artifact. The mean eccentricity during the systolic phase at the level of the basal plane was 0.21 ± 0.06 and

TABLE 1 Baseline Characteristics (N ¼ 40)

Male	13 (32.5)
Age, yrs	83.5 ± 5.0
Height, m	1.61 ± 0.10
Weight, kg	73.5 ± 17.4
BMI, kg/m^2	28.5 ± 6.7
STS PROM	5.7 ± 2.6
EuroSCORE II	7.7 ± 6.6
LVEF, %	57.7 ± 11.5
AVA, mm^2	0.73 ± 0.18
Mean aortic gradient, mm Hg	47.7 ± 11.9

Values are n (%) or mean ± SD.

AVA ¼ aortic valve area; BMI ¼ body mass index; EuroSCORE ¼ European System for Cardiac Operative Risk Evaluation; LVEF ¼ left ventricular ejection fraction; STS PROM ¼ Society of Thoracic Surgeons Predicted Risk of Mortality Score.

TABLE 2 Baseline MDCT Dimensions and Procedural Characteristics (N ¼ 40)

Basal plane	
D_{min}, mm	21.0 ± 1.8
D_{max}, mm	26.6 ± 2.1
Perimeter, mm	75.3 ± 5.7
Area, mm^2	431.8 ± 65.8
Eccentricity index	0.21 ± 0.06
LVOT	
D_{min}, mm	18.8 ± 2.5
D_{max}, mm	27.3 ± 2.3
Perimeter, mm	74.1 ± 6.4
Area, mm^2	399.4 ± 76.2
Eccentricity index	0.31 ± 0.09
Sinus of Valsalva	
Area, mm^2	753.4 ± 104.6
Average height, mm	21.1 ± 1.6
Coronary artery height, mm	
LMCA	15.2 ± 2.8
RCA	17.0 ± 2.5
Procedure	
Implanted prosthesis size, 23/27 mm	22/18
New pacemaker implantation	11 (27.5)
PAR at 30 days	
None/trivial	35 (87.5)
Mild	5 (12.5)
Moderate	0 (0)
Severe	0 (0)
Mean gradient at follow-up, mm Hg	11.9 ± 5.1

Values are n (%) or mean ± SD.

D_{max} ¼ maximal diameter; D_{min} ¼ minimal diameter; LMCA ¼ left main coronary artery; LVOT ¼ left ventricular outflow tract; MDCT ¼ multidetector computed tomography; PAR ¼ paraprosthetic aortic regurgitation; RCA ¼ right coronary artery.

JACC: CARDIOVASCULAR INTERVENTIONS VOL. 8, NO. 5, 2015
APRIL 27, 2015: 740–9

FIGURE 2 Assessment of Calcific Burden and Distribution

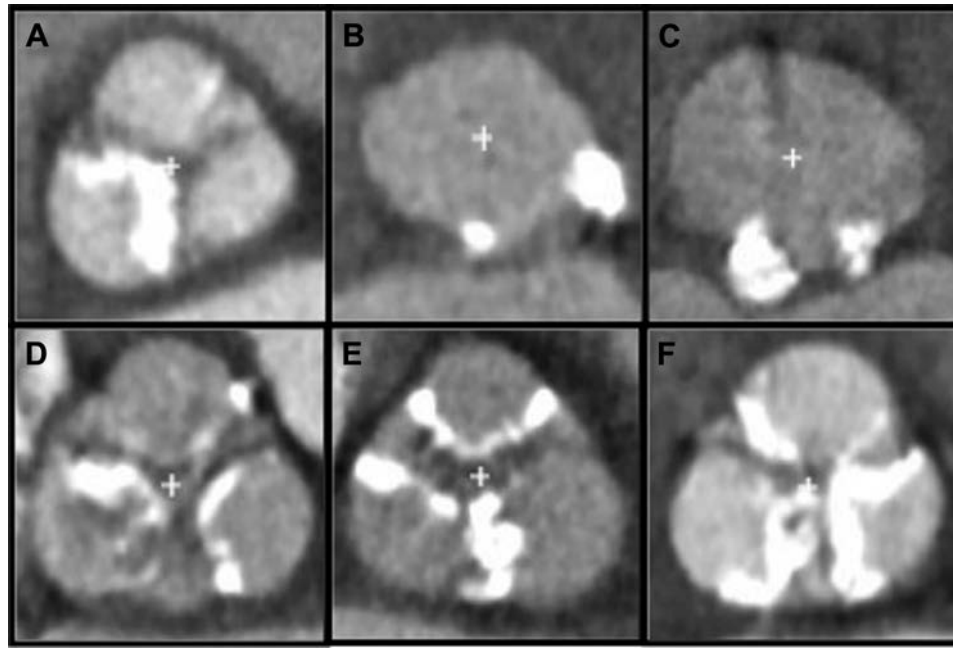

(A) Eccentric leaflet calcification. (B) Calcific nodules at the level of the left ventricular outlet tract. (C) Calcific nodules at the level of the basal plane. (D) Mild leaflet calcification. (E) Moderate leaflet calcification. (F) Heavy leaflet calcification.

0.31 ± 0.09 at the level of the LVOT. Further baseline MDCT dimensions throughout the aortoventricular interface are described in Table 2.

The annular calcification burden was assessed as none, mild, moderate, and severe in 45%, 30%, 22.5%, and 2.5% of patients, respectively. It was also noted that annular/leaflet calcification was unevenly distributed in 30%. LVOT calcification was assessed as none, mild, moderate, and severe in 45%, 30%, 22.5%, and 2.5%, respectively, with calcific nodules located below the left, right, and noncoronary cusps in 88.9%, 11.1%, and 66.7%, respectively, of those

TABLE 3 Aortoventricular Interface Calcification and Its Relation to PAR and Expansion

	Entire Cohort (N ¼ 40)	No/ Minor PAR (n ¼ 35)	Mild PAR (n ¼ 5)	p Value	Underexpanded (n ¼ 10)	Fully Expanded (n ¼ 30)	p Value	Noncircular (n ¼ 10)	Circular (n ¼ 30)	p Value
Basal plane										
None	18 (45)	18 (51.4)	0 (0)		2 (20)	16 (53.3)		1 (10)	17 (56.7)	
Mild	12 (30)	11 (31.4)	1 (20)		6 (60)	6 (20)		6 (60)	6 (20)	
Moderate	9 (22.5)	5 (14.3)	4 (80)		2 (20)	7 (23.3)		2 (20)	7 (23.3)	
Severe	1 (2.5)	1 (2.9)	0 (0)	0.01	0 (0)	1 (3.3)	0.10	1 (10)	0 (0)	0.01
LVOT										
None	31 (77.5)	28 (80)	3 (60)		7 (70)	24 (80)		5 (50)	26 (86.7)	
Mild	5 (12.5)	3 (8.6)	2 (40)		2 (20)	3 (10)		3 (30)	2 (6.7)	
Moderate	3 (7.5)	3 (8.6)	0 (0)		1 (10)	2 (6.7)		1 (10)	2 (6.7)	
Severe	1 (2.5)	1 (2.9)	0 (0)	0.23	0 (0)	1 (3.3)	0.77	1 (10)	0 (0)	0.06
Location if present										
Left coronary cusp	8 (88.9)	5 (71.4)	1 (50)		2 (66.7)	6 (100)		3 (60)	2 (50)	
Right coronary cusp	1 (11.1)	0 (0)	1 (50)		0	1 (16.7)		1 (20)	0 (0)	
Noncoronary cusp	6 (66.7)	4 (57.1)	2 (100)	0.45	3 (100)	3 (50)	0.52	2 (40)	3 (75)	0.36

Values are n (%).
Abbreviations as in Table 2.

patients where calcium was present (Figure 2). No differences were observed in the severity or location of calcification in those with mild PAR compared with those with none or trivial PAR or between underexpanded and fully expanded prostheses (Table 3).

Eccentricity. MDCT-derived prosthesis dimensions are presented in Table 4. The mean EI was 0.06 ± 0.04 across all prosthesis segments. Ten prostheses and 16 prosthesis segments were found to be noncircular as defined by an EI >0.10 (range 0.10 to 0.19) (Figures 3A and 3B). One device was noncircular throughout the frame height (EI ¼ inflow, 0.19; mid, 0.11; outflow, 0.12), 3 were eccentric in the mid- and inflow segments, 2 were eccentric only in the mid segment, whereas the other 4 devices were noncircular in the inflow segment but circularized in the mid- and outflow segments.

The native basal plane before implantation was significantly more eccentric among those patients who had noncircular deployment occur (0.24 ± 0.04) compared with those with circular deployment (0.19 ± 0.06) (p ¼ 0.01). Although the baseline LVOT was also more eccentric in patients with a noncircular deployment (0.34 ± 0.10 vs. 0.30 ± 0.09), this was not statistically different (p ¼ 0.25).

Assessment of baseline calcification as a risk factor for eccentric deployment revealed that 60% of patients in whom the device was noncircular had mild annular calcification, 20% had moderate, and 10% had severe, which was significantly greater than that observed in those with circular deployment (20%, 23.3%, and 0%, respectively; p ¼ 0.01). The degree of LVOT calcification was numerically greater although not statistically different (p ¼ 0.06) (Table 3).

Expansion. The mean percent of frame expansion was 98.0 ± 5.3%. An underexpanded prosthesis segment (percent of expansion <90%) was found in 10 patients (Figures 3C and 3D). Five of these patients also had noncircular deployment. One prosthesis was underexpanded in the inflow segment (86.5%) and 9 in the mid-segment (71.3% to 87.5%). No prostheses were underexpanded in the outflow segment. Although underexpanded prostheses were numerically more oversized than fully expanded prostheses (area oversizing, 17.3 ± 16.7% vs. 11.6 ± 10.5%; perimeter oversizing, 5.3 ± 7.4% vs. 3.1 ± 4.9%), this did not reach significance. No significant difference was identified between the extent of annular or LVOT calcification and degree of expansion (Table 3).

Underexpansion was not associated with an increase in mean pressure gradient at 30 days with a numerically lower, although not statistically significant, gradient in this cohort (9.2 ± 4.9 mm Hg in the underexpanded cohort vs. 12.8 ± 4.9 mm Hg in the fully expanded cohort, p ¼ 0.06).

Prosthesis position. The mean prosthesis height was 19.2 ± 0.5 mm, and the mean implantation depth below the nadir of the coronary sinuses was

TABLE 4 MDCT Assessment of Lotus Prosthesis at Follow-Up

	Prosthesis Segment				
	Inflow	Mid	Outflow	Average	p Value*
23 mm (n ¼ 22)					
D_{min}, mm	22.0 ± 0.8	22.0 ± 1.0	22.7 ± 0.6	22.2 ± 0.8	0.51
D_{max}, mm	23.4 ± 0.5	23.2 ± 0.7	23.5 ± 0.5	23.4 ± 0.6	0.26
Area, mm^2	403.9 ± 17.1	401.6 ± 26.7	419.8 ± 12.5	408.4 ± 18.8	0.96
Perimeter, mm	71.5 ± 1.5	71.2 ± 2.4	72.8 ± 1.1	71.8 ± 1.7	0.92
27 mm (n ¼ 18)					
D_{min}, mm	25.8 ± 0.7	25.1 ± 1.7	26.7 ± 0.9	25.9 ± 1.1	0.89
D_{max}, mm	27.7 ± 0.8	26.8 ± 1.1	27.8 ± 0.7	27.4 ± 0.9	0.14
Area, mm^2	560.9 ± 19.9	530.1 ± 52.6	587.8 ± 29.0	559.6 ± 38.3	0.06
Perimeter, mm	84.2 ± 1.5	81.9 ± 4.0	81.8 ± 18.8	82.6 ± 8.1	0.08
Eccentricity index	0.07 ± 0.04	0.06 ± 0.05	0.04 ± 0.03	0.06 ± 0.04	0.06
% Expansion	97.5 ± 3.8	94.8 ± 8.0	101.8 ± 4.1	98.0 ± 5.3	0.21

Values are mean ± SD. *p Value compares inflow and outflow values.
Abbreviations as in Table 2.

FIGURE 3 Assessment of Prosthesis Circularity and Expansion

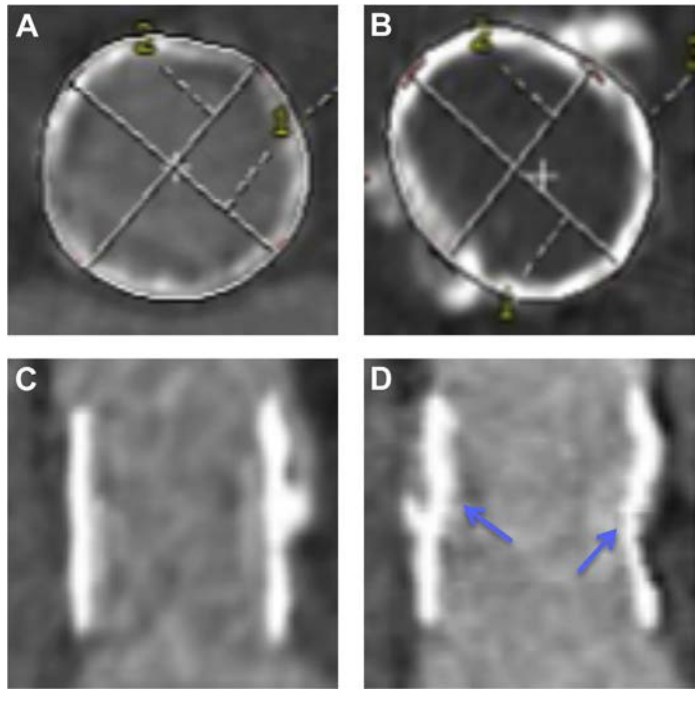

(A) A circular prosthesis with an eccentricity index (EI) ¼ 0.01. (B) An eccentric prosthesis with EI ¼ 0.18. (C) An evenly expanded prosthesis with no waisting. (D) An underexpanded prosthesis at the basal plane level with waisting of the device (blue arrows) at this point.

print & web 4C-FPO

JACC: CARDIOVASCULAR INTERVENTIONS VOL. 8, NO. 5, 2015
APRIL 27, 2015: 740–9

FIGURE 4 Assessment of Residual Sinus Area

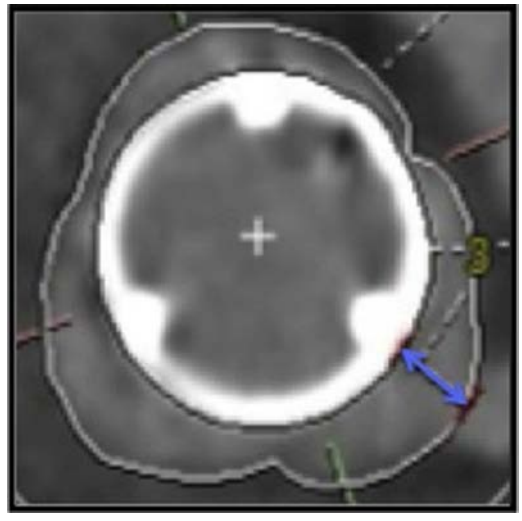

Assessment of the sinus area surrounding the Lotus prosthesis (Boston Scientific, Natick, Massachusetts) at the level of the left main coronary artery. Blue arrow indicates the distance between the prosthesis and the left main coronary artery.

TABLE 5 Prosthesis Integrity Throughout the Cardiac Cycle (n ¼ 23)

	Systole	Diastole	p Value
Inflow			
D_{min}, mm	23.9 ± 1.9	23.6 ± 2.4	0.45
D_{max}, mm	25.4 ± 2.1	25.3 ± 2.7	0.70
Area, mm^2	479.8 ± 76.4	489.0 ± 76.4	0.46
Perimeter, mm	77.7 ± 6.2	78.5 ± 6.3	0.53
Eccentricity index	0.06 ± 0.04	0.07 ± 0.04	0.30
% Expansion	97.9 ± 3.4	99.8 ± 3.7	0.60
Mid			
D_{min}, mm	23.5 ± 2.2	23.7 ± 2.1	0.08
D_{max}, mm	25.0 ± 2.0	25.1 ± 2.0	0.40
Area, mm^2	465.6 ± 79.4	466.9 ± 74.8	0.65
Perimeter, mm	76.5 ± 6.4	76.8 ± 5.9	0.20
Eccentricity index	0.06 ± 0.05	0.05 ± 0.05	0.56
% Expansion	95.2 ± 8.1	95.6 ± 8.1	0.45
Outflow			
D_{min}, mm	24.5 ± 2.1	24.7 ± 2.1	0.09
D_{max}, mm	25.4 ± 2.3	25.4 ± 2.4	0.92
Area, mm^2	494.0 ± 87.0	493.2 ± 88.2	0.87
Perimeter, mm	78.7 ± 7.0	78.8 ± 7.0	0.87
Eccentricity index	0.04 ± 0.03	0.03 ± 0.03	0.66
% Expansion	100.6 ± 4.3	100.4 ± 4.0	0.81

Values are mean ± SD.
Abbreviations as in Table 2.

3.6 ± 1.2 mm. The prosthesis protruded above the left main coronary artery in 65.0% of patients and above the right coronary artery in 40.0%. In patients who had the coronary ostia beneath the aortic frame edge, a mean difference of 298.5 ± 91.2 mm^2 remained between the sinus area and prosthesis area at this point, with a mean distance of 5.2 ± 1.6 mm from the coronary artery ostium to the prosthesis edge (Figure 4).

No contrast could be identified between the prosthesis and native tissue at either the annular or LVOT level, indicating complete apposition of all prostheses.

Prosthesis integrity throughout the cardiac cycle. There were no significant changes in prosthesis dimensions, circularity, or expansion throughout the cardiac cycle in the 23 patients who underwent retrospectively gated MDCT scanning (Table 5).

Leaflet excursion was symmetrical and without restriction in all 23 patients. Neither leaflet calcification nor thickening was identified in any prostheses; in addition, no difference was found between underexpanded and fully expanded prostheses. Blinded comparison of prostheses at 30 days and 1 year found no difference in leaflet function during the cardiac cycle or leaflet morphology.

Echocardiographic assessment of prosthesis function. At follow-up, 35 patients (87.5%) had none or minor PAR, 5 patients (12.5%) had mild, and there were no patients with moderate or greater PAR. In the 5 patients with mild PAR, 4 (80%) had moderate and 1 (20%) mild basal plane calcification compared with 14.3% and 31.4%, respectively, in those with none or minor PAR (p ¼ 0.01) (Table 3).

No association was found between noncircular deployment and the presence of PAR with 4 cases of mild PAR in devices that were circularly deployed (EI < 0.10) and only 1 case of mild PAR in the more eccentric cohort (EI > 0.10) (p ¼ 0.84). The mean transprosthetic gradient at follow-up was 11.9 ± 5.1 mm Hg. There was no correlation between underexpansion and the severity of this gradient (9.2 ± 4.9 mm Hg vs. 12.8 ± 4.9 mm Hg, p ¼ 0.06).

DISCUSSION

Previous post-TAVR imaging studies demonstrated that balloon-expandable devices result in circularization of the native annulus (7,8), whereas similar studies of self-expanding devices suggest that the prostheses remain more eccentric when deployed in eccentric annuli (6). The Lotus transcatheter heart valve uses a unique mechanism of deployment, expansion and locking, the effect of which on the prosthesis–native aortoventricular interface interaction was previously unknown.

FIGURE 5 Interaction Between Native Annular Eccentricity and Prosthesis Eccentricity

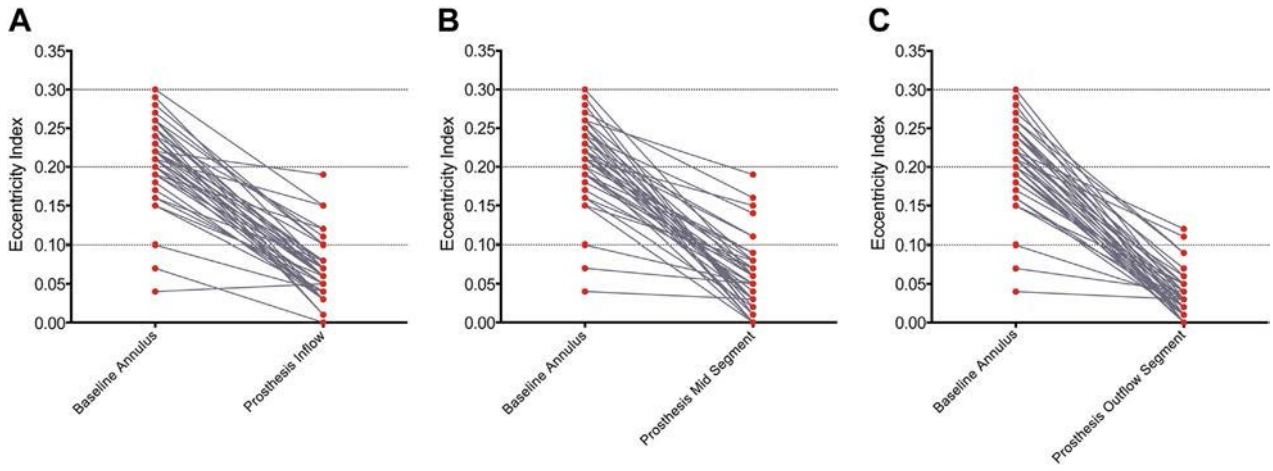

(A) Change from baseline annular eccentricity to prosthesis eccentricity at in*flow* level. (B) Change from baseline annular eccentricity to prosthesis eccentricity at mid-level. (C) Change from baseline annular eccentricity to prosthesis eccentricity at out*flow* level.

A number of published case studies following patients with underexpanded or noncircular prostheses suggested that even in these cases, good short-term function and durability are achieved (11,12). There are no large-scale in vivo studies that assessed possible deleterious effects of abnormal transcatheter prosthesis deployment, eccentricity, or underexpansion. In vitro computational data, however, indicate that noncircularity of surgically implanted bioprostheses may lead to increased mechanical stress on the valve leaflets and higher rates of valve incompetence (13). It is, therefore, possible, although not proven, that noncircular deployment of TAVR prostheses may also lead to earlier degeneration and that prostheses that obtain high rates of circular expansion may be more durable.

ECCENTRICITY. This study demonstrates that the Lotus TAVR prosthesis results in high rates of circular deployment at all prosthesis levels (EI ¼ 0.05 ± 0.04) even in the presence of significant baseline annular eccentricity (EI ¼ 0.21 ± 0.06). The prosthesis was noncircular (EI >0.10) at follow-up in 10 patients in a total of 16 segments (range 0.10 to 0.19) (Figure 5). Patients who had noncircular deployment occur had a significantly more eccentric native basal plane at baseline than those who had the prosthesis circularly deployed. This suggests that greater baseline eccentricity at the annular level may result in noncircular prosthesis deployment and should be factored into pre-procedural anatomic assessment. It should, however, be recognized that the greatest prosthesis EI was only 0.19, which equates to a difference of 4.5 mm between the minimal and maximal diameters.

We also identified a significantly greater burden of annular calcification and a trend toward greater LVOT calcification in those with noncircular deployment. Previous studies indicated that the severity of aortic valve calcification (14,15) or the degree of calcification in the landing zone of the device (16) is associated with PAR. Whether this association is due to eccentricity of the deployed device from calcium invaginating the frame or preventing symmetrical deployment has not been proven. In our cohort, we observed a greater burden of eccentric leaflet and deployment site calcification in patients in whom the deployed prosthesis was noncircular. This result should be interpreted carefully given the small number of cases of PAR.

Although prosthesis eccentricity has been linked with PAR (1) in other device studies, we did not observe such a relationship in our cohort. There were very low rates of PAR with only 5 cases (12.5%) of mild PAR and no cases of moderate or greater PAR. Although this could be attributable to the tendency of the Lotus TAVR prosthesis to circularize the annulus, this device also has an adaptive seal around the lower half of the frame (Figure 1) that is designed to accommodate any residual interstices after deployment and thus reduce PAR. The potential efficacy of the adaptive seal was also observed in the lack of contrast between the valve frame and native tissue, indicating nearly complete apposition.

JACC: CARDIOVASCULAR INTERVENTIONS VOL. 8, NO. 5, 2015
APRIL 27, 2015: 740–9

EXPANSION. We identified 10 prostheses (25%) that were underexpanded, 1 in the inflow segment and 9 in the mid-segment. Underexpansion of SAPIEN devices has previously been shown to occur most commonly in the inflow segment, correlating with the more constrained LVOT/annular level (7); how- ever, underexpansion was much more common in the middle of the frame height in our cohort. This may be due in part to the unique locking mechanism of the Lotus prosthesis, whereby the valve frame is not forcibly balloon expanded but shortens along 3 evenly spaced mandrels. The more rigid locking attachments are at the inflow and outflow por- tions of the frame with only the thin mandrels running between these points. This may provide greater opportunity for incomplete expansion of the mid-frame.

Although significant oversizing of the prosthesis would conceivably result in underexpansion, such a correlation was not proven in our cohort. Although there was numerically greater oversizing in these 10 patients, this difference was not statistically significant (area oversizing, 17.3 ± 16.7% vs. 11.6 ± 10.5%, p ¼ 0.33). Similarly there was no increase in trans-prosthesis mean gradient as a result of under-expansion in this cohort with a nonsignificant, numerically lower gradient in the underexpanded devices (9.2 ± 4.9 mm Hg in the underexpanded cohort vs. 12.8 ± 4.9 mm Hg in the fully expanded cohort, p ¼ 0.06).

CORONARY POSITION. Contrary to some devices, the Lotus pre-procedural sizing protocol does not dictate a specific minimal required distance between the annulus and coronary ostia, but rather mandates a combined assessment together with sinus of Valsalva height, sinus of Valsalva area, calcific burden, and calcification distribution. Despite the prosthesis extending above the coronary ostia in 28 patients (70%), there were no instances of coronary obstruction, with a mean residual sinus area of 298.5 ± 91.2 mm^2 and a mean of 5.2 ± 1.6 mm between the frame and coronary ostia.

STUDY LIMITATIONS. This must be considered a pilot study with a modest study population that makes it difficult to determine associations between the native anatomic features and resultant prosthesis deployment or between the prosthesis deployment and resultant valve hemodynamics. Similar studies assessing other TAVR prostheses by MDCT have, however, had similar or even smaller population sizes. These limited studies are, however, important in furthering the understanding of physicians regarding the interaction that each device type has with the native architecture and the effects this has on procedural sizing, device function, and safety.

CONCLUSIONS

The Lotus transcatheter prosthesis results in high rates of full expansion and appears to result in circularization of the native annulus with low trans-prosthesis gradients and minimal PAR. Awareness of these features may aid in the formulation of appropriate sizing algorithms that use the idea of right sizing rather than oversizing to ensure appro- priate annular occupation, circularity, and expansion while minimizing procedural and post-procedural complications.

REPRINT REQUESTS AND CORRESPONDENCE: Dr. Robert Gooley, Department of Medicine, Monash Cardiovascular Research Centre, Monash Health, Monash University, 246 Clayton Road, Clayton 3168, Victoria, Australia.[redacted]

PERSPECTIVES

The interaction between transcatheter aortic valve prostheses and native anatomy is variable, although potentially predictable. The Lotus transcatheter device uses a novel mechanical means of expansion, the effect of which on native anatomic geometry has not been previously described. The Lotus device results in high rates of native annulus circularization and prosthesis expansion. The clinical effects of these geometric interactions should be tested in larger randomized trials.

REFERENCES

1. Athappan G, Patvardhan E, Tuzcu EM, et al. Incidence, predictors, and outcomes of aortic regurgitation after transcatheter aortic valve replacement: meta-analysis and systematic review of literature. J Am Coll Cardiol 2013;61:1585–95.

2. Willson AB, Webb JG, Labounty TM, et al. 3-Dimensional aortic annular assessment by multidetector computed tomography predicts moderate or severe paravalvular regurgitation after transcatheter aortic valve replacement: a multicenter retrospective analysis. J Am Coll Cardiol 2012;59:1287–94.

3. Wong DT, Bertaso AG, Liew GY, et al. Relationship of aortic annular eccentricity and

paravalvular regurgitation post transcatheter aortic valve implantation with CoreValve. J Invasive Cardiol 2013;25:190–5.

4. Bleiziffer S, Ruge H, Horer J, et al. Predictors for new-onset complete heart block after transcatheter aortic valve implantation. J Am Coll Cardiol Intv 2010;3:524–30.

5. Barbanti M, Yang TH, Rodes Cabau J, et al. Anatomical and procedural features associated with aortic root rupture during balloon-expandable transcatheter aortic valve replacement. Circulation 2013;128:244–53.

6. Schultz CJ, Weustink A, Piazza N, et al. Geometry and degree of apposition of the CoreValve ReValving system with multislice computed tomography after implantation in patients with aortic stenosis. J Am Coll Cardiol 2009;54:911–8.

7. Willson AB, Webb JG, Gurvitch R, et al. Structural integrity of balloon-expandable stents after transcatheter aortic valve replacement: assessment by multidetector computed tomography. J Am Coll Cardiol Intv 2012;5:525–32.

8. Delgado V, Ng AC, van de Veire NR, et al. Transcatheter aortic valve implantation: role of multi-detector row computed tomography to evaluate prosthesis positioning and deployment in relation to valve function. Eur Heart J 2010;31:1114–23.

9. Gooley R, Lockwood S, Antonis P, Meredith IT. The SADRA Lotus Valve System: a fully repositionable, retrievable prosthesis. Minerva Cardioangiol 2013;61:45–52.

10. Meredith IT, WS, Whitbourn RJ, et al. Transfemoral aortic valve replacement with the repositionable Lotus Valve System in high surgical risk patients: the REPRISE I study. EuroIntervention 2014;9:1264–70.

11. Ussia GP, Barbanti M, Tamburino C. Consequences of underexpansion of a percutaneous aortic valve bioprosthesis. J Invasive Cardiol 2010;22:E86–9.

12. Jilaihawi H, Asgar A, Bonan R. Good outcome and valve function despite Medtronic-corevalve underexpansion. Catheter Cardiovasc Interv 2010;76:1022–5.

13. Sun W, Li K, Sirois E. Simulated elliptical bioprosthetic valve deformation: implications for asymmetric transcatheter valve deployment. J Biomech 2010;43:3085–90.

14. Haensig M, Lehmkuhl L, Rastan AJ, et al. Aortic valve calcium scoring is a predictor of significant paravalvular aortic insufficiency in transapical-aortic valve implantation. Eur J Cardiothorac Surg 2012;41:1234–40, discussion 1240–1.

15. Koos R, Mahnken AH, Dohmen G, et al. Association of aortic valve calcification severity with the degree of aortic regurgitation after transcatheter aortic valve implantation. Int J Cardiol 2011;150:142–5.

16. John D, Buellesfeld L, Yuecel S, et al. Correlation of device landing zone calcification and acute procedural success in patients undergoing transcatheter aortic valve implantations with the self-expanding CoreValve prosthesis. J Am Coll Cardiol Intv 2010;3:233–43.

KEY WORDS Lotus, multidetector computed tomography, transcatheter aortic valve replacement, transcatheter prosthesis geometry

Chapter 4: Comparative Safety and Efficacy of Current Generation Self---expanding and New Generation Mechanically---expanding TAVR Prostheses

Monash University

Declaration for Thesis Chapter 4

Comparison of Self---Expanding and Mechanically Expanded Transcatheter Aortic Valve Prostheses

Declaration by candidate

In the case of Chapter 4, the nature and extent of my contribution to the work was the following:

Nature of contribution	Extent of contribution (%)
Review of existing literature, planning study protocol, collection and interpretation of data writing manuscript, creation of figures, editing manuscript	73%

The following co---authors contributed to the work.

Name	Nature of contribution	Extent of contribution (%)
Dr Andrew Talman	Collection and Interpretation of data, writing and editing manuscript	10%
Prof James Cameron	Planning study protocol, interpretation of data, writing and editing manuscript	5%
Dr Siobhan Lockwood	Interpretation of data and editing manuscript	2%
Prof Ian Meredith	Planning study protocol, interpretation of data, writing and editing manuscript	10%

The undersigned hereby certify that the above declaration correctly reflects the nature and extent of the candidate's and co---authors' contributions to this work.

Candidate's Signature	[redacted]	**Date** 12/04/2016

Main Supervisor's Signature	[redacted]	**Date** 12/04/2016

Preface

The previous chapters have highlighted the complex anatomy of the aortoventricular interface and how this anatomy is modified by placement of the Lotus Valve System. Having proven that the Lotus device affects the native aortoventricular interface geometry differently from that reported with contemporary self---expanding devices, the following work identified the potential effects of these differences on procedural aspects, safety and efficacy.

The following work, published in JACC Cardiovascular Interventions, was the first study to compare the novel Lotus device with the self---expanding CoreValve device in the clinical setting. All clinical events were independently adjudicated, outcomes reported in accordance with published VARC2 criteria and all echocardiographic studies core laboratory adjudicated.

Such studies are imperative in assuring that device iterations and design features are associated with a net clinical safety and efficacy benefit which is not offset by increased procedural complexity or new excess adverse events.

JACC: CARDIOVASCULAR INTERVENTIONS
VOL. 8, NO. 7, 2015

ISSN 1936-8798/$36.00
PUBLISHED BY ELSEVIER INC.
http://dx.doi.org/10.1016/j.jcin.2015.03.014

STRUCTURAL

Comparison of Self-Expanding and Mechanically Expanded Transcatheter Aortic Valve Prostheses

Robert P. Gooley, MD,*y Andrew H. Talman, MD,*y James D. Cameron, MD,*y Siobhan M. Lockwood, MD,*y Ian T. Meredith, AM, MD*y

ABSTRACT

OBJECTIVES The aim of this study was to determine whether transcatheter aortic valve replacement (TAVR) with the mechanically expanded Lotus valve (Boston Scientific, Natick Massachusetts) offers potential benefits over treatment with the self-expanding CoreValve (Medtronic, Minneapolis, Minnesota).

BACKGROUND New-generation transcatheter aortic valve systems are emerging in clinical trials and practice with design features aimed at improving safety and efficacy. To date, these devices have not been compared systematically with current-generation devices.

METHODS A total of 100 patients (83.4 ± 4.8 years of age, 44% male, Society of Thoracic Surgeons Predicted Risk of Mortality score of 5.5 ± 2.4) were assessed. Fifty consecutive patients undergoing a Lotus transcatheter aortic valve replacement were enrolled and compared with 50 matched patients treated with a CoreValve. An independent core laboratory reviewed all echocardiographic data, and an independent clinical events committee adjudicated all events.

RESULTS Valve Academic Research Consortium 2–defined device success was 84% and 64% in the Lotus and CoreValve cohorts, respectively (p ¼ 0.02). This difference was driven by lower rates of moderate or greater aortic regurgitation (4% vs. 16.7%, respectively; p ¼ 0.04) and higher rates of successfully implanting a single device in the correct anatomic position (100% vs. 86%, respectively; p ¼ 0.06). Cardiovascular mortality rate (0% vs. 4%, respectively; p ¼ 0.32), major stroke rate (4% vs. 2%, respectively; p ¼ 0.56), and permanent pacemaker insertion rate (28% vs. 18%, respectively; p ¼ 0.23) were not different at 30 days in the Lotus and CoreValve cohorts.

CONCLUSIONS In this matched comparison of high surgical risk patients undergoing transcatheter aortic valve replacement, the use of the Lotus device was associated with higher rates of Valve Academic Research Consortium 2–defined device success compared with the CoreValve. This was driven by higher rates of correct anatomic positioning and lower incidences of moderate paraprosthetic regurgitation. The clinical significance of these differences needs to be tested in a large randomized, controlled trial. (J Am Coll Cardiol Intv 2015;8:962–71) © 2015 by the American College of Cardiology Foundation.

From *MonashHeart, Monash Health, Clayton, Victoria, Australia; and the yMonash Cardiovascular Research Centre, Monash University, Clayton, Victoria, Australia. Dr. Gooley, Dr. Lockwood, and Prof. Meredith receive modest consulting fees from Boston Scientific. Prof. Meredith serves on the Strategic Advisory Boards of Boston Scientific and Medtronic. Dr. Gooley receives a research scholarship from the National Health and Medical Research Council of Australia. All other authors have reported that they have no relationships relevant to the contents of this paper to disclose.

Manuscript received February 23, 2015; revised manuscript received March 20, 2015, accepted March 26, 2015.

Transcatheter aortic valve replacement (TAVR) has proved to be a safe and effective treatment for severe aortic stenosis in appropriately selected high and extremely high surgical risk patients (1,2). Since its inception in 2002 (3), TAVR has gained wide acceptance and clinical approval in many countries on the basis of a rapidly growing body of evidence. As a result, adoption of the technol- ogy and implant rates have grown nearly exponen- tially (4,5).

Most global TAVR experience has been obtained with either the Edwards SAPIEN or SAPIEN XT (Edwards Lifesciences, Irvine, California) or the Medtronic CoreValve device, (Minneapolis, Minnesota); however, a growing number of next-generation prostheses are now entering clinical trials and routine practice (6–9). Most of these devices incorporate novel features designed to reduce the modest yet impor- tant complications identified with current-generation devices. Data supporting enhanced safety and efficacy of new-generation devices, however, are modest and derived from single-arm studies.

The CoreValve Revalving System (Medtronic) is a self-expanding device fashioned from nitinol wire. The distinctive frame has a flared inflow portion to anchor in the native annulus, a constrained midsegment to avoid coronary obstruction, and a flared outflow portion to improve coaxial alignment to the aortic flow plane. In a U.S. pivotal trial, the CoreValve was found to have a significantly higher survival rate at 1 year than surgical valve replacement in a high-risk cohort (10). These results mirror favorable safety and efficacy data from large single-center (11,12), national (13–15), and multinational (16) registries.

The Lotus device (Boston Scientific, Natick, Massachusetts) is a new TAVR device that uses a unique mechanical expansion mechanism. It is made of a single braided nitinol wire and 3 bovine pericardial leaflets. The outer surface of the lower half of the frame is covered with an adaptive seal, essentially a polymer membrane that concertinas as the device is expanded and, in doing so, occupies any small residual interstices, sealing the frame against the native aortoventricular interface (8,17). This has been reported to reduce the rate of paraprosthetic aortic regurgitation (PAR). The device is fully repositionable and resheathable, even in the completely expanded position, allowing for fine control and the potential for removal should the device position or size be deemed suboptimal. The Lotus device was studied in the REPRISE I (Repositionable Percutaneous Replacement of Stenotic Aortic Valve Through Implantation of Lotus™ Valve System) (18), the REPRISE II (Repositionable Percutaneous Replacement of Stenotic Aortic Valve Through Implantation of Lotus™ Valve System—Evaluation of Safety and Performance) (19), and REPRISE II Extension single-arm trials.

Although there has been an adoption of new devices such as the Lotus at some cen- ters, to date, there have been no systematic head-to-head comparisons, with indepen- dent core laboratory assessments, of devices to accurately determine their relative safety and efficacy.

ABBREVIATIONS AND ACRONYMS

EOA = effective orifice area

MDCT = multidetector computed tomography

PAR = paraprosthetic aortic regurgitation

TAVR = transcatheter aortic valve replacement

TTE = transthoracic echocardiography

VARC2 = Valve Academic Research Consortium 2

METHODS

STUDY POPULATION. A total of 100 patients (mean age, 83.4 ± 4.8 years, 44% male) with symptomatic severe aortic stenosis were included in this study. Fifty consecutive and prospectively enrolled patients receiving a Lotus transcatheter device were compared with 50 matched patients who had undergone TAVR with the CoreValve device during the same period.

All patients were treated at a single Australian center. All patients were deemed to be at high or extremely high surgical risk because of an increased Society of Thoracic Surgeons Predicted Risk of Mortality score (higher than 8) and/or the collective opinion of the institution's Heart Team after a comprehensive history, examination, and frailty assessment (dominant hand-grip strength, 5-m gait speed, and serum albumin). Patients were eligible for inclusion if they had severe aortic stenosis based on echocardiographic criteria (mean transaortic gradient $40 mm Hg or aortic velocity $4 m/s and an aortic valve area #1 cm^2 or indexed aortic valve area #0.7 cm^2/m^2) and reported symptoms attributable to severe aortic stenosis (Table 1).

All patients were assessed in a systematic and standardized manner beginning with their attendance and clinical evaluation at our Structural Heart Disease Clinic. All patients underwent multidetector computed tomography (MDCT), transthoracic echocardiography (TTE), invasive angiography, and right heart catheterization before inclusion. Only patients who had MDCT annular sizing that allowed for treatment with either device (according to the respective instructions for use) and were treated via the femoral access route were considered suitable for the study. Patients were matched on age, sex, Society of Thoracic Surgeons score, and frailty indexes.

PRE-PROCEDURAL MDCT ASSESSMENT. All patients underwent prospectively electrocardiography-gated,

JACC: CARDIOVASCULAR INTERVENTIONS VOL. 8, NO. 7, 2015
JUNE 2015:962–71

TABLE 1 Inclusion and Exclusion Criteria

Inclusion criteria
1. Severe aortic stenosis
Mean aortic gradient $40 mm Hg or aortic velocity $4 m/s
AVA #1 cm^2 or indexed AVA #0.7 cm^2/m^2
2. Symptoms consistent with aortic stenosis
NYHA functional class II–IV dyspnea
Exertional angina
Exertional syncope or pre-syncope
3. High or extreme surgical risk
STS PROM $8 or heart team agreement that patient is at high surgical risk
4. Suitable aortic root anatomy for placement of either a Lotus* or CoreValve† prosthesis
MDCT-derived annular dimension $19 mm and #27 mm
5. Suitable peripheral vasculature for passage of an 18-/20-F sheath
Exclusion criteria
1. Inability to consent

*Boston Scientific, Natick, Massachusetts. †Medtronic, Minneapolis, Minnesota.
AVA ¼ aortic valve area; NYHA ¼ New York Heart Association; STS PROM ¼ Society of Thoracic Surgeons Predicted Risk of Mortality; MDCT ¼ multidetector computed tomography.

320-MDCT imaging of the aortic root at baseline. All scans were performed on a Toshiba Aquilion One 320-detector row scanner (Toshiba Medical Systems, Otawara, Japan). No heart rate control was used. Collimation was individualized to achieve a z-axis that encompassed the entire aortic root. Slice thickness was 0.5 mm. Gantry rotation speed was 275 ms per rotation, tube voltage was 100 to 120 kV, and the tube current was individualized to body habitus. Intravenous contrast (Omnipaque 350, GE Healthcare, Little Chalfont, Buckinghamshire, United Kingdom) was administered via an 18-gauge antecubital vein as a 70-ml bolus followed by a 50-ml saline solution bolus at a rate of 6 ml/s. Systolic phase images (20) were acquired after manual triggering by monitoring for contrast den- sity in the descending aorta to ensure adequate contrast opacification.

All MDCT scans were analyzed by an experienced computed tomography cardiologist using the 3Mensio valve analysis program (3Mensio Medical Imaging, Bilthoven, the Netherlands). The annular plane was identified as the short axis through the nadir of each coronary cusp, and diameters, perimeter, and area were measured. The eccentricity was calculated using the eccentricity index (eccentricity index ¼ 1 − minimal diameter/maximal diameter). Further measurements were taken in the left ventricular outflow tract 4 mm below the annular plane, sinus of Val- salva, ascending aorta, and height of the coronary arteries.

Sizing of TAVR devices was guided by the 3-dimensional MDCT measurements and strictly conformed with the respective manufacturer's instructions for use. The degree of oversizing for each device was calculated based on annular plane perimeter (perimeter oversizing ¼ (device perimeter − annular perimeter)/annular perimeter × 100) and annular plane area (area oversizing ¼ (device area − annular area)/annular area × 100).

PRE-PROCEDURAL TTE ASSESSMENT. TTE was performed using an iE33 machine (Philips, Best, the Netherlands) before enrollment. All scans were assessed by an experienced echocardiologist with severity of aortic stenosis graded based on European Association of Echocardiography and American Society of Echocardiography joint guidelines (21). An independent echocardiography core laboratory subsequently reviewed these studies with these results used for study analysis.

PRE-PROCEDURAL INVASIVE ANGIOGRAPHIC ASSESSMENT. All patients underwent invasive coronary and peripheral angiography to confirm access site suitability and to identify significant coronary artery disease warranting treatment before TAVR. Treatment of concomitant coronary artery disease was at the discretion of the implanting cardiologist. Right heart catheterization was performed to exclude significant primary pulmonary hypertension and corroborate ultrasound-based hemodynamic measurements.

TREATMENT. All TAVR procedures were performed in the cardiac catheterization laboratory with patients under general anesthesia or conscious sedation. Three experienced TAVR cardiologists performed all procedures with 2 operators present at each procedure. The femoral artery was used for device access in all cases with an 18-F Cook sheath (Cook Medical, Bloomington, Indiana) used for all CoreValve procedures, whereas an 18-F Lotus Introducer (Boston Scientific) was used for 23-mm Lotus cases and 20-F Lotus Introducer for those receiving a 27-mm Lotus valve. The femoral access site was managed uniformly in all patients. The designated femoral access was routinely "pre-closed" with either a single Prostar or 2 Proglide devices (Abbott Vascular, Abbott Park, Illinois), and final access site closure was performed using a crossover balloon occlusion technique (22).

Balloon valvuloplasty was performed in all patients under rapid ventricular pacing to enable maximal balloon stability. Valvuloplasty balloons were sized so as to not exceed the minimal diameter of the left ventricular outflow tract.

Deployment of the respective devices was performed in strict accordance with manufacturer's guidelines and current best practices (8,16,17).

Aortic regurgitation was assessed by aortography after final deployment using 20 ml of iodinated contrast delivered at 20 ml/s and 800 psi by automated injector through a 5-F pigtail catheter positioned above the prosthesis leaflets. Moderate or greater aortic regurgitation, identified at the time of deployment by either imaging modality and/or haemodynamic assessment, was treated by post-dilation in the CoreValve cohort and repositioning in the Lotus cohort. Aortography was repeated after final device manipulation to reassess final degree of PAR and to exclude the need for further manipulation.

INDEPENDENT CORE LABORATORY ECHOCARDIOGRAPHIC ASSESSMENT. All patients had a TTE study performed on day 7 to 10 or on the day of discharge, if this occurred earlier, and again at 30 days after TAVR. The independent core laboratory assessed prosthesis function, degree, and location of aortic regurgitation, severity of mitral regurgitation, left ventricular function, and pulmonary artery pressure. Prosthetic regurgitation was assessed in accordance with Valve Academic Research Consortium 2 (VARC2) (23) recommendations.

CLINICAL REVIEW. A study investigator reviewed patients at the time of each echocardiogram, and a detailed history was taken and an examination performed. New York Heart Association functional class was determined on the basis of the patient's self-reporting of symptoms.

ENDPOINTS. The primary endpoint of the trial was VARC2-defined device success (23). This is a composite endpoint that includes the absence of procedural mortality, correct positioning of a single prosthesis in the correct anatomic position, and intended prosthesis function (no prosthesis-patient mismatch, mean aortic valve gradient <20 mm Hg, peak velocity <3 m/s, and no moderate or greater aortic regurgitation on TTE at time of discharge). Prosthesis function was determined by core laboratory assessment of the discharge echocardiogram.

Secondary endpoints were all-cause and cardiovascular mortality at 30 days, minor and major bleeding, minor and major vascular injury, new pacemaker insertion, and disabling and nondisabling stroke.

STATISTICAL ANALYSIS. Categorical variables were expressed as frequencies and percentages, whereas continuous variables were expressed as means and SDs. Categorical variables were compared using a chi-square test, whereas nonparametric continuous variables were compared using the Mann-Whitney or independent-sample *t* test. A 2-sided p value <0.05 was considered statistically significant. Statistical analysis was performed using IBM SPSS Statistics version 22.0 (IBM Corporation, Armonk, New York).

RESULTS

BASELINE CHARACTERISTICS. The baseline demographic and clinical characteristics are described in Table 2. In brief, there were no clinically significant differences between the 2 study populations other than a higher proportion of patients with NYHA functional class IV symptoms in the Lotus cohort and more patients with pre-existing atrial fibrillation in the CoreValve cohort. Baseline Society of Thoracic Surgeon scores, Charlson Comorbidity Index, and frailty index were similar.

Baseline echocardiographic parameters of aortic stenosis severity were not significantly different between the Lotus and CoreValve cohorts, with average mean gradients of 44.9 ± 12.9 mm Hg and 47.3 ± 12.5 mm Hg, respectively (p ¼ 0.34). There

TABLE 2 Baseline Characteristics

	Lotus* (n ¼ 50)	CoreValve† (n ¼ 50)	p Value
Age, yrs	84.0 ± 5.2	82.7 ± 4.5	0.19
Male	18 (36)	26 (52)	0.11
Height, cm	161.4 ± 10.0	163.8 ± 8.9	0.20
Weight, kg	72.9 ± 17.2	73.9 ± 14.6	0.75
Body mass index, kg/m^2	28.1 ± 6.6	27.5 ± 4.8	0.62
STS PROM, %	5.80 ± 2.40	5.21 ± 2.47	0.23
STS M&M	26.21 ± 7.44	23.97 ± 6.08	0.10
Charlson Comorbidity Index	2.7 ± 2.0	2.6 ± 1.4	0.65
Hand grip strength	16.6 ± 7.0	16.0 ± 6.3	0.73
5-m gait speed	9.9 ± 3.0	9.5 ± 2.9	0.55
Serum albumin	33.9 ± 5.6	32.1 ± 5.8	0.12
NYHA functional class			
II	7 (14)	13 (26)	
III	36 (72)	36 (72)	
IV	7 (14)	1 (2)	0.05
Creatinine, mmol/l	97.6 ± 57.3	103.2 ± 28.4	0.54
Type 2 diabetes mellitus	10 (20)	12 (24)	0.63
Existing coronary artery disease	29 (58)	33 (66)	0.41
Previous coronary bypass surgery	7 (14)	15 (30)	0.05
Peripheral vascular disease	3 (6)	6 (12)	0.30
Chronic pulmonary disease	14 (28)	16 (32)	0.66
Atrial fibrillation	5 (10)	14 (28)	0.02
Existing permanent pacemaker	5 (10)	7 (14)	0.54

Values are mean ± SD or n (%). *Boston Scientific, Natick, Massachusetts. †Medtronic, Minneapolis, Minnesota.

STS M&M ¼ Society of Thoracic Surgeons Morbidity and Mortality; other abbreviations as in Table 1.

JACC: CARDIOVASCULAR INTERVENTIONS VOL. 8, NO. 7, 2015
JUNE 2015:962–71

were no differences in the proportion of patients with mild, moderate, or severe aortic regurgitation at baseline. MDCT annular dimensions, whether diameter, perimeter, or perimeter-derived metrics, were well matched. The basal plane was slightly more eccentric among the CoreValve cohort (eccentricity index: 0.20 ± 0.06 vs. 0.23 ± 0.06, p ¼ 0.02). Left ventricular outflow tract, sinus dimensions, and height of the coronary arteries above the basal plane were similar. Full baseline anatomic dimensions are shown in Table 3.

PROCEDURAL DETAILS. Twenty-six patients (52%) in the Lotus cohort were treated with the smaller Lotus device (23 mm), whereas 22 patients (44%) in the CoreValve group received the smaller CoreValve prosthesis (26 mm) ($p < 0.001$). There was greater perimeter oversizing (3.6 ± 5.7% vs. 14.0 ± 6.2%, $p < 0.001$) and area oversizing (13.0 ± 12.3% vs. 36.6 ± 15.4%, $p < 0.001$) in the CoreValve cohort. All patients left the catheterization laboratory with a functioning TAVR prosthesis. There were no differences in procedure duration (Table 4).

The primary outcome measure of VARC2-defined device success was achieved in 84% of the Lotus cohort and 64% of the CoreValve cohort (p ¼ 0.02). The components of this outcome measure were the absence of procedural mortality (100% vs. 96%; p ¼ 0.15), correct positioning of a single prosthesis (100% vs. 86%; p ¼ 0.06), mean gradient across the prosthesis <20 mm Hg (96% vs. 100%; p ¼ 0.16), absence of prosthesis-patient mismatch (92% vs. 86%; p ¼ 0.68), and no more than mild aortic regurgitation (96% vs. 83.3%; p ¼ 0.04) in the Lotus and CoreValve cohorts, respectively (Figure 1).

All-cause death was 0% in the Lotus cohort and 4% in the CoreValve cohort at 7 days. At 7 days, 1 death in the CoreValve cohort was due to ischemic colitis after a partially deployed prosthesis was retrieved through the aorta, whereas the other death was due to progressive congestive cardiac failure in the setting of severe PAR that was refractory to post-dilation. There was 1 additional death in the Lotus cohort at 30 days due to a hemorrhagic stroke, and 1 additional death in the CoreValve cohort due to pneumonia and respiratory failure.

There was no significant difference in the rates of acute kidney injury, minor or major vascular injury, disabling or nondisabling stroke, or periprocedural myocardial infarction. The rate of new pacemaker insertion was greater in the Lotus cohort (28% vs. 18%), although not statistically different (p ¼ 0.23) (Figure 2).

CORE LABORATORY DISCHARGE ASSESSMENT. The mean transprosthetic gradients were 12.4 ± 4.2 mm Hg and 8.5 ± 2.9 mm Hg ($p < 0.001$) for the Lotus and CoreValve cohorts, respectively. The mean effective orifice areas (EOAs) were similar in both cohorts (1.6 ± 0.3 cm^2 vs. 1.7 ± 0.4 cm^2, p ¼ 0.07). There were no differences in the severity of mitral regurgita- tion, pulmonary artery pressure, or left ventricular function (Table 5).

Core laboratory–adjudicated PAR was mild in 14% and 56.2% ($p < 0.001$) and moderate in 4% and 16.7% (p ¼ 0.04) of the Lotus and CoreValve cohorts, respectively. Although 1 patient in the CoreValve cohort died of complications of severe

TABLE 3 Pre-procedural Echocardiographic and Computed Tomographic Imaging Assessment

	Lotus* (n ¼ 50)	CoreValve† (n ¼ 50)	p Value
Transthoracic echocardiography			
Mean gradient	44.9 ± 12.9	47.3 ± 12.5	0.34
AVA	0.70 ± 0.17	0.67 ± 0.16	0.35
AVA indexed	0.41 ± 0.10	0.39 ± 0.07	0.41
Dimensionless index	0.23 ± 0.05	0.22 ± 0.05	0.39
Pulmonary artery pressure	41.3 ± 11.4	39.1 ± 9.8	0.34
Left ventricular ejection fraction	56.4 ± 9.1	54.9 ± 9.2	0.51
Mitral regurgitation			
None/trivial	29 (58)	25 (50)	
Mild	14 (28)	25 (50)	
Moderate	7 (14)	0	0.01
Tricuspid regurgitation			
None/trivial	22 (44)	30 (60)	
Mild	23 (46)	17 (34)	
Moderate	5 (10)	2 (4)	
Moderate/severe	0	0	
Severe	0	1 (2)	0.22
Aortic regurgitation			
None/trivial	21 (42)	20 (40)	
Mild	23 (46)	28 (56)	
Moderate	6 (12)	2 (4)	0.28
Multidetector computed tomography			
Basal plane			
Minimal diameter	21.2 ± 1.9	21.0 ± 2.0	0.68
Maximal diameter	26.5 ± 2.1	27.3 ± 2.2	0.09
Eccentricity index	0.20 ± 0.06	0.23 ± 0.06	0.02
Perimeter	75.6 ± 5.5	76.5 ± 5.8	0.42
Area	435.7 ± 63.4	447.1 ± 68.9	0.40
Left ventricular outflow tract			
Minimal diameter	19.2 ± 2.6	19.5 ± 2.4	0.59
Maximal diameter	27.4 ± 2.7	27.7 ± 2.8	0.54
Eccentricity index	0.30 ± 0.09	0.30 ± 0.07	0.99
Perimeter	74.6 ± 6.8	75.8 ± 6.8	0.36
Area	405.8 ± 80.5	424.9 ± 77.3	0.23
Sinus of Valsalva			
Area	776.8 ± 122.2	831.3 ± 136.2	0.04

Values are mean ± SD or n (%). *Boston Scientific, Natick, Massachusetts. †Medtronic, Minneapolis, Minnesota.
AVA ¼ aortic valve area.

PAR before the discharge TTE time point, there were no further cases of severe PAR in those patients alive at 7 days.

CORE LABORATORY 30-DAY ASSESSMENT. There was no deterioration in valve function as assessed by TTE at 30 days by mean transprosthetic gradient or EOA. The mean transprosthetic gradient remained significantly higher in the Lotus cohort than the CoreValve cohort (12.6 ± 6.5 mm Hg and 8.2 ± 2.6 mm Hg, respectively; $p < 0.001$), with no difference in the prosthesis EOA (1.7 ± 0.4 cm^2 vs. 1.8 ± 0.4 cm^2, respectively; p ¼ 0.17).

Moderate PAR occurred in 0% and 10.6% (p ¼ 0.02) of patients in the Lotus and CoreValve cohorts, respectively, with no cases of severe PAR at 30 days. The percentage of patients with mild AR was similar to that at discharge: 14.3% and 66% ($p < 0.001$), respectively (Table 5).

FUNCTIONAL ASSESSMENT. There was a significant improvement in New York Heart Association score in both cohorts with 79.2% of patients in the Lotus group and 82.9% in the CoreValve group, improving by 1 class or more (Figure 3).

DISCUSSION

There is a substantial body of evidence supporting the efficacy and safety of TAVR as an alternate treatment to surgical valve replacement in high-risk patients (1,10) and its superiority to medical therapy in patients denied surgery due to extreme risk (2). Despite improvements in patient selection, the utility of 3-dimensional computed tomography image-based sizing algorithms and deployment techniques, a number of limitations remain with the current technologies. These include vascular access complications (24,25), need for permanent pacemaker after implantation (26,27), PAR (28), and stroke (29,30). Although second-generation devices, designed to address some of these limitations, are emerging in both clinical trials and clinical practice, the evidence supporting their safety and efficacy is limited. This study was designed to systematically compare a widely accepted and well-studied current-generation device, the CoreValve, with an emerging new- generation device, the Lotus valve.

In this nonrandomized, single-center study, we observed that both the Lotus and CoreValve devices were associated with high rates of procedural suc- cess, although the VARC2-defined primary compos- ite outcome of device success was higher in the Lotus cohort. Device success was 84% and 64% in the Lotus and CoreValve arms, respectively, driven by higher rates of correct positioning of a single device and lower rates of moderate PAR in the Lotus group. Importantly, the rates of procedural mortality and transprosthesis gradient greater than 20 mm Hg and prosthesis patient mismatch were not different.

It could be argued that the difference we observed was due to a lower than expected VARC2 device success rate in the CoreValve group; however, the rate was comparable to that observed in the CoreValve arm of the CHOICE trial (Comparison of balloon-expandable vs. self-expandable valves in patients undergoing transcatheter aortic valve replacement) —77.5% (31)—if the same VARC definition is used. The CHOICE trial used the first VARC

TABLE 4 Procedural Characteristics

	Lotus* (n ¼ 50)	CoreValve† (n ¼ 50)	p Value
Device size			<0.001
Small (23-mm Lotus, 26-mm CoreValve)	26 (52)	22 (44)	
Large (27-mm Lotus, 29-mm CoreValve)	24 (48)	28 (56)	
Sheath size, Fr			<0.001
18	26 (52)	50 (100)	
20	24 (48)	0 (0)	
Prosthesis oversizing			
Perimeter	3.6 ± 5.7	13.0 ± 12.3	<0.001
Area	14.0 ± 6.2	36.6 ± 15.4	<0.001
No. of devices used	1.12 ± 0.32	1.14 ± 0.40	0.79
Post-dilation	0 (0)	13 (26)	<0.001
Procedure duration, min	118.0 ± 39.2	114.2 ± 35.8	0.62

*Boston Scientific, Natick, Massachusetts. †Medtronic, Minneapolis, Minnesota.

FIGURE 1 Device Success and Composites

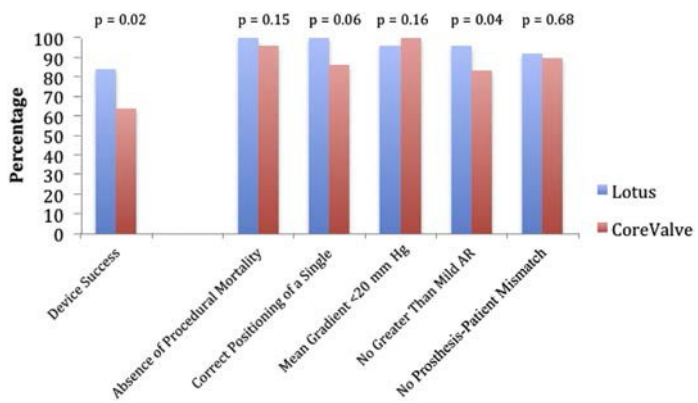

Primary outcome measure of Valve Academic Research Consortium 2–defined device success and its composites. AR ¼ aortic regurgitation.

JACC: CARDIOVASCULAR INTERVENTIONS VOL. 8, NO. 7, 2015
JUNE 2015:962–71

FIGURE 2 Secondary Outcome Measures

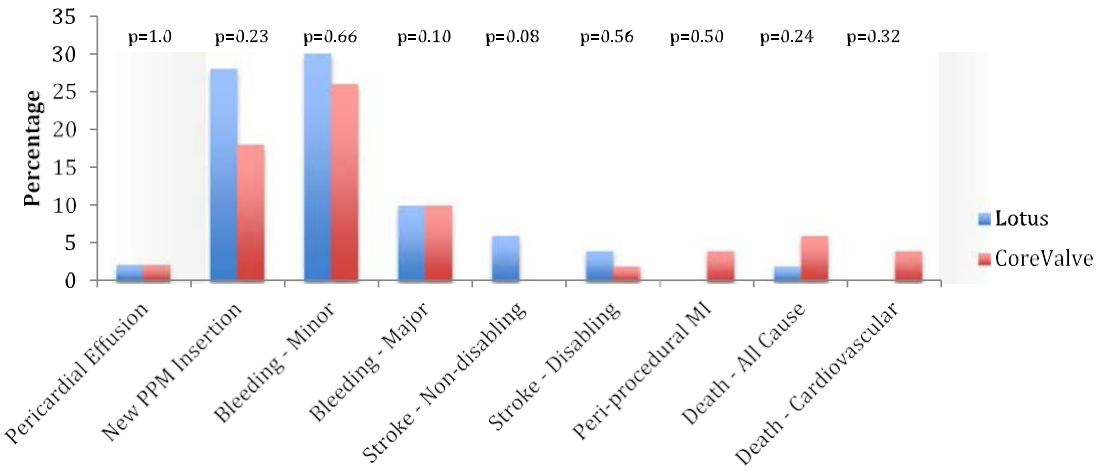

Comparison of Valve Academic Research Consortium 2 defined outcome measures between the valve types. MI ¼ myocardial infarction; PPM ¼ permanent pacemaker.

definition of device success, which, unlike VARC2, does not include prosthesis-patient mismatch in the composite endpoint. If the prosthesis-patient mismatch is not included in the composite, the rates of device success in our study are 92% and 74% in the Lotus and CoreValve cohorts, respectively. Moreover, the rate of moderate PAR observed in this study was comparable, if not lower, than that observed in

TABLE 5 Core Laboratory–Adjudicated Echocardiographic Assessment

	Discharge			1 Month		
	Lotus* (n ¼ 50)	CoreValve† (n ¼ 48)	p Value	Lotus (n ¼ 49)	CoreValve (n ¼ 47)	p Value
Paraprosthetic aortic regurgitation						
None/trivial	41 (82)	13 (27.1)	<0.001	42 (85.7)	11 (23.4)	<0.001
Mild	7 (14)	27 (56.2)		7 (14.3)	31 (66)	
Moderate	2 (4)	8 (16.7)	<0.001	0	5 (10.6)	<0.001
Moderate/severe	0	0		0	0	
Severe	0	0	0.04	0	0	0.02
Valvular aortic regurgitation						
None/trivial	46 (92)	44 (91.7)	0.95	44 (89.8)	45 (95.7)	0.26
Mild	3 (6)	4 (8.3)	0.65	5 (10.2)	2 (4.3)	0.26
Moderate	1 (2)	0	0.33	0	0	
Moderate/severe	0	0		0	0	
Severe	0	0		0	0	
Mean transprosthetic gradient	12.4 ± 4.2	8.5 ± 2.9	<0.001	12.6 ± 6.5	8.2 ± 2.6	<0.001
Effective orifice area	1.6 ± 0.3	1.7 ± 0.4	0.07	1.7 ± 0.4	1.8 ± 0.4	0.17
Pulmonary artery pressure	41.4 ± 10.8	34.8 ± 8.9	0.03	40.4 ± 10.1	37.0 ± 8.8	0.11
Left ventricular ejection fraction	55.3 ± 10.1	54.5 ± 8.7	0.70	56.0 ± 8.9	55.3 ± 6.0	0.68
Mitral regurgitation						
None/trivial	25 (50)	16 (33.3)		27 (55.1)	20 (42.6)	
Mild	22 (44)	29 (60.4)		18 (36.7)	22 (46.8)	
Moderate	3 (6)	3 (6.3)		4 (8.2)	5 (10.6)	
Moderate/severe	0	0		0	0	
Severe	0	0	0.24	0	0	0.68

Values are n (%) or mean ± SD. *Boston Scientific, Natick, Massachusetts. †Medtronic, Minneapolis, Minnesota.

other core laboratory–adjudicated trials (10,16). The rate of post-dilation in the CoreValve cohort (26%) was also comparable to the rate reported in the CoreValve United States Investigational Device Exemption trial (20.3%) (10). Importantly, the apparent difference in device success in the current study was not reflected in differences in mortality nor clinical efficacy to 30 days.

Significant PAR after TAVR deployment has been shown to correlate with increased morbidity and mortality (32,33). Factors contributing to regurgitation include baseline annular eccentricity (34), the depth of device implantation (35), and the degree of prosthesis oversizing (36), whereas the degree of calcification has been an inconsistent predictor in various studies (37–39). In this study, the native basal plane was slightly more eccentric in the CoreValve cohort, although whether this contributed to the device success differences is unclear. The degree of prosthesis oversizing was greater in the CoreValve cohort, although this reflected differences in the manufacturer sizing recommendations for the 2 devices.

The novel features of the Lotus valve may potentially explain the differences observed in de- vice success. The Lotus is totally repositionable, even when fully expanded in the final position by virtue of its deployment and coupling mechanism. This enables detailed interrogation of the device function, degree of PAR, and device stability before uncoupling and release. In addition, the presence of an adaptive seal around the outer aspect of the lower valve frame appears to reduce PAR by occu- pying residual interstices between the frame and native annulus (17–19). Placement of the CoreValve, on the other hand, relies on accurate initial posi- tioning and oversizing of the device to increase device/annular interaction.

A nonsignificant reduction in the degree of PAR was noted between the discharge and 30-day time points. In the CoreValve cohort, 3 patients with moderate PAR at discharge had only mild PAR at 30 days. Similarly, 2 patients in the Lotus cohort had a reduction from moderate to mild PAR. Detailed interpretation of the mechanism of this improvement is difficult given the small numbers but may represent further device expansion, occu- pation of residual interstices by fibrous tissue, or sampling error due to different echocardiographic windows.

Secondary procedural outcome measures including vascular injury, stroke, myocardial infarction, and mortality (all-cause and cardiovascular) were not different between the cohorts and consistent with

FIGURE 3 Change in New York Heart Association Functional Class

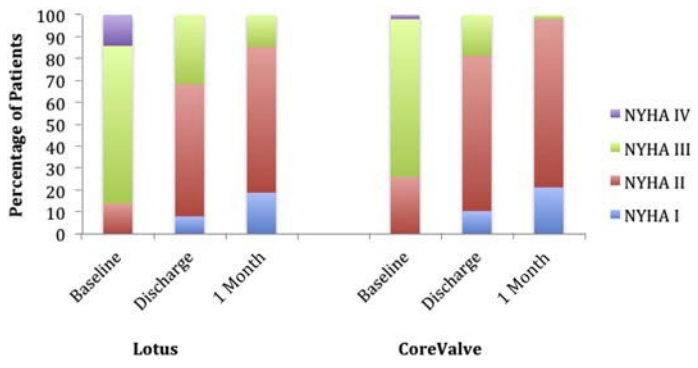

New York Heart Association (NYHA) functional class change at discharge and at 1 month.

previously reported rates (10,19). There was a numerically but not statistically higher rate of permanent pacemaker insertion after Lotus device placement. This study was not powered to identify the cause of increased pacing; however, in the REPRISE II trials, pacemaker insertion was found to correlate with the degree of prosthesis oversizing (40), which was greater than anticipated because only 2 valve sizes were available.

Core laboratory assessment of the echocardiographic studies at discharge and 30 days showed that the prosthesis EOA was similar in both cohorts but that the mean transprosthesis gradient was greater in the Lotus cohort. Despite well-matched baseline annular dimensions, a significantly larger number of small prostheses were inserted in the Lotus cohort due to manufacturer sizing recommendations of less oversizing with this device. It is possible that the smaller average device size contributed to a higher mean gradient.

The results of this well-matched study suggest that placement of either the CoreValve device or Lotus device, in appropriately selected high surgical risk patients, results in acceptable procedural outcomes with good safety and efficacy profiles. The higher rate of VARC2-defined device success observed in the Lotus cohort, driven by higher rates of correct positioning and less PAR, supports the efficacy of the device's novel design features.

STUDY LIMITATIONS. This was a small, single-center, nonrandomized study not powered for major clinical endpoints such as death, stroke, and MI. Although every attempt was made to match patients, it is possible that unrecognized differences between the study cohorts may have contributed to the

JACC: CARDIOVASCULAR INTERVENTIONS VOL. 8, NO. 7, 2015
JUNE 2015:962–71

results. The results should be viewed as hypothesis generating.

CONCLUSIONS

In this well-matched, single-center, nonrandomized study, both the CoreValve and Lotus devices demonstrated comparable procedural safety and efficacy results. Independent core laboratory assessment of all echocardiograms suggested greater device success with the second-generation Lotus valve driven by higher rates of correct anatomic positioning of a single prosthesis and lower rates of moderate paraprosthetic regurgitation. The clinical significance of these differences will need to be tested in larger randomized trials such as the REPRISE III trial.

REPRINT REQUESTS AND CORRESPONDENCE: Dr. Ian T. Meredith, Monash Heart, Monash Health, 246 Clayton Road, Clayton, Victoria, 3168 Australia. [redacted]

PERSPECTIVES

WHAT IS KNOWN? TAVR is an accepted treatment modality for appropriately selected patients with symptomatic severe aortic stenosis, yet modest complication rates remain.

WHAT IS NEW? New-generation TAVR devices, with new design features, are entering clinical practice with potential safety and efficacy advantages over current devices. We have shown that the mechanically expanded Lotus device results in higher rates of device success than the self-expanding CoreValve device in a matched cohort.

WHAT IS NEXT? The clinical significance of these differences will need to be tested in a larger randomized trial such as the currently recruiting REPRISE III study.

REFERENCES

1. Smith CR, Leon MB, Mack MJ, et al. Transcatheter versus surgical aortic-valve replacement in high-risk patients. N Engl J Med 2011;364:2187–98.

2. Makkar RR, Fontana GP, Jilaihawi H, et al. Transcatheter aortic-valve replacement for inoperable severe aortic stenosis. N Engl J Med 2012;366:1696–704.

3. Cribier A, Eltchaninoff H, Bash A, et al. Percutaneous transcatheter implantation of an aortic valve prosthesis for calcific aortic stenosis: first human case description. Circulation 2002;106:3006–8.

4. Osnabrugge RL, Mylotte D, Head SJ, et al. Aortic stenosis in the elderly: disease prevalence and number of candidates for transcatheter aortic valve replacement: a meta-analysis and modeling study. J Am Coll Cardiol 2013;62:1002–12.

5. Mylotte D, Osnabrugge RL, Windecker S, et al. Transcatheter aortic valve replacement in Europe: adoption trends and factors influencing device utilization. J Am Coll Cardiol 2013;62:210–9.

6. Binder RK, Rodes-Cabau J, Wood DA, et al. Transcatheter aortic valve replacement with the SAPIEN 3: a new balloon-expandable transcatheter heart valve. J Am Coll Cardiol Intv 2013;6:293–300.

7. Freeman M, Rodé3s-Cabau J, Urena M, et al. First-in-man transfemoral transcatheter aortic valve replacement with the 29 mm Edwards SAPIEN XT valve. Catheter Cardiovasc Interv 2013;82:664–70.

8. Gooley R, Lockwood S, Antonis P, Meredith IT. The SADRA Lotus Valve System: a fully repositionable, retrievable prosthesis. Minerva Cardioangiol 2013;61:45–52.

9. Manoharan G, Spence MS, Rodes-Cabau J, Webb JG. St Jude Medical Portico valve. EuroIntervention 2012;8 Suppl Q:Q97–101.

10. Adams DH, Popma JJ, Reardon MJ, et al. Transcatheter aortic-valve replacement with a self-expanding prosthesis. N Engl J Med 2014;370:1790–8.

11. Godino C, Maisano F, Montorfano M, et al. Outcomes after transcatheter aortic valve implantation with both Edwards-SAPIEN and CoreValve devices in a single center: the Milan experience. J Am Coll Cardiol Intv 2010;3:1110–21.

12. Grube E, Buellesfeld L, Mueller R, et al. Progress and current status of percutaneous aortic valve replacement: results of three device generations of the CoreValve Revalving system. Circ Cardiovasc Interv 2008;1:167–75.

13. Meredith IT, Walton A, Walters DL, et al. Midterm outcomes in patients following transcatheter aortic valve implantation in the CoreValve Australia and New Zealand study. Heart Lung Circ 2015;24:281–90.

14. Barbanti M, Ussia GP, Cannata S, Giarratana A, Sgroi C, Tamburino C. 3-year outcomes of self-expanding CoreValve prosthesis—The Italian Registry. Ann Cardiothorac Surg 2012;1:182–4.

15. Hamm CW, Mollmann H, Holzhey D, et al. The German Aortic Valve Registry (GARY): in-hospital outcome. Eur Heart J 2014;35:1588–98.

16. Linke A, Wenaweser P, Gerckens U, et al. Treatment of aortic stenosis with a self-expanding transcatheter valve: the International Multi-centre ADVANCE Study. Eur Heart J 2014;35:281–90.

17. Meredith IT, Hood KL, Haratani N, Allocco DJ, Dawkins KD. Boston Scientific Lotus valve. EuroIntervention 2012;8 Suppl Q:Q70–4.

18. Meredith IT, Worthley SG, Whitbourn RJ, et al. Transfemoral aortic valve replacement with the repositionable Lotus Valve System in high surgical risk patients: the REPRISE I study. EuroIntervention 2014;9:1264–70.

19. Meredith Am IT, Walters DL, Dumonteil N, et al. Transcatheter Aortic Valve Replacement for Severe Symptomatic Aortic Stenosis Using a Repositionable Valve System: 30-Day Primary Endpoint Results From the REPRISE II Study. J Am Coll of Cardiol 2014;64:1339–48.

20. Bloomfield GS, Gillam LD, Hahn RT, et al. A practical guide to multimodality imaging of transcatheter aortic valve replacement. J Am Coll Cardiol Img 2012;5:441–55.

21. Baumgartner H, Hung J, Bermejo J, et al. Echocardiographic assessment of valve stenosis: EAE/ASE recommendations for clinical practice. Eur J Echocardiogr 2009;10:1–25.

22. Genereux P, Kodali S, Leon MB, et al. Clinical outcomes using a new crossover balloon occlusion technique for percutaneous closure after transfemoral aortic valve implantation. J Am Coll Cardiol Intv 2011;4:861–7.

23. Kappetein AP, Head SJ, Genereux P, et al. Updated standardized endpoint definitions for transcatheter aortic valve implantation: the Valve Academic Research Consortium-2 consensus document. J Thorac Cardiovasc Surg 2013;145:6–23.

24. Tchetche D, Dumonteil N, Sauguet A, et al. Thirty-day outcome and vascular complications after transarterial aortic valve implantation using both Edwards Sapien and Medtronic CoreValve bioprostheses in a mixed population. EuroIntervention 2010;5:659–65.

25. Van Mieghem NM, Nuis RJ, Piazza N, et al. Vascular complications with transcatheter aortic

valve implantation using the 18 Fr Medtronic CoreValve System: the Rotterdam experience. EuroIntervention 2010;5:673–9.

26. Fraccaro C, Buja G, Tarantini G, et al. Incidence, predictors, and outcome of conduction disorders after transcatheter self-expandable aortic valve implantation. Am J Cardiol 2011;107:747–54.

27. van der Boon RM, Nuis RJ, Van Mieghem NM, et al. New conduction abnormalities after TAVI—frequency and causes. Nat Rev Cardiol 2012;9:454–63.

28. Sherif MA, Abdel-Wahab M, Stocker B, et al. Anatomic and procedural predictors of paravalvular aortic regurgitation after implantation of the Medtronic CoreValve bioprosthesis. J Am Coll Cardiol 2010;56:1623–9.

29. Nuis RJ, Van Mieghem NM, Schultz CJ, et al. Frequency and causes of stroke during or after transcatheter aortic valve implantation. Am J Cardiol 2012;109:1637–43.

30. Eggebrecht H, Schmermund A, Voigtlander T, Kahlert P, Erbel R, Mehta RH. Risk of stroke after transcatheter aortic valve implantation (TAVI): a meta-analysis of 10,037 published pa- tients. EuroIntervention 2012;8:129–38.

31. Abdel-Wahab M, Mehilli J, Frerker C, et al. Comparison of balloon-expandable vs self-expandable valves in patients undergoing transcatheter aortic valve replacement: the CHOICE randomized clinical trial. JAMA 2014;311:1503–14.

32. Sinning JM, Hammerstingl C, Vasa-Nicotera M, et al. Aortic regurgitation index defines severity of peri-prosthetic regurgitation and predicts outcome in patients after transcatheter aortic valve implantation. J Am Coll Cardiol 2012;59:1134–41.

33. Athappan G, Patvardhan E, Tuzcu EM, et al. Incidence, predictors, and outcomes of aortic regurgitation after transcatheter aortic valve replacement: meta-analysis and systematic review of literature. J Am Coll Cardiol 2013;61:1585–95.

34. Wong DT, Bertaso AG, Liew GY, et al. Relationship of aortic annular eccentricity and paravalvular regurgitation post transcatheter aortic valve implantation with CoreValve. J Invasive Cardiol 2013;25:190–5.

35. Takagi K, Latib A, Al-Lamee R, et al. Predictors of moderate-to-severe paravalvular aortic regurgitation immediately after CoreValve implantation and the impact of postdilatation. Catheter Cardiovasc Interv 2011;78:432–43.

36. Detaint D, Lepage L, Himbert D, et al. Determinants of significant paravalvular regurgitation after transcatheter aortic valve: implantation impact of device and annulus discongruence. J Am Coll Cardiovasc Intv 2009;2:821–7.

37. Colli A, D'Amico R, Kempfert J, Borger MA, Mohr FW, Walther T. Transesophageal echocardiographic scoring for transcatheter aortic valve implantation: impact of aortic cusp calcification on postoperative aortic regurgitation. J Thorac Cardiovasc Surg 2011;142:1229–35.

38. Ewe SH, Ng AC, Schuijf JD, et al. Location and severity of aortic valve calcium and implications for aortic regurgitation after transcatheter aortic valve implantation. Am J Cardiol 2011;108:1470–7.

39. Staubach S, Franke J, Gerckens U, et al. Impact of aortic valve calcification on the outcome of transcatheter aortic valve implantation: results from the prospective multicenter German TAVI registry. Catheter Cardiovasc Interv 2013;81:348–55.

40. Dumonteil N. Need for permanent pacemaker following implantation of the repositionable second-generation LOTUS device for transcatheter aortic valve replacement: results from the pivotal REPRISE II trial. J Am Coll Cardiol 2013;62:B39.

KEY WORDS aortic stenosis, CoreValve, Lotus, transcatheter aortic valve replacement

Chapter 5: Multi---detector Computed Tomographic Assessment of Leaflet Thickness in a Novel Mechanically Expanded TAVR Prosthesis

Monash University

Declaration for Thesis Chapter 5

4---Dimensional Multidetector Computed Tomographic Assessment of Leaflet Thickening and Motion in Patients Treated with a Mechanically Expanded TAVR Prosthesis

Declaration by candidate

In the case of Chapter 5, the nature and extent of my contribution to the work was the following:

Nature of contribution	**Extent of contribution (%)**
Review of existing literature, planning study protocol, collection and interpretation of data writing manuscript, creation of figures, editing manuscript	80%

The following co---authors contributed to the work.

Name	**Nature of contribution**	**Extent of contribution (%)**
Prof Ian Meredith	Planning study protocol, interpretation of data, writing and editing manuscript	10%
Prof James Cameron	Planning study protocol, interpretation of data, writing and editing manuscript	10%

The undersigned hereby certify that the above declaration correctly reflects the nature and extent of the candidate's and co---authors' contributions to this work.

Candidate's Signature	[redacted]	**Date** 12/04/2016

Main Supervisor's Signature	[redacted]	**Date** 12/04/2016

Preface

Large clinical trial and registry studies of bioprosthetic valves (surgical and transcatheter) generally involve echocardiographic follow---up. Reported echocardiographic outcome measures include trans---prosthetic gradients, effective orifice area and degree of regurgitation. The lower spatial resolution of echocardiography, however, limits the ability to directly visualise the actual valve leaflets. The greater spatial resolution of MDCT offers a unique opportunity to visualise changes in leaflet form and function within a single imaging modality and builds on its proven use for aortoventricular interface anatomical assessment and prosthesis/anatomy geometric interactions outlined earlier in this thesis.

A recent work in this field[1] utilised MDCT imaging to identify that a significant minority of prostheses develop subclinical leaflet thickening. The following work, submitted to the Journal of the American College of Cardiology, is the first study to assess the rate of such leaflet change in the Lotus Valve System. The work also includes a longer---term follow---up giving the first indication of the temporal nature of this newly described phenomenon.

1. Makkar RR, Fontana G, Jilaihawi H, et al. Possible Subclinical Leaflet Thrombosis in Bioprosthetic Aortic Valves. N Engl J Med 2015;373:2015---24.

4---Dimensional Multidetector Computed Tomographic Assessment of Leaflet Thickening and Motion in Patients Treated with a Mechanically Expanded TAVR Prosthesis

R Gooley[1,2], J D Cameron[1,2], L McCormick[1], I T Meredith[1,2]

[1]MonashHeart, Monash Health, Clayton, Victoria, Australia

[2]Monash Cardiovascular Research Centre, Monash University, Clayton, Victoria, Australia

ABSTRACT

Aims

Subclinical leaflet thickening is a recently recognized entity following TAVR and bioprosthetic surgical valve replacement. The incidence and clinical significance over a longer follow---up remains uncertain. We sought to analyse this phenomenon in patients treated with the Lotus TAVR device.

Methods and Results

57 patients treated with the Lotus device at a single Australian centre underwent 4---dimensional multi---detector computed tomographic (MDCT) imaging of the aortoventricular interface and Lotus device. 20 patients underwent serial imaging resulting in 83 scans at a mean of 351 days (range 26 --- 1090 days) following implantation. Echocardiographic assessment of valve haemodynamics was performed at the same time points. 49.1% of the cohort were male with a mean age of 83.4±4.9 years. The mean Society of Thoracic Surgeons Predicted Risk of Mortality score was 3.89±2.25%.

Prosthesis leaflet thickening was found in 10 patients (17.5%) and 15 leaflets (8.8%). Leaflet thickening predominantly occurred in a triangular pattern at the insertion point, resulting in medial displacement of the leaflet hinge point and reduction in leaflet excursion.

Leaflet thickening was detected on initial imaging in seven patients (29, 31, 36, 63, 83, 331 and 752 days post implant), three patients showed no evidence of leaflet thickening or restriction on initial imaging (319, 331, 719 days post implant) but thickening was observed on serial imaging (1073, 1078, 1073 days post implant).

Ten patients (21.3%) among those with normal leaflet thickness, while none of those with leaflet restriction were on oral anticoagulation at the time of imaging (p=0.11).

The presence of leaflet thickening was associated with elevation in mean trans---prosthetic gradient (12.0±3.9mmHg vs 21.3±16.7mmHg, p=0.001). One patient with identified leaflet restriction and severe elevated trans---prosthetic gradient was commenced on oral anticoagulation resulting in a reduction in mean trans---prosthetic gradient from 65 to 29 mmHg after thirty days of treatment.

Conclusions

In this study, leaflet thickening was observed in 17.5% of patients and found to occur at variable time points following implantation. While most patients remain asymptomatic and without haemodynamic sequelae, the condition can result in significant trans---prosthetic gradients which seem to reduce following oral anticoagulant treatment. A large cohort

study with longer term follow---up is required to further describe the natural history of this newly recognized entity.

INTRODUCTION

Transcatheter Aortic Valve Replacement (TAVR) has gained widespread acceptance as the preferred treatment modality for extreme surgical risk patients with symptomatic severe aortic stenosis[1,2] and an acceptable alternative to surgical valve replacement in high surgical risk patients[3,4]. With an increasing burden of evidence regarding the safety and efficacy of TAVR its use has grown exponentially leading to an estimated greater than 200 000 procedures world---wide.

The relative infancy of TAVR together with treatment of elderly, frail individuals has contributed to a limited body of evidence regarding longer---term durability. Recent early imaging studies have, however, raised concerns regarding a variable incidence of leaflet thickening. This process, termed subclinical leaflet thrombosis, was first identified on multi---detector computed tomographic (MDCT) imaging studies[5]. An apparent thickening of the leaflet tissues and associated restriction of leaflet mobility was reported.

Small, early studies have suggested that this process can be found in most transcatheter and surgical bioprostheses. The process seems to be prevented by use of oral anticoagulation and indeed treatment with oral anticoagulation may resolve it.

The Lotus (Boston Scientific, Marlborough, MA, USA) transcatheter prosthesis utilizes a unique controlled mechanical expansion that results in near full expansion and high rates of circularization[6]. As such the haemodynamic forces the leaflets are exposed to and blood flow patterns may differ from other devices. As such, we sought to investigate the development of leaflet thickening and restriction by means of four---dimensional MDCT

imaging in this unique prosthesis. We also sought to perform serial imaging in a subset of patients to elicit whether delayed occurrence and or progression of this phenomenon was identified.

METHODS

Population

All patients undergoing treatment for symptomatic severe aortic stenosis with implantation of a Lotus prosthesis during the study period were assessed. All patients had severe aortic stenosis defined as an aortic valve area <1cm^2 and a mean trans---aortic gradient >40mmHg or aortic flow velocity >4m/s. All patients were deemed to be at high or extreme surgical risk by the institution's Heart Team. Patients were excluded if they declined participation, were unable to attend study follow---up or had baseline renal dysfunction (eGFR <30ml/min) which would preclude safe administration of contrast.

Index Procedure

All index procedures were performed by two experienced TAVI operators with device sizes chosen by MDCT assessment of the aortoventricular interface. All patients underwent transthoracic echocardiography (TTE) between 7 and 10 days following implantation to quantify the baseline trans---prosthetic gradient and effective orifice area (EOA). The degree of paravalvular aortic regurgitation (PAR) was also quantitated in accordance with Valve Academic Research Consortium version 2 (VARC2) criteria.

Multi---detector Computed Tomographic Imaging

Patients were then randomly assigned to undergo four---dimensional MDCT imaging of the aortoventricular interface at a variable time---point; 30---days, 6---months or 12---months following implantation. One third of patients also underwent serial MDCT imaging.

All MDCT scans were performed on an Aquilion One 320---detector row scanner (Toshiba Medical Systems, Otawara, Japan). No heart rate control was employed. All scans utilized a retrospective (full R---R interval) window with images reformatted at 10% intervals. Collimation was individualized to achieve a z---axis that encompassed the entire aortoventricular interface. Slice thickness was 0.5mm. Gantry rotation speed was 275 ms per rotation, tube voltage 100---120kV and tube current individualised to body habitus.

Intravenous contrast (Omnipaque 350, GE Healthcare, USA) was administered via an 18---gauge antecubital vein as a 70ml bolus followed by a 50ml saline bolus at a rate of 6ml/s. Scanning acquisition was triggered manually by monitoring for contrast density in the descending aorta to ensure adequate contrast opacification.

All patients underwent MDCT imaging at 30---days, 90---days, 1---year or 2---years following the index procedure. 20 patients underwent serial imaging resulting in a total of 83 scans.

MDCT Analysis

All scans were analysed by an experienced cardiac CT Cardiologist using a Vitrea (Vital Images Inc, Minnetonka, MN, USA) reporting platform. Each leaflet was assessed in a

diastolic phase through the middle of the leaflet with leaflet thickness measured, when possible in the limits of the spatial resolution of the scan, at the insertion, mid and tip. When detected the pattern of leaflet thickening was qualitatively described.

The extent of leaflet motion was described semi---quantitatively as normal, mildly reduced (<50% reduction in excursion), moderately reduced (50---70%) and severely reduced (>70%). Additionally, the angle of leaflet opening in relation to the vertical valve frame (Figure 1E) and distance between leaflet tip and valve frame (Figure 1D) were measured.

Transthoracic Echocardiography

All patients underwent transthoracic echocardiographic imaging at baseline and at the same time point as the post---procedural MDCT imaging. Echocardiograms were analysed by a Consultant Echocardiologist who was blinded to the MDCT findings, with particular attention to prosthesis function reported in accordance with societal recommendations.

RESULTS

Population

123 patients underwent TAVR with the Lotus prosthesis during the study period. 30 patients declined study enrolment, 36 patients were excluded due to renal impairment resulting in prospective enrolment of 57 patients. The mean transaortic gradient was 49.4±14.8 mmHg and valve area 0.74±0.21cm^2. The mean age at enrolment was 83.4±4.9 years with 49.1% male. There were no significant differences in baseline characteristics between those with or without leaflet thickening (Table 1).

Table 1: Baseline characteristics

	Total Population (n=57)	Normal Leaflets (n=47)	Leaflet Thickening (n=10)	p-Value
Age (years)	83.4±4.9	83.3±4.8	83.6±5.5	0.88
Gender - male	28 (49.1%)	23 (48.9%)	5 (50%)	0.95
NYHA Class				
I	0 (0%)	0 (0%)	0 (0%)	
II	17 (29.8%)	15 (31.9%)	2 (20%)	
III	32 (56.1%)	25 (53.2%)	7 (70%)	
IV	8 (14.1%)	7 (14.9%)	1 (10%)	0.62
Diabetes Mellitus	13 (22.8%)	10 (21.3%)	3 (30%)	0.55
Hypertension	47 (82.5%)	38 (80.9%)	9 (90%)	0.49
Atrial Fibrillation	13 (22.8%)	12 (25.5%)	1 (10%)	0.28
Previous Coronary Bypass	11 (19.3%)	7 (14.9%)	4 (40%)	0.07
Previous Stroke	13 (22.8%)	11 (23.4%)	2 (20%)	0.82
Risk Score				
STS PROM	3.89±2.25	3.96±2.37	3.51±1.68	0.49
STS M&M	20.94±6.92	21.09±7.20	20.28±5.72	0.70
EUROSCORE II	4.12±3.38	3.97±3.32	4.84±3.76	0.51
Echocardiography				
Mean gradient (mmHg)	49.4±14.8	48.7±13.2	52.5±21.1	0.60
Peak gradient (mmHg)	83.3±23.9	82.2±21.2	88.2±35.0	0.62
Aortic Valve Velocity (m/s)	4.5±0.8	4.5±0.8	4.6±0.9	0.54
Aortic Valve Area (cm^2)	0.74±0.21	0.76±0.22	0.66±0.12	0.20
Ejection Fraction (%)	59.5±12.2	60.1±11.3	57.0±16.2	0.58
Pulmonary Pressure (mmHg)	39.5±11.0	39.7±11.3	38.3±10.1	0.75
Medication				
Aspirin	35 (61.4%)	29 (61.7%)	6 (60%)	0.92
Thienopyridine	6 (10.5%)	6 (12.8%)	0 (0%)	0.23
Warfarin	6 (10.5%)	6 (12.8%)	0 (0%)	0.23
Novel Oral Anticoagulant	4 (7.0%)	4 (8.5%)	0 (0%)	0.33
Any Oral Anticoagulant	10 (17.5%)	10 (21.3%)	0 (0%)	0.11

Index Procedure

The majority of procedures (71.9%) were performed under general anaesthesia with transoesophageal echocardiographic guidance. 19 patients received a 23mm, 10 patients a 25mm and 18 patients a 27mm device. There were no differences in prosthesis size implanted or the extent of device oversizing between those with normal leaflet thickness and those who developed leaflet thickening and restriction (Table 2).

Table 2: Procedural Characteristics

	Total Population (n=57)	Normal Leaflets (n=47)	Leaflet Thickening (n=10)	p-Value
Device Size				
23mm	22 (38.6%)	19 (40.4%)	3 (30%)	
25mm	12 (21.1%)	10 (21.3%)	2 (20%)	
27mm	23 (40.3%)	18 (38.3%)	5 (50%)	0.77
Device Oversizing (%)				
Area	13.0±11.7	13.3±10.9	11.4±15.1	0.72
Perimeter	4.2±5.2	4.4±4.9	3.4±6.3	0.66
Use of Pre-dilatation (no.)	55 (96.5%)	45 (95.7%)	10 (100%)	0.51
Balloon size (mm)	17.8±3.0	17.6±3.0	18.8±3.0	0.26
Transoesophageal Echo (no.)	41 (71.9%)	34 (72.3%)	7 (70%)	0.88

Multidetector Computed Tomographic Assessment

MDCT imaging in all 57 patients and all 83 scans was deemed to be of adequate quality for interpretation. Assessment of leaflet motion identified 10 (17.5%) patients with reduction in leaflet excursion. The severity of leaflet restriction was mild in 3 patients, moderate in 4 patients and severe in 3 patients. In six patients only 1 leaflet was affected, in three patients 2 leaflets and in one patient all 3 leaflets showed restriction.

Leaflet thickening occurred in a triangular pattern at the point of leaflet insertion and then with a variable degree of thickening of the leaflet body and tip (Figure 1). The triangular pattern of thickening at the leaflet insertion resulted in medial displacement of the leaflet inflection or hinge point and increase in the angulation between the systolic leaflet position and the valve frame (Figure 2).

Figure 1: Example of Leaflet Assessment

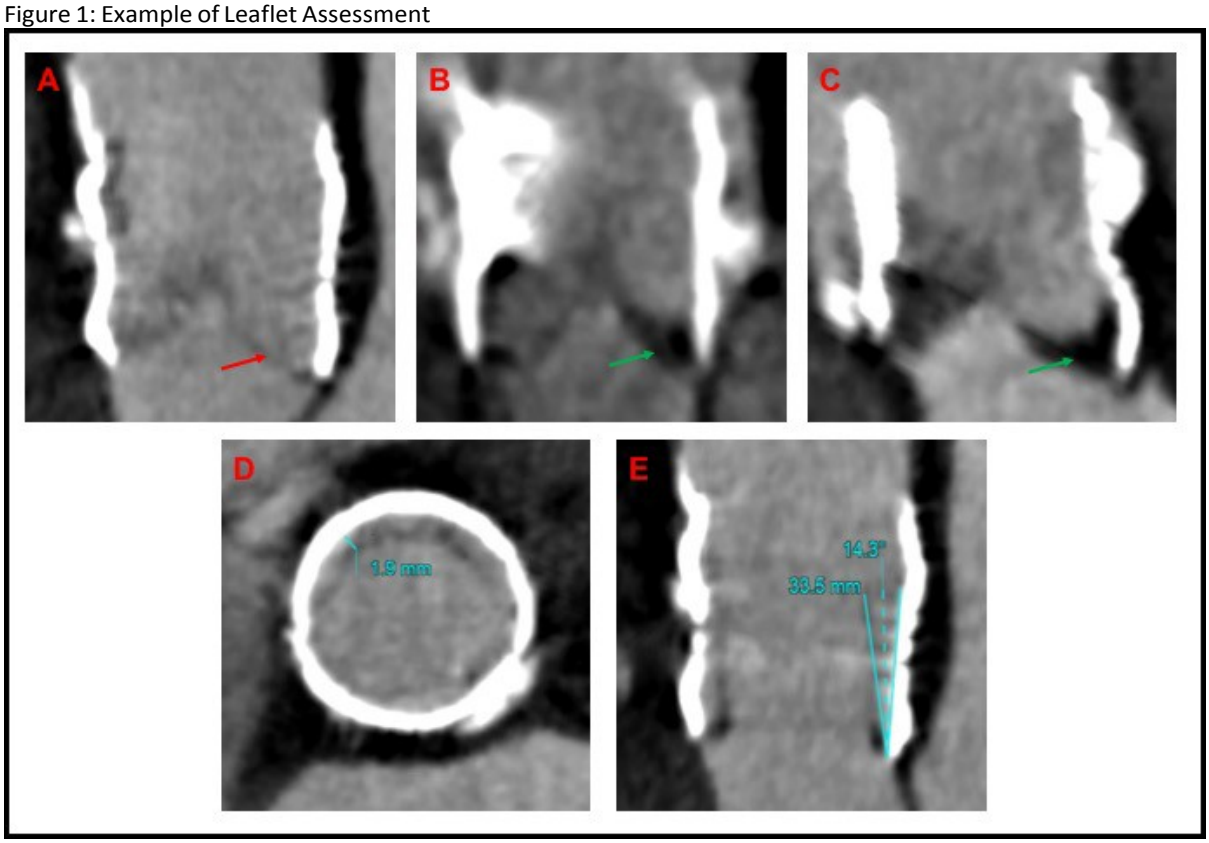

Figure 1A – An example of normal leaflet thickness (Red Arrow)

Figure 1B and C – Examples of leaflet thickening with a triangular pattern of leaflet thickening at the attachment point extending a variable distance along the leaflet length

Figure 1D and E – Quantification of leaflet excursion

Figure 2: Leaflet Restriction Throughout the Cardiac Cycle with Medial Displacement of the Inflection Point

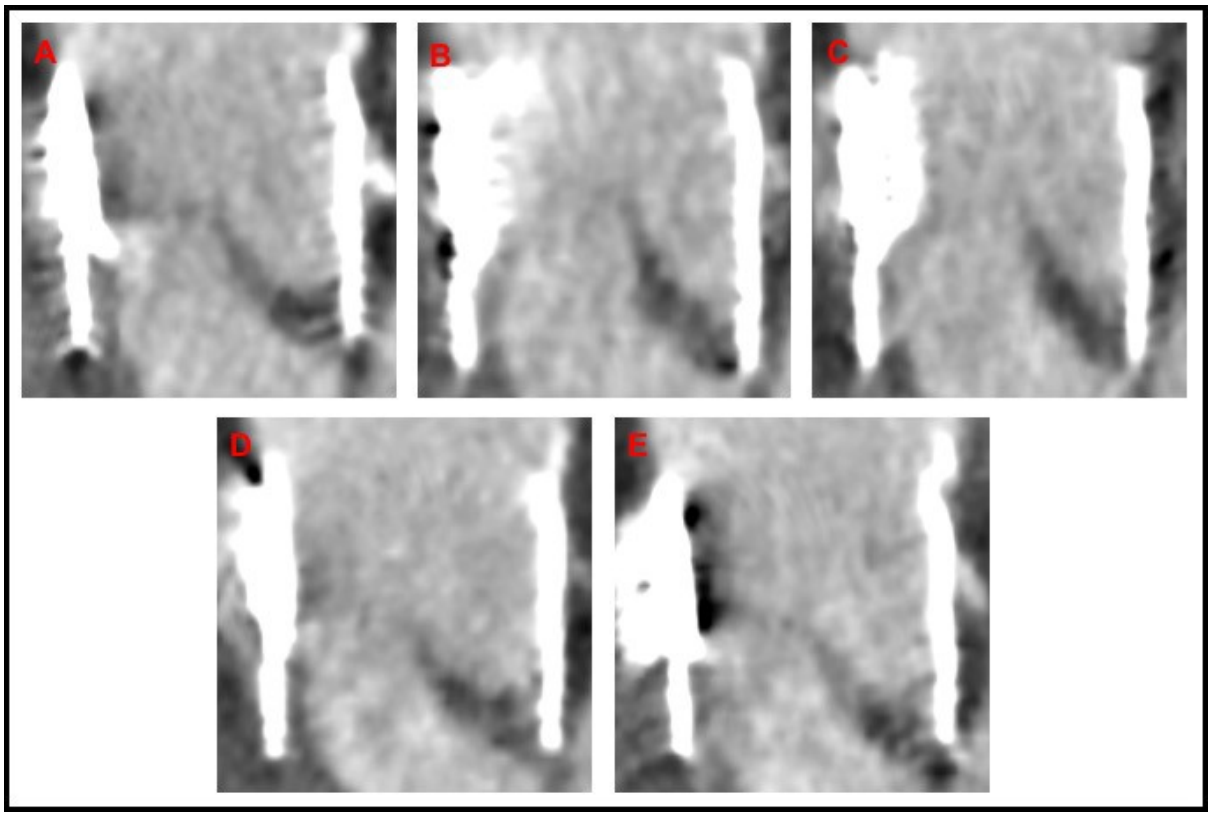

Figure 2 – An example of the restricted movement of a thickened leaflet throughout the cardiac cycle (A---0% RR Interval, B---20%, C---40%, D---60%, E---80%)

Transthoracic Echocardiography

The mean transprosthetic gradient was significantly higher in those patients with leaflet thickening, 12.0±3.9mmHg versus 21.3±16.7mmHg, p=0.001. This was largely driven by a single patient with a severe transprosthetic gradient of 65mmHg, once this patient was excluded there was still an apparent difference, 12.0±3.9mmHg versus 16.4±7.0mmHg, p=0.01. There were no differences detected in EOA, degree of para---prosthetic regurgitation or pulmonary pressure between the two groups (Table 3).

Clinical Sequelae

One patient with a severely elevated mean transprosthetic gradient of 65mmHg was commenced on oral anticoagulant therapy with Warfarin. Serial echocardiography demonstrated a gradual reduction in the gradient to 29mmHg after 30---days treatment. All other patients with demonstrated leaflet thickening have been followed with serial echocardiography and clinical review at a median of 370 days (IQR 156---415) following detection of leaflet thickening but have not been commenced on anticoagulant therapy. Three patients with leaflet thickening underwent repeat MDCT imaging 12---months later with no significant progression in number of leaflets affected or the severity of leaflet restriction.

No increase in occurrence of neurological event (stoke or TIA) was identified in those patients with leaflet thickening, 2 (4.3%) versus 1 (10%) p=0.46 or disabling stroke, 1 (2.1%) versus 0 (0%) p=0.82. There were no deaths in either cohort during the study follow---up.

Table 3: Echocardiographic Indices at Follow---up

	Total Population (n=57)	Normal Leaflets (n=47)	Leaflet Thickening (n=10)	p---Value
Mean Gradient (mmHg)	13.7±8.4	12.0±3.9	21.3±16.7	0.001
Peak Gradient (mmHg)	26.0±14.7	23.3±8.4	38.8±27.4	0.002
Aortic Valve Velocity (m/s)	2.5±0.6	2.4±0.5	2.9±1.0	0.007
Effective Orifice Area (cm^2)	1.88±0.38	1.93±0.36	1.35±0.21	0.10
Aortic Regurgitation				
None/Trivial	53 (93.0%)	43 (91.5%)	10 (100%)	
Mild	4 (7.0%)	4 (8.5%)	0 (0%)	
Moderate or Greater	0 (0%)	0 (0%)	0 (0%)	0.36
Pulmonary Artery Pressure (mmHg)	38.5±9.4	39.4±9.9	34.3±5.8	0.15

DISCUSSION

Transcatheter aortic valve replacement has provided a treatment modality for a cohort of patients who may previously have been denied definitive intervention. Information regarding the durability of TAVR devices is only just emerging as sufficient numbers of treated patients and time since insertion reaches a critical mass. This, together with the use of MDCT imaging and its higher spatial resolution have identified a small but potentially significant incidence of 'subclinical leaflet thrombosis'. This phenomenon was identified in most bioprostheses studied, surgical and transcatheter, though the majority of the devices investigated were the Portico (St Jude Medical, Little Canada, MN, USA) transcatheter prosthesis[5].

This study is the first to look at the incidence and time course of leaflet thickening in patients treated with the Lotus device. The unique deployment mechanism of the Lotus device and its resultant interaction with the native aortoventricular interface[6] may alter blood flow patterns, sheer forces on the valve leaflets and hence different rates of leaflet thickening. Leaflet thickening was identified in 17.5% of the cohort which is comparable to the rates identified by Makkar et al in the Portico IDE trial (40%) and reported registries (13%).

While leaflet thickening was associated with an elevation in mean transprosthetic gradient the clinical significance of this in most cases is likely to be negligible. In only one of the ten patients did the measured gradient reach a clinically significant, severe range. This patient was commenced on warfarin and the gradient subsequently improved. In another three cases leaflet thickening and restriction did not progress on serial imaging. Within this study there was no indication of elevated adverse events such as stroke or death associated with leaflet thickening.

Despite the significant rate of leaflet thickening (17.5%) the results of this study do not support routine surveillance MDCT imaging. Rather regular echocardiographic imaging which does not require contrast administration or ionising radiation could be used to follow transvalvular gradients. If elevated gradients are identified MDCT imaging may be used to aid the diagnosis of subclinical leaflet thrombosis.

The finding that no patient taking oral anticoagulation developed leaflet thickening and that one patient with a significantly elevated gradient improved on oral anticoagulation suggests

that it may be protective. As the process has not, however, been shown to result in elevated stroke or mortality risk routine use of oral anticoagulation could not be recommended based on this study alone but should be investigated further in larger cohorts.

CONCLUSIONS

In this study, leaflet thickening was observed in 17.5% of patients and found to occur at variable time points following implantation. While most patients remain asymptomatic and without haemodynamic sequelae, the condition can result in significant trans---prosthetic gradients which seem to reduce following oral anticoagulant treatment. A large cohort study with longer term follow---up is required to further describe the natural history of this newly recognized entity.

REFERENCES

1. Kodali SK, Williams MR, Smith CR, et al. Two---year outcomes after transcatheter or surgical aortic---valve replacement. N Engl J Med 2012;366:1686---95.

2. Adams DH, Popma JJ, Reardon MJ. Transcatheter aortic---valve replacement with a self---expanding prosthesis. N Engl J Med 2014;371:967---8.

3. Makkar RR, Fontana GP, Jilaihawi H, et al. Transcatheter aortic---valve replacement for inoperable severe aortic stenosis. N Engl J Med 2012;366:1696---704.

4. Popma JJ, Adams DH, Reardon MJ, et al. Transcatheter aortic valve replacement using a self---expanding bioprosthesis in patients with severe aortic stenosis at extreme risk for surgery. J Am Coll Cardiol 2014;63:1972---81.

5. Makkar RR, Fontana G, Jilaihawi H, et al. Possible Subclinical Leaflet Thrombosis in Bioprosthetic Aortic Valves. N Engl J Med 2015;373:2015---24.

6. Gooley RP, Cameron JD, Meredith IT. Assessment of the geometric interaction between the Lotus transcatheter aortic valve prosthesis and the native ventricular aortic interface by 320---multidetector computed tomography. JACC Cardiovasc Interv 2015;8:740---9.

Chapter 6: Conclusions and Future Directions

The work presented in this thesis has furthered the field of transcatheter aortic valve replacement. Work presented has highlighted the utility of multi---detector computed tomographic imaging assessment of the aortoventricular interface, the impact of TAVR on native anatomy and the device specific features of the Lotus Valve System.

A detailed understanding of aortoventricular interface anatomy and geometry is imperative to understanding its function in the setting of health but possibly even more so in the setting of disease. The work presented in Chapter 2 has provided the foundation for a uniform description of the native aortoventricular interface in routine clinical reporting of computed tomographic scans and for research trials by quantification of normative ranges and demographic predictors of dimensions formulated with a standardised and reproducible technique. The formation of normative ranges that encompass a representative breadth of the population also provides guidance for future TAVR device iteration that will provide appropriate population coverage.

Simple awareness of the native anatomy is however not sufficient and it is imperative to understand how a new treatment modality may impact the form and function of this anatomy. Chapter 3 highlights that extrapolation of information regarding prior device types is not appropriate. Unlike self---expanding devices and more in keeping with balloon---expanded devices, this work found that the Lotus Valve System results in high rates of circularisation as the valve achieves near full expansion to the stated device size even when deployed in highly eccentric anatomy. This information has been crucial in the development of appropriate sizing algorithms for the Lotus valve which dictate anatomical assessment of the entire aortoventricular interface and avoidance of excessive prosthesis oversizing. This is likely to

have contributed to the favourable outcomes in published trials assessing the efficacy and safety of the Lotus prosthesis with no reported cases of annular rupture or ectopic valve deployment or need for TAV in TAV.

To date, however, evidence supporting the efficacy and safety of the Lotus Valve System has been from single arm studies (REPRISE I, REPRISE II, REPRISE II Extension) and large registries (RESPOND). Chapter 4 represents the first and currently only fully core laboratory adjudicated comparison of the Lotus Valve System with a contemporary TAVR device, the CoreValve ReValving System. Work such as this is vital in ensuring that new devices and device iterations result in net clinical benefit. Using VARC---2 defined endpoints, this work found that the Lotus Valve System resulted in higher rates of device success driven by a higher rate of correct anatomical positioning of a single device and lower rates of moderate or greater paravalvular regurgitation. The CoreValve ReValving System, however, resulted in a lower mean trans---prosthetic gradient. These findings support the efficacy of the Lotus design features though also highlight that in some instances such as small annuli the supra---annular placement of the CoreValve leaflets may be advantageous in achieving a lower prosthetic gradient and larger EOA. These findings need to be confirmed in a larger randomised trial and the soon to be reported REPRISE III study will provide this.

The work presented in the earlier chapters of this thesis highlight the importance of three---dimensional MDCT imaging in procedural planning and device frame interrogation. Four dimensional MDCT imaging, combining the excellent spatial resolution with the time domain of functional imaging, has facilitated leaflet interrogation and identification of a newly described phenomenon, subclinical leaflet thrombosis. The work presented in Chapter 5

identified leaflet thickening in 17.5% of patients treated with the Lotus Valve System. While leaflet thickening was associated with an increase in trans---prosthetic gradient only one patient developed a clinically significant gradient which improved following commencement of oral anticoagulation. Additionally, no patients who were on oral anticoagulation demonstrated leaflet thickening. While a definitive recommendation regarding the use of oral anticoagulation following TAVR can not be made on the basis of this trial the fact that no increased incidence of adverse event such as neurological event was observed supports the use of current antiplatelet regimens while further research is conducted. Future trials need to address the use of anticoagulation following TAVR in a randomised trial. Further work is also need in larger cohorts to identify predictors of leaflet thickening.

Appendix A – Other Published Work

The following work was completed during PhD enrolment and has been published following peer review. Each manuscript builds on the overall body of work regarding transcatheter aortic valve replacement, the Lotus Valve System and the role of multi---detector computed tomographic imaging.

Published Manuscripts

1. Gooley R, Lockwood S, Antonis P, Meredith IT. The SADRA Lotus Valve System: a fully repositionable, retrievable prosthesis. Minerva Cardioangiol 2013;61:45---52.

2. Gooley R, Antonis P, Meredith IT. The next era of transcatheter aortic valve replacement: a case illustrating the benefit of a fully re---positionable, re---sheathable, and retrievable prosthesis. Catheter Cardiovasc Interv 2014;83:831---5.

Book Chapters

The Interaction Between Psychological Health and valvular Heart Disease: Pathogenesis, Clinical Course and Treatment. Published in *Handbook of Psychocardiology*. Edited M Alvarenga and D Byrne. Springer Science and Business.

MINERVA CARDIOANGIOL 2013;61:45-52

The SADRA Lotus Valve System: a fully repositionable, retrievable prosthesis

R. GOOLEY, S. LOCKWOOD, P. ANTONIS, I. T. MEREDITH

MonashHEART, Monash Medical Centre, Southern Health, Melbourne, Australia

Transcatheter aortic valve implantation (TAVI) has become the preferred treatment option for patients with severe aortic stenosis at extreme surgical risk and an acceptable alternative to surgical aortic valve replacement in patients at high risk. Despite a growing amount of evidence in support of TAVI there remain important limitations and recognized complications. The SADRA Lotus Valve System is a novel TAVI device capable of allowing full repositionability and retrievability, which may address some of the first generation limitations.

KEY WORDS: Aortic valve - Aortic valve stenosis - Heart valve prosthesis implantation.

Transcatheter aortic valve implantation (TAVI) has gathered widespread acceptance as an alternative treatment for selected high-risk patients with symptomatic severe aortic stenosis.[1] It has also proven to be a superior treatment compared to medical management in people denied surgical aortic valve replacement (AVR).[2] With an ageing population and evidence that approximately 30% of people suffering severe calcific aortic stenosis are denied surgery [3] the importance of this alternative treatment modality will continue to grow.

Since Alain Cribier implanted the first device in 2002 [4] there has been a continual evolution in technology and associated improvements in patient outcomes. To date more than 50000 TAVI devices have been implanted worldwide with the vast majority being either the Edwards Sapien (Edwards Lifesciences Inc, Irvine, CA, USA) or Medtronic CoreValve (Medtronic Inc, Minneapolis, MN) devices. Both of these prostheses have progressed through a number of device and delivery catheter changes designed to improve device function, facilitate ease of operation and reduce complications.

Corresponding author: Professor I. T. Meredith, Monash HEART, Monash Medical Centre, Southern Health and Monash University, Melbourne, 246 Clayton Road, Clayton VIC 3168 Australia. E-mail: ian.meredith@myheart.id.au

Current device limitations and complications

Despite expanding clinical trial evidence demonstrating that TAVI provides superior outcomes compared to medical therapy, and equivalent outcomes to surgical AVR in select high and extreme risk patients, there remains a modest complication rate[1,2]. Such complications impact long-term patient outcomes [5] and potentially limit the adoption of this technology for lower risk individuals[6].

Conduction disturbance

The requirement for permanent pacing following TAVI varies between devices.[1, 2, 7] Most registries demonstrate that rates of requirement for permanent pacing are reducing over time [8] as operators become more adept at accurate valve positioning. There is no current trial evidence that requirement for pacing is associated with long-term adverse outcomes although some recent data suggests that development of a left bundle branch block may impact outcome.[9]

Stroke and transient ischemic attacks

Clinically apparent stroke rates following TAVI have been reported to range from 2 to 5 percent,[1, 2, 8] with newer registry data suggesting that the incidence of stroke may be lower than initially reported. MRI based studies demonstrate that the procedure is associated with significant subclinical cerebral embolization [10] and thus ongoing research is focusing on the use of embolic protection devices, antiplatelets and antithrombotic regimens during TAVI to reduce this.

Bleeding and vascular complications

Vascular complication rates have also shown a steady decline since the first generation TAVI iterations entered clinical trial and practice.[1, 2, 8] This has been attributed to better screening utilising multimodality imaging of the vasculature, improved access techniques, a reduction in sheath size and improved sheath technology and better closure techniques including cross-over balloon occlusion techniques.

Of these, sheath size reduction has been the most significant contributor. The Edwards Sapien XT valves can be delivered through an 18Fr femoral sheath or smaller 16 Fr expandable sheath. The current iteration Medtronic CoreValve device can be delivered through an 18 Fr sheath. Future devices hold the promise for even smaller delivery systems.

Device embolization

Migration of the prosthesis into the aorta or embolization into the left ventricle may occur when the prosthesis does not anchor securely due to insufficient interference between prosthesis, native valve and the basal ring. Prevention of device embolization requires detailed knowledge of device geometry, accurate preprocedural sizing and assessment of the degree of calcification.

Paraprosthetic aortic regurgitation

Of all these complications paraprosthetic aortic regurgitation (PAR) has become the Achilles' heel of TAVI[5,11]. Even mild levels of PAR appear to be associated with adverse outcomes.[1] The cause of PAR is multifactorial but the mismatch between the circular prosthesis and the non-circular, often elliptical, native aortic annulus is a critical component. The non-circular nature of the basal ring has highlighted the limitations of echocardiography used alone to size the basal ring. Recognition that multi-detector CT (MDCT) imaging provides a more accurate representation of the complex geometry of the basal ring and improves pre-procedural sizing [12] has gone someway to reducing the occurrence of PAR.[13, 14]

Despite these improvements sizing alone cannot eliminate PAR and so device manufacturers have focused on changes to prosthesis design. Two features have been used; the addition of a membrane to the valve frame and the ability to more accurately position the valve.

Membranous seals around the lower portion of the valve frame aim to prevent PAR through small gaps left between the circular device, the residual native leaflets following balloon valvuloplasty and the elliptical native basal ring.

The height at which the prosthesis is deployed relative to the basal ring has been shown in registry data to impact on the degree of PAR.[15] Newer devices, with the ability to accurately position the valve and even reposition offer the potential to eliminate this as a contributing variable.

New generation TAVI devices

A number of new generation transcatheter valves have entered clinical trial and even clinical use in some markets. These devices have been designed to reduce complication rates while maintaining the proven efficacy of TAVI technology. Many of the devices currently under investigation have focused on improving the operator's ability to accurately position the valve and offering the possibility to alter the position if it is not optimal.[16]

SADRA Lotus Valve System

Valve components

The SADRA Lotus Valve System (Boston Scientific, Natick, MA, USA) has a number of design features aimed at improving efficacy, safety and ease of use. The prosthesis consists of a braided frame woven from a single extruded nitinol wire. A radio-opaque, tantalum marker is positioned at the vertical mid-point of the frame height to aid accurate prosthesis positioning. Three leaflets, fashioned from bovine pericardium, are sutured to the valve frame. The outer surface of the inflow portion of the nitinol frame is covered in an Adaptive™ seal. The seal is made of a blended polymer and designed to occlude interstices between the circular prosthesis and non-circular annulus, which can contribute to PAR. (Figure 1)

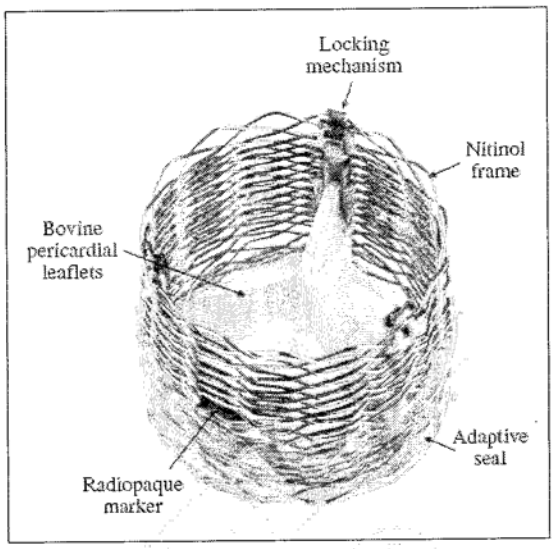

Figure 1.—The Lotus Valve Components.

Delivery system

The prosthesis is pre-mounted on the delivery catheter, obviating the time-consuming step of mounting and crimping in the catheterisation laboratory. The delivery catheter has a lubricious surface and is pre-shaped to allow easy passage through the peripheral vasculature and across the aortic arch. The valve and delivery system are compatible with a proprietary 18 Fr femoral sheath allowing delivery through femoral vessels as small as 6 mm (Figure 2).

The delivery handle is ergonomically designed with intuitive controls. The control knob allows the valve to be progressively unsheathed, deployed and locked with counter-clockwise rotation or, conversely, retrieval and resheathing by clockwise rotation. Torque transmission is excellent. Valve release is accomplished by sliding the release collar forward and clockwise rotating the release mechanism to detach the couplers. This is all carried out under fluoroscopic guidance.

Locking mechanism

The device utilises a unique locking mechanism. The 70 mm constrained device radially expands as it is mechanically shortened to its final frame height of 19 mm. Anti-clockwise rotation of the ergonomic handle causes valve shortening along three mandrils until, at full expansion, the locking mechanism is engaged and prevents recoil. The expansion provides the radial force required to provide interaction between the device, residual native leaflets and basal ring. The locking mechanism is fully reversible, making the valve repositionable and retrievable even after locked into its functioning position. This allows the operator to perform a detailed angiographic and echocardiographic assessment of the valve

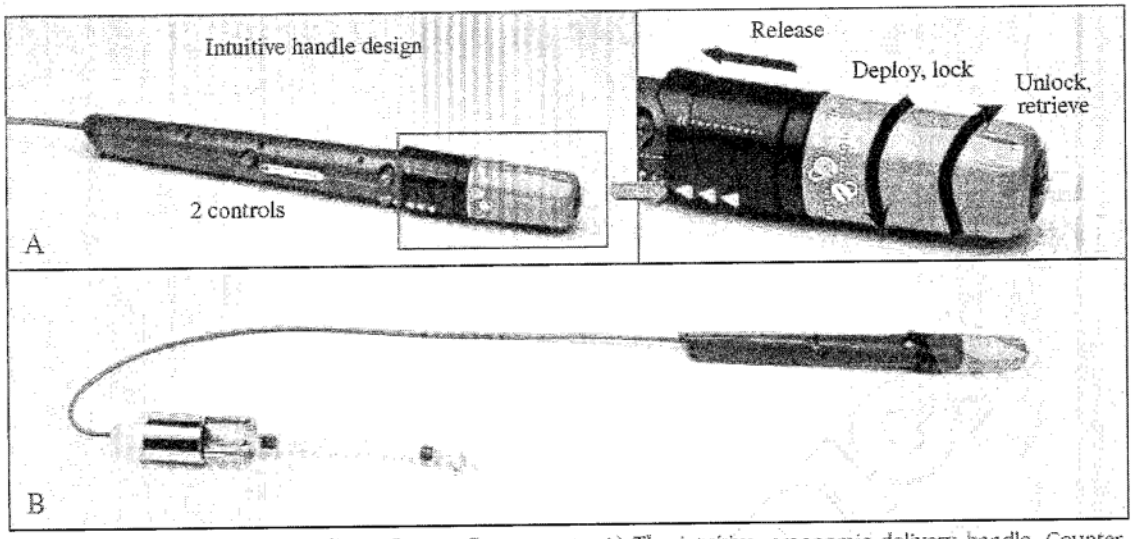

Figure 2.—The SADRA Lotus Delivery System Components. A) The intuitive, ergonomic delivery handle. Counter-clockwise rotation allows unsheathing of the valve while clockwise rotation resheaths; B) the pre-loaded valve avoids the need for mounting and crimping in the catheterization laboratory while the pre-shaped delivery catheter allows the valve to easily traverse the peripheral vasculature and aortic arch.

position and function prior to release and affords the opportunity to reposition the valve or even fully recapture and remove the device.

The valve functions very early during the deployment and hence reduces the potential duration of hypo-perfusion and need for rapid ventricular pacing.

Reprise clinical program

The third iteration of the Sadra Lotus Valve System underwent a first-in-man trial (Reprise I) at three Australian sites in 2012. Eleven patients were enrolled and all had a 23 mm Sadra Lotus device implanted. The 7 day results from the Reprise I trial were presented at EuroPCR 2012.[17] The primary endpoint was clinical procedural success through to discharge or 7 days, defined as device success without in-hospital major cardiovascular or cerebrovascular events (MACCE) using Valve Academic Research Consortium (VARC) definitions.[18]

The next phase of device evaluation, Reprise II, will involve recruitment of 120 patients at 15 centres in Australia and Europe. Reprise II will also see the introduction of a second valve size, 27 mm. There are plans for a global randomised control trial, Reprise III.

Patient selection

Current study enrolment requires that patients have symptomatic severe aortic stenosis, are aged 70 years or older and are considered to be at high surgical risk; defined as an STS Mortality score >8 or the consensus opinion of the Heart Team. A Cardiologist and Cardiothoracic Surgeon review patients prior to discussion at a Heart Team Meeting. The Heart Team includes the treating cardiologist, interventional cardiologist, imaging cardiologist, cardiothoracic surgeon, TAVI co-ordinator and cardiac anesthetist.

All patients undergo a transthoracic echocardiogram (TTE), invasive left and right heart catheterisation and a multi-detector CT (MDCT) assessment of the aortic basal plane and peripheral vasculature. The currently available 23 mm and 27 mm prostheses are designed to fit native annuli between 19 mm and 27 mm. The native annulus is assessed by both TTE and MDCT. The MDCT is analysed using the 3Mensio Valves™ software program. The basal plane is defined as the plane joining the nadir of each aortic cusp. The annular short axis is analysed and the perimeter traced. The annular diameter is derived from the perim-

eter by dividing by pi. The MDCT is also used to assess the ilio-femoral vasculature for size, tortuosity and calcification to ensure it is of suitable calibre to accommodate an 18 Fr sheath; that is greater than 6mm in diameter. We also utilise the MDCT images to determine optimal angiographic implantation angle.

Case example

A case from the recently completed REPRISE I trial provides a useful insight into the SADRA Lotus Valve System, its delivery and deployment. One such case was an 86 year old female with diet controlled Type II diabetes mellitus, previous cerebrovascular disease (event >12 months pre-procedure), esophageal ulceration (>5 years pre-procedure), diverticulitis with previous sigmoid colectomy, osteoarthritis, polymyalgia rheumatic requiring prednisolone, vitamin B12 deficiency, and pulmonary asbestos plaques. She presented with severe symptomatic aortic stenosis (New York Heart Association Class III).

Echocardiography revealed a heavily calcified tri-leaflet aortic valve with an estimated peak and mean pressure gradient of 70 and 41 mmHg respectively, an aortic

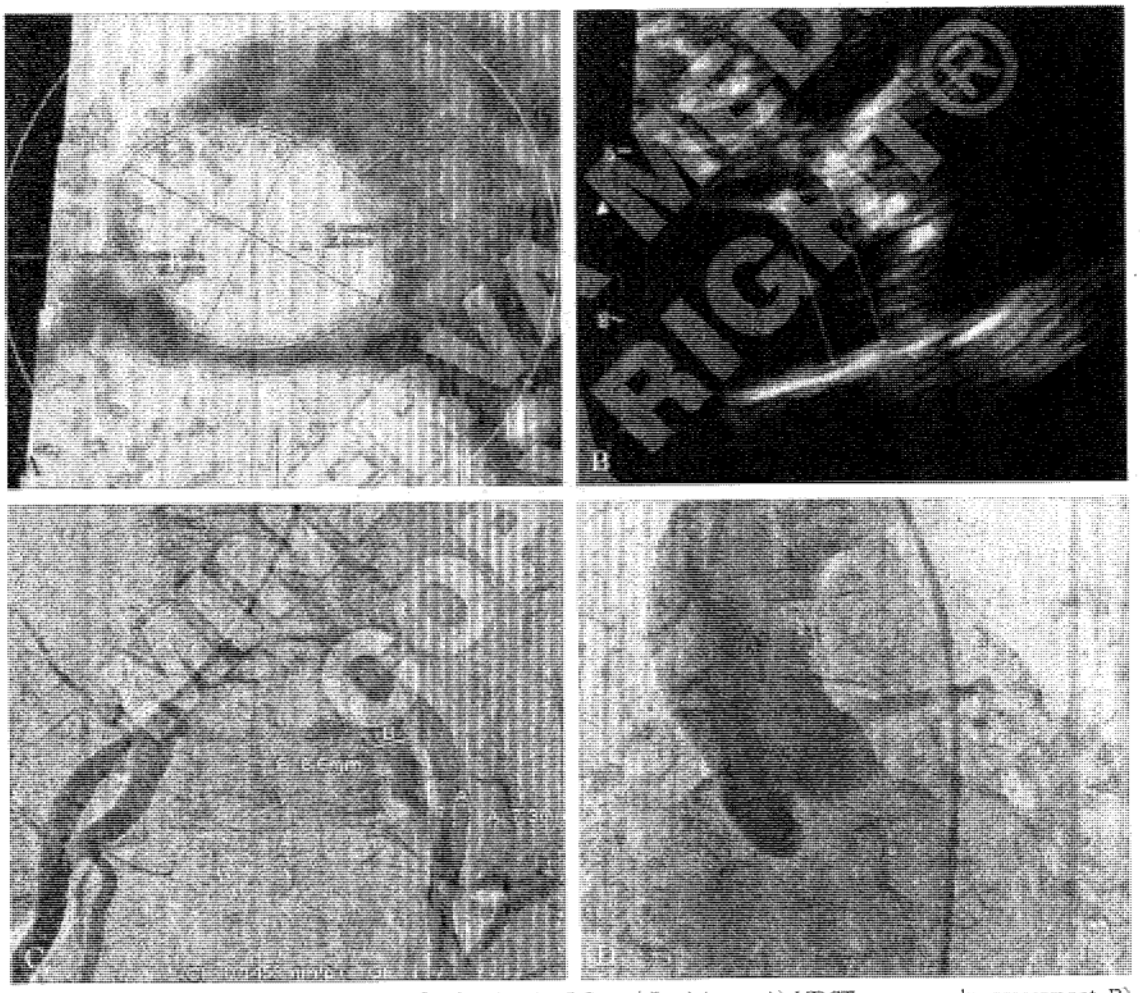

Figure 3.—Routine Work-up Investigation for the Reprise I Case 4 Participant. A) MDCT scan annular assessment; B) TTE annular and left ventricular outflow tract measurement; C) peripheral angiography with a graduated pigtail catheter to allow accurate measurement; D) aortography to assess annular size, coronary height and the vertical position of the annular plane.

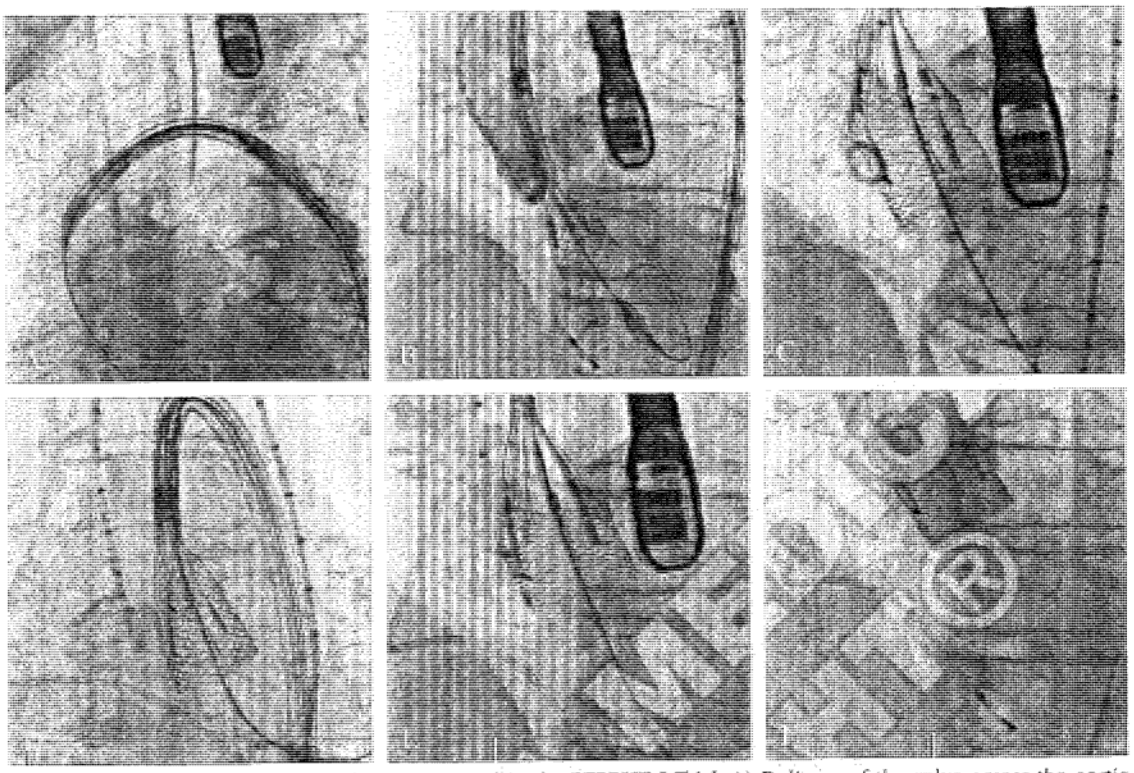

Figure 4.—SADRA Lotus Valve Deployment Case 4 in the REPRISE I Trial. A) Delivery of the valve across the aortic arch; B) unsheathing the valve by counter-clockwise rotation of the handle. Maintaining the tantalum marker at the midpoint of the native leaflets; C) reaching towards full expansion the valve was deemed too low; D) the Valve was partially resheathed by clockwise rotation of the handle; E) the valve was positioned optimally with the tantalum marker at the midpoint of the native leaflets; F) following full angiographic and echocardiographic assessment the valve was released.

valve area of 0.8cm², and a left ventricular ejection fraction of 65%. An angiogram prior to the procedure showed no significant coronary artery disease. STS mortality and morbidity scores were calculated to be 6.06% and 26.49% respectively, and logistic euroSCORE 11.96%.

The patient underwent an invasive left and right heart catheterisation, TTE and MDCT scan in accordance with the study protocol. The multidiscipline Heart Team reviewed her case and she was accepted for TAVI utilising the SADRA Lotus Valve System (Figure 3).

The procedure was performed under general an esthesia to facilitate transoesophageal echocardiography. A balloon tipped temporary pacing catheter was inserted via the right internal jugular vein and positioned at the right ventricular apex. A 6 Fr sheath was inserted in the non-deployment femoral artery while the deployment artery was cannulated under angiographic guidance and the proprietary 18 Fr sheath inserted.

The aortic valve was crossed using a straight wire and exchanged for a stiff wire. A balloon vavluloplasty was then performed during rapid ventricular pacing. Following this the SADRA Lotus Valve System was inserted on the delivery catheter to the native annulus. The pre-shaped delivery catheter and its lubricious coating facilitated easy passage through the peripheral vasculature and across the aortic arch (Figure 4A). The radio-opaque tantalum marker was then used to maintain the device at the desired implantation position as the valve was unsheathed and deployed (Figure 4B). Valve deployment was achieved by counter-

clockwise rotation of the delivery handle allowing the valve to shorten and radially expand.

At near full deployment the position was deemed to be marginally low (Figure 4C). While this position could have been judged acceptable, the unique capacity to retrieve and reposition the device allowed more optimal annular positioning. This was achieved by clockwise rotation of the delivery handle to lengthen and partially compress the valve (Figure 4D) to allow valve movement and then redeployment by counter-clockwise rotation of the handle (Figure 4E). Once the operator was happy that the device position was optimal on fluoroscopic and echocardiographic interrogation the release collar was opened and the release mechanism initiated (Figure 4F).

Conclusions

While the advent of TAVI has provided new promise for patients suffering from severe aortic stenosis there remain aspects of the procedure and complication profile that warrant improvement. The SADRA Lotus TAVI device is fully repositionable and retrievable even in its final fully expanded and fully functioning position. This allows accurate device placement and potentially reduces the risk of paravalvular aortic regurgitation, coronary artery occlusion and device embolization. Further to this the device remains highly efficacious with early device function during deployment and reduction in aortic valve gradients. Following the successful Reprise I feasibility study we await the results of the multinational Reprise II and Reprise III studies.

Riassunto

SADRA Lotus Valve System: una protesi a completa riposizionabilità e recuperabilità

L'impianto di valvole aortiche transcatetere (TAVI) è diventata l'opzione di trattamento preferenziale per pazienti affetti da stenosi aortica grave ad estremo rischio chirurgico e un'alternativa accettabile per la sostituzione chirurgica della valvola aortica in pazienti ad alto rischio. Nonostante la crescente quantità di prove a sostegno del TAVI, permangono alcune importanti limitazioni e complicazioni riconosciute. Il sistema della valvola SADRA Lotus è un dispositivo innovativo, in grado di consentire la completa riposizionabilità e recuperabilità, che può interessare alcune delle limitazioni di prima generazione.

Parole chiave: Valvola aortica - Valvola aortica, stenosi - Valvola cardiaca, protesi, impianto.

References

1. Kodali SK, Williams MR, Smith CR, Svensson LG, Webb JG, Makkar RR *et al.* Two-Year Outcomes after Transcatheter or Surgical Aortic-Valve Replacement. N Engl J Med 2012;366:1686-95.
2. Makkar RR, Fontana GP, Jilaihawi H, Kapadia S, Pichard AD, Douglas PS *et al.* Transcatheter Aortic-Valve Replacement for Inoperable Severe Aortic Stenosis. NEJM 2012;366:1696-704.
3. Iung B, Cachier A, Baron G, Messika-Zeitoun D, Delahaye F, Tornos P *et al.* Decision-making in Elderly Patients With Severe Aortic Stenosis: Why Are So Many Denied Surgery? Eur Heart J 2005;26:2714-20.
4. Cribier A, Eltchaninoff H, Bash A, Borenstein N, Tron C, Bauer F *et al.* Percutaneous transcatheter implantation of an aortic valve prosthesis for calcific aortic stenosis: first human case description. Circulation 2002;106:3006-8.
5. Tamburino C, Capodanno D, Ramondo A, Petronio AS, Ettori F, Santoro *et al.* Incidence and predictors of early and late mortality after transcatheter aortic valve implantation in 663 patients with severe aortic stenosis. Circulation 2011;123:299-308.
6. Lange R, Bleiziffer S, Mazzitelli D, Elhmidi Y, Opitz A, Krane M *et al.* Improvements in transcatheter aortic valve implantation outcomes in lower surgical risk patients: a glimpse into the future. J Am Coll Cardiol 2012;59:280-7.
7. Gilard M. French Aortic National CoreValve and Edwards Registry 2: FRANCE2. ESC 2011, Paris.
8. Linke A. ADVANCE CoreValve Registry 6-Month Data. ACC 2012 Scientific Sessions.
9. Buellesfeld L, Stortecky S, Heg D, Hausen S, Mueller R, Wenaweser P *et al.* Impact of permanent pacemaker implantation on clinical outcome among patients undergoing transcathter aortic valve implantation. J Am Coll Cardiol 2012;60:493-501.
10. Ghanem A, Muller A, Nähle CP, Kocurek J, Werner N, Hammerstingl C *et al.* Risk and Fate of Cerebral Embolism After Transfemoral Aortic Valve Implantation. A prospective Pilot Study With Diffusion-Weighted Magnetic Resonance Imaging. J Am Coll Cardiol 2010;55:1427-32.
11. Abdel-Wahab M, Zahn R, Horack M, Gerckens U, Schuler G, Sievert H *et al.* Aortic regurgitation after transcatheter aortic valve implantation: incidence and early outcome. Results from the German transcatheter aortic valve intervention registry. Heart 2011;97:899-906.
12. Piazza N, de J egere P, Schultz C, Becker AE, Serruys PW, Anderson RH. Anatomy of the aortic valvar complex and its implications for transcatheter implantation of the aortic valve. Circ Cardiovasc Intervent 2008;1:74-81.

13. Willson A, Webb J, LaBounty T, Achenbach S, Moss R, Wheeler M *et al.* 3-Dimensional Aortic Annular Assessment by Multidetector Computed Tomography Predicts Moderate or Severe Paravalvular Regurgitation After Transcatheter Aortic Valve Replacement: A Multicenter Retrospective Analysis. J Am Coll Cardiol 2012;59:1287-94.
14. Jilaihawi H, Kashif M, Fontana G, Furugen A, Shiota T, Friede G *et al.* Cross-sectional computed tomographic assessment improves accuracy of aortic annular sizing for transcatheter aortic valve replacement and reduces the incidence of paravalvular aortic regurgitation. J Am Coll Cardiol 2012;59:1275-86.
15. Mohammad A, Mohamed A, Björn S. Anatomic and procedural predictors of paravalvular aortic regurgitation after implantation of the medtronic corevalve bioprosthesis. J Am Coll Cardiol 2010;56:1623-9.
16. Webb J, Wood D. Current status of transcatheter aortic valve replacement. J Am Coll Cardiol 2012;60:483-92.
17. Meredith I. Repositionable percutaneous replacement of a stenotic aortic valve through implantation of the Lotus Valve System: Discharge/7-Day Outcomes in the REPRISE I Study. Paris Course on Revascularization. Paris, France; 2012.
18. Leon MB, Piazza N, Nikolsky E, Blackstone EH, Cutlip DE, Kappetein AP *et al.* Standardized endpoint definitions for Transcatheter Aortic Valve Implantation clinical trials: a consensus report from the Valve Academic Research Consortium. J Am Coll Cardiol 2011;57:253-69.

Received on October 2, 2012.
Accepted for publication on October 10, 2012.

Catheterization and Cardiovascular Interventions 83:831–835 (2014)

The Next Era of Transcatheter Aortic Valve Replacement: A Case Illustrating the Benefit of a Fully Re-positionable, Re-sheathable, and Retrievable Prosthesis

Robert Gooley,[1,2] MBBS (HONS), FRACP, Paul Antonis,[1,2] MBBS (HONS), FRACP, and Ian T Meredith,[1,2]* AM. MBBS (HONS), PhD, FRACP

While transcatheter aortic valve replacement (TAVR) is an accepted treatment modality in appropriately selected patients there remain modest complication rates. New TAVR devices, through novel design features, may overcome some of these complications. We present the first case of full re-sheathing and retrieval of a Lotus Valve to facilitate a change in prosthesis size.

Key words: percutaneous aortic valve replacement; SADRA Lotus; repositionable; resheathable; aortic valve stenosis; high surgical risk

INTRODUCTION

Transcatheter aortic valve replacement (TAVR) is an accepted treatment modality for patients with symptomatic severe aortic stenosis (AS) who are deemed to be at high or extreme surgical risk [1,2]. Despite excellent results there remain modest yet significant complication rates [1,2]. Some complications, such as paravalvular aortic regurgitation, conduction abnormalities, and device migration, are at least partially related to device positioning [3,4]. Accurate placement of current generation devices has been difficult and the ability to reposition deployed devices is limited.

The Lotus Valve System (Boston Scientific, MA) is uniquely designed to facilitate repositioning, re-sheathing, and retrieval even in the fully expanded and functioning position. The device is manually expanded by rotation of the delivery handle. This achieves controlled radial expansion as the prosthesis shortens to its final dimensions while remaining attached to the delivery system. Counter-rotation of the handle allows full retrieval and re-sheathing. We present the first reported case of the retrieval of a fully expanded TAVR device in order to facilitate change of prosthesis size.

CASE REPORT

Patient Presentation

An 88-year-old man with severe AS (NYHA class III) was referred for consideration of TAVR. He was deemed to be at high surgical risk by the Heart Team with moderately elevated surgical risk scores (Society of Thoracic Surgeons' mortality score 5.7% and EuroSCORE II 7.8%) and general frailty (hand grip 16.7 kg, 5 m gait speed 8.4 sec).

Device Selection

The Lotus Valve System is available in two sizes. The 23 mm prosthesis allows insertion in annuli between 19 and 23 mm if other aortic root measurements are congruent. It is delivered via an 18 Fr equivalent femoral sheath over a 260 cm wire. The 27 mm prosthesis is suitable for annuli between 23 and 27

[1]MonashHEART, Monash Health, Melbourne, Australia
[2]Monash Cardiovascular Research Centre, Department of Medicine, Monash University, Melbourne, Australia

Conflict of interest: Prof. Ian T. Meredith and Dr. P. Antonis receive consulting fees from Boston Scientific. Dr. R Gooley has no disclosures.

*Correspondence to: Professor Ian Meredith, Director, MonashHEART, Monash Medical Centre, Monash Health and Monash University, Melbourne, 246 Clayton Road, Clayton Vic 3168 Australia. Email: [redacted]

Additional Supporting Information may be found in the online version of this article.

Received 25 June 2013; Revision accepted 25 August 2013

DOI: 10.1002/ccd.25182
Published online 31 August 2013 in Wiley Online Library (wileyonlinelibrary.com)

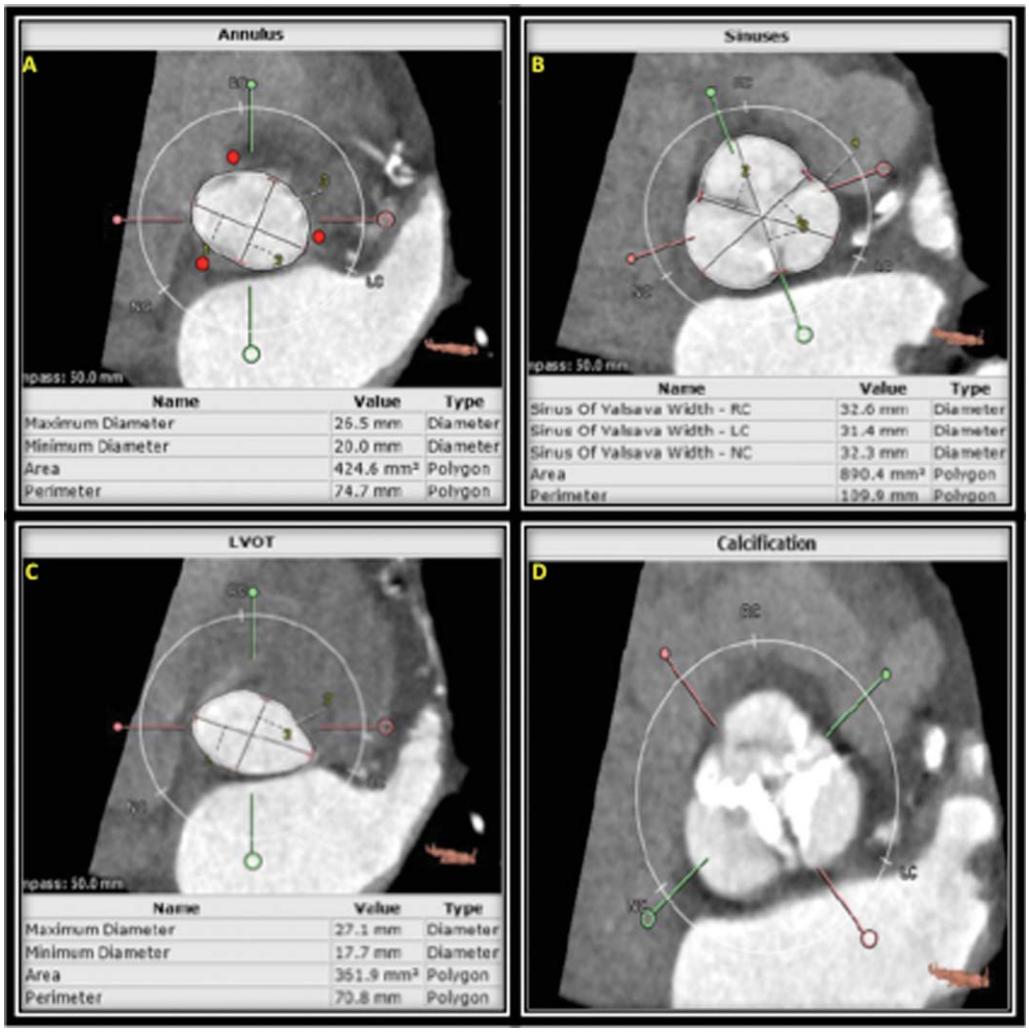

Fig. 1. MDCT assessment. A: Basal plane measurements. B: Sinus of valsalva measurements. C: LVOT measurements. D: Moderate calcification of the aortic valve leaflets.

mm. It is delivered via a 20 Fr equivalent femoral sheath over a 300 cm wire. In the locked position, the devices are 19 mm high and 23 or 27 mm wide.

Left and right heart catheterization, transthoracic echocardiogram (TTE), and multi-detector computed tomography (MDCT) imaging was performed prior to the procedure. MDCT was analyzed using the 3mensio Valves program (3mensio Medical Imaging, The Netherlands). The basal ring measured 20.0 mm × 26.5 mm, perimeter-derived diameter 23.7 mm, and area-derived diameter 23.2 mm (Fig. 1A). These measurements were on the border between suggested sizing criteria for the 23 mm and 27 mm Lotus Valve System. Due to the presence of moderate rather than large trans-sinus dimensions (Fig. 1B), smaller left ventricular outflow tract (LVOT) dimensions (Fig. 1C), and moderate leaflet calcification (Fig. 1D) a 23 mm Lotus Valve System was initially chosen.

Procedure

The procedure was performed under general anesthesia with transesophageal echocardiographic (TEE) assistance. The patient was pre-medicated with aspirin and clopidogrel. The left femoral artery was cannulated under fluoroscopic guidance and the right femoral ar- tery cannulated under angiographic guidance during contralateral contrast injection. A 9 Fr Prostar (Abbott, IL) was placed and the sheath upsized to the larger Lotus Introducer. The use of the larger introducer and 300 cm delivery wire allowed conversion to a 27 mm prosthesis if required. A balloon valvuloplasty was performed using a 20 mm × 40 mm Nucleus balloon (NuMED, Canada) during rapid ventricular pacing.

The 23 mm Lotus Valve prosthesis was gradually deployed under fluoroscopic, angiographic, and TEE guidance by rotating the delivery knob counter-

Published on behalf of The Society for Cardiovascular Angiography and Interventions (SCAI).

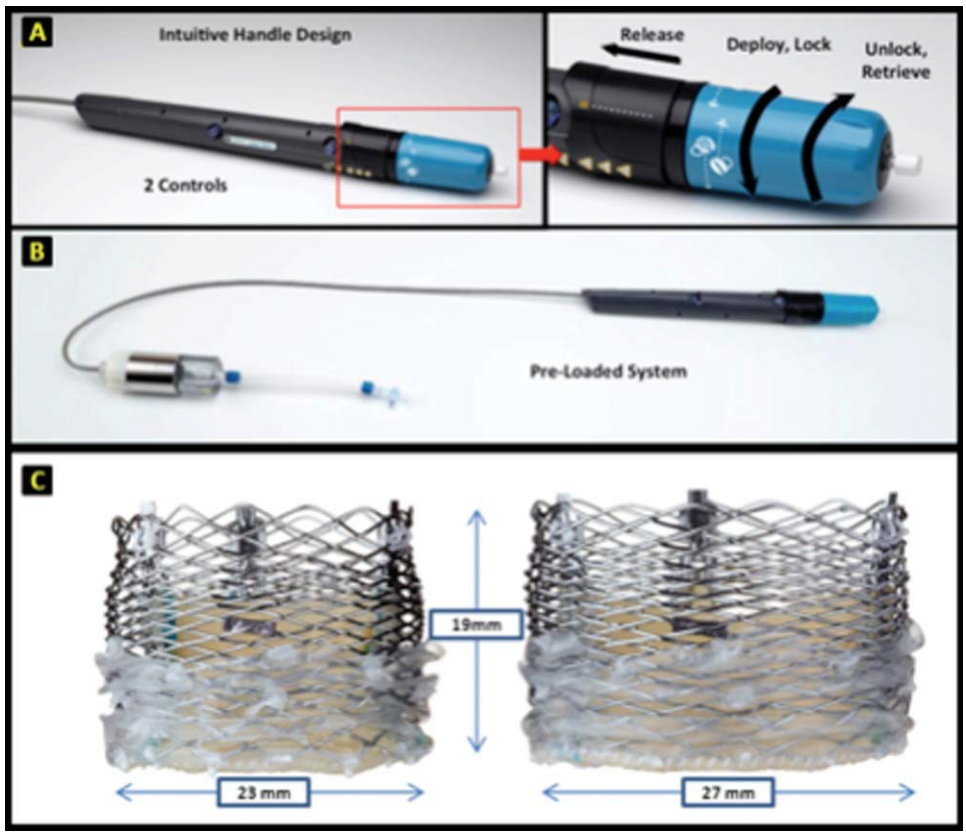

Fig. 2. The Lotus Valve System. A: Counter-clockwise rotation of the release handle deploys the valve while clock-wise rotation allows partial or full recapturing. Once the optimal device position is achieved the prosthesis is released by opening the release collar and rotating the mechanism. B: The prosthesis is pre-mounted. C: The fully deployed prosthesis has a height of 19 mm and external diameter of 23 or 27 mm.

clockwise (Fig. 2). Rapid ventricular pacing was not required. Despite adequate valve position at the annular level a waist had not formed on the valve and the TEE appearance was barrel-shaped rather than waisted (Fig. 3). Despite only trivial paravalvular aortic regurgita- tion, slight tension on the delivery catheter confirmed that the device was not stable within the annulus so it was decided to upsize to the 27 mm Lotus device.

The 27 mm device was prepared while the 23 mm device remained in situ so as to avoid a prolonged period of aortic regurgitation. The 23 mm device was then re-sheathed by clockwise rotation of the delivery knob (Fig. 2) and the delivery system removed. The 27 mm device was deployed with fluoroscopy showing a slight waist at the annular level and TEE confirming an excellent final position with no valvular or para- valvular aortic regurgitation.

Once device stability was confirmed and position deemed optimal the prosthesis was released by opening the release collar and clock-wise rotating the mechanism. The nose cone was re-captured in the descending aorta and the delivery catheter removed. Hemostasis was achieved by tying the Prostar sutures while a cross-over peripheral balloon was inflated in the right external iliac artery (see online supporting information for fluoroscopy of valve deployment and release).

The patient was discharged on day 4 without need for permanent pacing. TTE at discharge showed the prosthesis was functioning well with trivial aortic regurgitation, mean gradient 7 mm Hg and a valve area of 2 cm^2.

DISCUSSION

This case highlights a number of distinct advantages of the Lotus Valve System over current generation TAVR devices. The Lotus Valve is deployed by manual unsheathing, where rotation of the delivery handle allows the device to shorten along its locking mechanism while radially expanding. This facilitates accurate device placement and, when combined with early

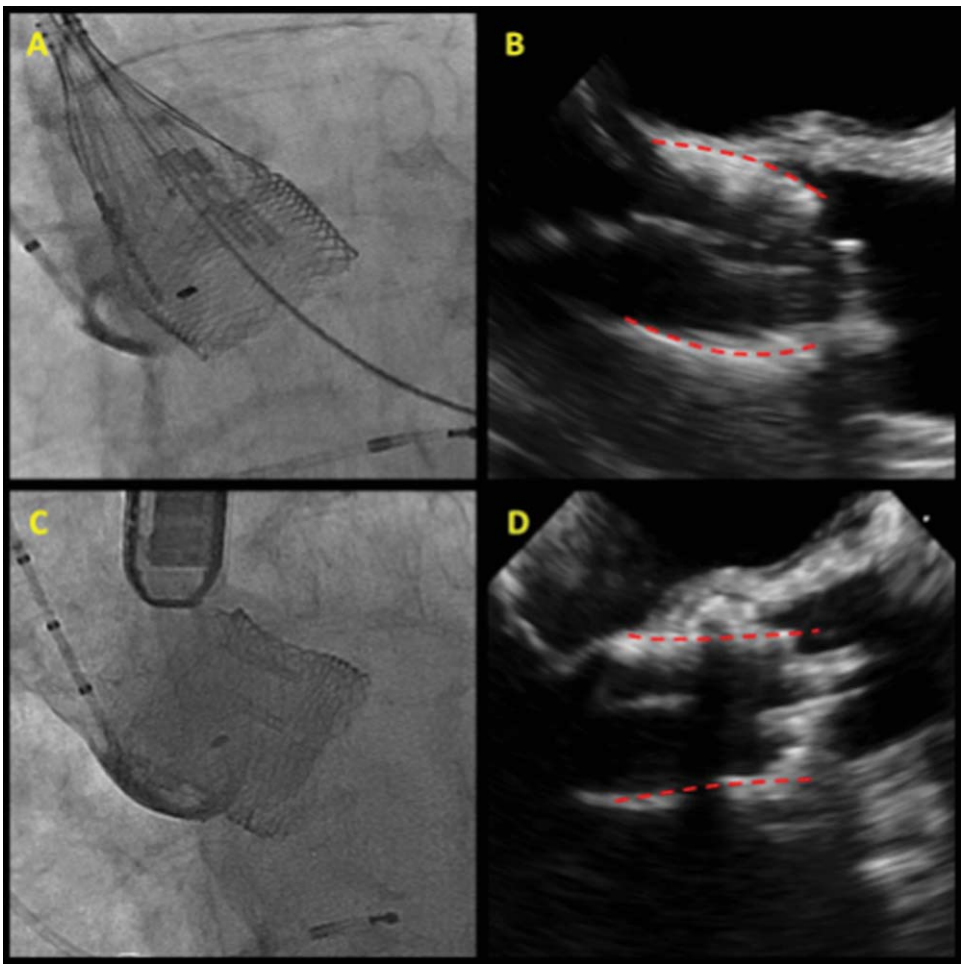

Fig. 3. Fluoroscopic and echocardiographic assessment. A: Fluoroscopy showing no waist on the locked 23 mm Lotus prosthesis. B: A similar barrel shaped appearance was seen on TEE. (Prosthesis highlighted by red dashed line). C: The locked 27 mm prosthesis showing a slight waist at the annular level. D: A similar appearance is seen on TEE. (Prosthesis highlighted by red dashed line).

prosthesis functioning, allows the process to be performed without rapid ventricular pacing.

If optimal positioning is not achieved initially the ability to partially or fully re-sheath the prosthesis allows it to be repositioned and exact placement accomplished. This mechanism also affords the ability to examine the device in its final functioning position prior to release.

TAVR prosthesis sizing is reliant on assessment of the aortic annulus together with the LVOT, aortic root, and coronary heights. Despite advancement in this area and provision of device specific sizing recommendations there remain cases such as this where best prosthesis size remains ambiguous on pre-procedural assessment. Until now placement of an undersized device risked embolization or significant aortic trauma from attempts to remove the expanded prosthesis while placement of a significantly oversized device risked device under-expansion or aortic annulus trauma. In cases where annular sizing does not clearly indicate one valve size, the Lotus Valve System allows the operator to position one valve, easily remove it in a fully sheathed state and change the prosthesis size if required.

Ongoing studies are required to determine whether the ability to accurately position the Lotus Valve prosthesis, and change size if required, leads to a reduction in recognized complications.

CONCLUSION

The Lotus Valve system is the first fully repositionable, re-sheathable, and retrievable TAVR system. It's unique design features are of particular use in cases where appropriate prosthesis size cannot be accurately determined on pre-procedural imaging.

Published on behalf of The Society for Cardiovascular Angiography and Interventions (SCAI).

ACKNOWLEDGMENTS

The authors would like to acknowledge the invaluable support of Dr. Siobhan Lockwood and Dr. Ted Feldman in the performance of this case.

REFERENCES

1. Kodali S, Williams M, Smith C, Svensson L, Webb J, Makkar R, Fontana G, Dewey T, Thourani V, Pichard A, Fischbein M, Szeto W, Lim S, Greason K, Teirstein P, Malaisrie S, Douglas P, Hahn R, Whisenant B, Zajarias A, Wang D, Akin J, Anderson W and Leon M, for the PARTNER Trial Investiga- tors. Two-year outcomes after transcatheter or surgical aortic- valve replacement. N Engl J Med 2012;366:1686 – 1695.
2. Makkar R, Fontana G, Jilaihawi H, Kapadia S, Pichard A, Douglas P, Thourani V, Babaliaros V, Webb J, Herrmann H, Bavaria J, Kodali S, Brown D, Bowers B, Dewey T, Svensson L, Tuzcu M, Moses J, Williams M, Siegel R, Akin J, Anderson W, Pocock S, Smith C, and Leon M, for the PART- NER Trial Investigators. Transcatheter aortic-valve replacement for inoperable severe aortic stenosis. N Engl J Med 2012;366: 1696 – 1704.
3. Sherif M, Abdel-Wahab M, Stecker B, Geist V, Richardt D, Felg R, Richardt G. Anatomic and procedural predictors of paravalvular aortic regurgitation after implantation of the Medtronic CoreValve bioprosthesis. J Am Coll Cardiol 2010;56: 1623 – 1629.
4. Tchetche D, Modine T, Farah B, Vahdat O, Sudre A, Koussa M, Lereun C, Nejjari M, Choby M, Rosencher J, Sorbets E, Fajadet J. Update on the need for a permanent pacemaker after transcatheter aortic valve implantation using the CoreValve Accutrak system. EuroIntervention 2012;8: 556 – 562.

The Interaction Between Psychological Health and Valvular Heart Disease: Pathogenesis, Clinical Course, and Treatment

Robert Gooley, Ian Meredith, and James Cameron

Contents

Introduction 2
Valvular Heart Disease 3
Definition 3
Prevalence 5
Etiology 5
Treatment and Prognosis 5
Prevalence of Depression and Anxiety in Patients with Valvular Heart Disease 6
The Etiology of Psychological Conditions in Patients with Valvular Heart Disease 8
The Role of Psychological Disturbance in the Etiology of Valvular Heart Disease 8
The Impact of Psychological Illness on Valvular Heart Disease and Its Treatment 9
Testing and Costs 10
Heart Failure 10
Pharmacological Treatment 11
Surgical Valve Repair or Replacement 12
The Impact of Valvular Heart Disease Treatment on Psychological Illness and Quality of Life 13
Pharmacological Treatment 13
Surgical Valve Repair or Replacement 14
Transcatheter Aortic Valve Intervention 14
Percutaneous Mitral Valve Repair 16
Practical Implications of Psychological Conditions and Valvular Heart Disease 17
Conclusion 17
References 19

R. Gooley (*) · I. Meredith · J. Cameron
MonashHeart, Monash Medical Centre, Monash Health, Clayton, VIC, Australia

Monash Cardiovascular Research Centre, Southern Clinical School, Monash University, Melbourne, VIC, Australia

M. Alvarenga, D. Byrne (eds.), *Handbook of Psychocardiology*,
DOI 10.1007/978-981-4560-53-5_24-1

Abstract

Valvular heart disease is an increasing health concern in most developed countries due to aging populations resulting in increased prevalence. While there is significant focus on ensuring timely medical care and developing less-invasive procedures to treat the functional valve lesions, there is often little attention given to the psychological impact of valvular heart disease.

Indeed while the impact of ischemic heart disease on psychological health and even the potential causative association between psychological illness and ischemic heart disease have been widely acknowledged, such a link is often not recognized in valvular heart disease. However among this unique population who are often older and frailer, assessment of psychological health may be even more important.

Keywords

Valvular heart disease · Aortic stenosis · Mitral regurgitation · Transcatheter aortic valve implantation · Percutaneous mitral valve repair · Surgical valve replacement

Introduction

Valvular heart disease encompasses numerous conditions that are united by dysfunction of one or more of the four cardiac valves: tricuspid, pulmonary, mitral, or aortic. In the majority of conditions, this is manifested as either obstruction to normal blood flow across the valve or regurgitation of blood in a retrograde direction. The clinical sequelae of a specific valve lesion are highly variable, from complete lack of symptoms to resultant heart failure and potentially death. The etiology of valvular dysfunction varies depending on the type of valve lesion, with the prevalence varying based on geographical location and age of the individual.

The aging population of most developed nations has resulted in an increased prevalence of valvular heart disease and resulted in a new health epidemic. In addition, treatment options are continually expanding, with the development of minimally invasive surgical and percutaneous valve repair and replacement techniques, leading to treatment of a cohort previously deemed inoperable due to age, frailty, or other comorbidities.

Like most chronic illnesses, patients with valvular heart disease experience a higher prevalence of psychological conditions including depression, anxiety, and personality disturbance. The significant impact these conditions have on patients' perceptions of their disease, treatment, and prognosis is often under-recognized.

This chapter will explore the interaction between psychological factors and valvular heart disease from etiology to treatment and to prognosis. We will also explore the psychological impact of new valvular heart disease treatment modalities compared to traditional approaches of care. The psychological aspects of valvular heart disease overlap with those of other chronic cardiac conditions such

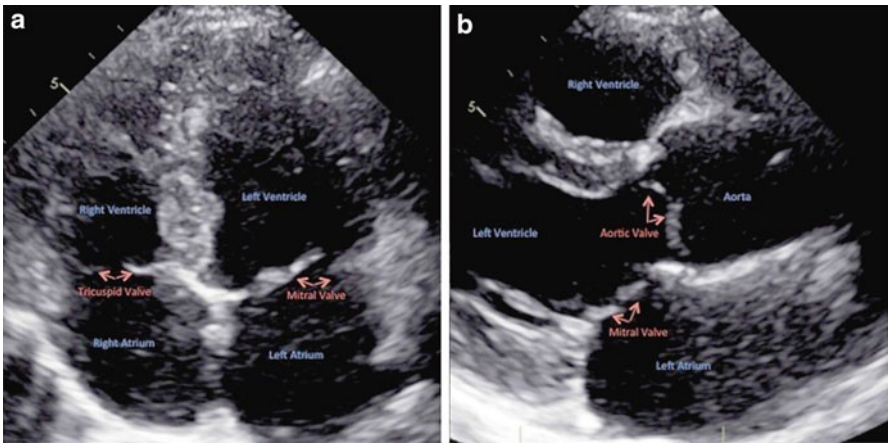

Fig. 1 Normal transthoracic echocardiographic images. (a) Apical four-chamber image demonstrating the mitral valve separating the left atrium and left ventricle and the tricuspid valve separating the right atrium and right ventricle. (b) Parasternal long-axis image demonstrating the mitral valve separating the left atrium and left ventricle and the aortic valve separating the left ventricle and aorta

as ischemic heart disease, heart failure, and cardiac transplantation. Where relevant the interaction and comparison with these conditions will be emphasized.

Valvular Heart Disease

Definition

The human heart contains four cardiac valves, composed of either two or three connective tissue leaflets. The valves separate the four cardiac chambers; the tricuspid valve is positioned between the right atrium and right ventricle, the pulmonary valve between the right ventricle and pulmonary artery, the mitral valve between the left atrium and left ventricle, and the aortic valve between the left ventricle and aorta (Fig. 1). In health, the valves facilitate unidirectional, antegrade flow of blood through the heart when a forward pressure differential forms and close to prevent regurgitation of blood when a negative forward pressure differential forms.

Valvular heart disease collectively refers to conditions that result in either obstruction to antegrade flow or regurgitation of blood through one or more of the cardiac valves. Valvular heart disease, therefore, encompasses a diverse number of conditions covering more than 25 International Classification of Disease (ICD-10) categories (World Health Organization 2010).

Table 1 Common etiologies of valvular defects

Aortic stenosis	Aortic regurgitation
Calcific degeneration	Acute
Bicuspid aortic valve	Infective endocarditis
Rheumatic heart disease	Trauma
	Aortic dissection
	Chronic
	Aortic root dilatation
	Idiopathic
	Hypertension
	Osteogenesis imperfecta
	Syphilitic aortitis
	Rheumatic heart disease
	Bicuspid aortic valve
	Connective tissue disease
Mitral stenosis	Mitral regurgitation
Rheumatic heart disease	Acute
Calcific degeneration	Infective endocarditis
	Ruptured papillary muscle
	Chronic
	Mitral valve prolapse
	Myxomatous degeneration
	Left ventricular remodeling
	Ischemic
	Dilated cardiomyopathy
	Rheumatic heart disease
	Marfan's syndrome
Pulmonary stenosis	Pulmonary regurgitation
Congenital heart disease	Pulmonary hypertension
Rheumatic heart disease	Congenital heart disease
Carcinoid tumor	
Tricuspid stenosis	Tricuspid regurgitation
Rheumatic heart disease	Acute
Right atrial myxoma	Infective endocarditis
Carcinoid syndrome	Chronic
Connective tissue disease	Right ventricular dilatation
Congenital heart disease	LV dysfunction
	RV ischemia
	Cor pulmonale
	Ebstein's anomaly
	Carcinoid
	Myxomatous degeneration

Prevalence

Valvular heart disease prevalence increases with age, affecting approximately 2.5 % of the population with prevalence increasing from <1 % among people aged less than 45 years to over 12 % in people aged over 75 years (Nkomo et al. 2006). The Australian population is aging with the proportion of people aged over 65 years projected to rise from 14 % in 2012 to approximately 20 % in 2031 and 25 % in 2061 (Australian Bureau of Statistics 2013). Valvular heart disease is therefore set to become a major health epidemic in Australia with similar patterns in most developing countries, associated with substantial costs to the health service and significant impact on patients' quality of life.

Etiology

The etiology of each valve condition differs; however common causes of regurgitation include rheumatic valve disease, ischemic heart disease, connective tissue conditions, congenitally abnormal valves, and endocarditis, while causes of valve stenosis include age-related calcific degeneration, rheumatic valve disease, and congenitally abnormal valve architecture. A more detailed list of potential etiologies for common valve lesions is presented in Table 1.

Even within a single country, there is variability in the rates of valvular heart disease and also the predominant etiology. While rheumatic heart disease is now an uncommon cause of valvular dysfunction in most western countries, within Australia there remains a significantly higher incidence among the indigenous Aboriginal population. Within Australia's Northern Territory, 93 % of patients with rheumatic heart disease are indigenous with prevalence among indigenous women of 3.2 % and indigenous men of 1.7 % compared to 0.2 % and 0.1 % for their respective nonindigenous contemporaries (Australian Institute of Health and Welfare 2011).

Treatment and Prognosis

The majority of people with mild or moderate valve dysfunction remain in a latent phase without any subjective or objective symptoms. This asymptomatic period has a variable duration but generally lasts decades before disease severity progresses and symptoms are identified. Often no specific treatment is required in this phase of valvular heart disease.

Guidelines recommend that patients identified with valvular heart disease be monitored for development of symptoms and with transthoracic echocardiography to allow early identification of negative compensatory cardiac changes such as chamber dilatation (Nishimura et al. 2014). This watchful waiting approach may lead to a prolonged latent period with no symptom burden but significant anticipation driven by awareness of the underlying condition and the need for

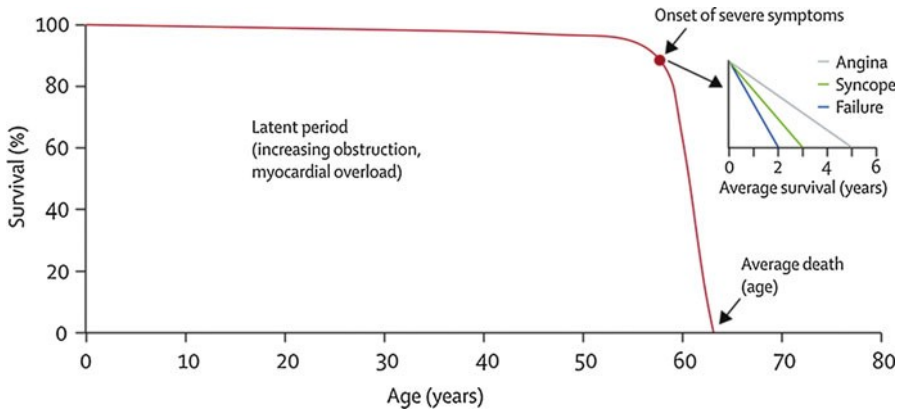

Fig. 2 The natural history of aortic stenosis includes a long latent period prior to the development of symptoms. After symptom development there is a rapid decline in survival

regular surveillance investigations. Some people will never move beyond this latent period due either to lack of disease progression or because other medical illnesses intervene fi Such anticipation may, however, be associated with psychological impact such as development of anxiety or depression in susceptible patients.

While the asymptomatic disease phase may last for a number of years or even decades, progression to severe dysfunction generally heralds the development of heart failure symptoms and associated morbidity and mortality (Fig. 2). Mild symptoms such as dyspnea or fatigue may be countered by commencement of medication, particularly diuretic therapy. The onset of symptoms together with identification of severe valvular dysfunction on echocardiography, however, warrants consideration of definitive treatment. This has traditionally centered on open-heart surgery with repair or replacement of the affected valve. Given the older demographic, up to 30 % of patients with symptomatic severe valvular heart disease have previously been denied or refused surgery (Iung et al. 2005). This has lead to the development of newer, less-invasive catheter-based treatments that have proven, in appropriate patients, to be as efficacious as open surgery. The advent of these catheter-based therapies has opened treatment to a group of patients previously denied operative management due to real or perceived risks by the patient or physician.

Prevalence of Depression and Anxiety in Patients with Valvular Heart Disease

It is generally acknowledged that patients with valvular heart disease, like other chronic illnesses, have a high rate of psychological conditions such as depression and anxiety. The actual prevalence of depression and anxiety, however, has not

been widely studied. The rate of depression in patients with cardiovascular disease, a condition that shares some symptoms and treatment modalities with valvular heart disease, approaches 15 % (Colquhoun et al. 2013), while rates of 20 – 30 % (Rumsfeld et al. 2003; Rutledge et al. 2006; Sullivan et al. 2004) have been reported among patients with chronic heart failure, a condition that is a common sequelae of valvular heart disease. Among the limited published data, the reported rate of depression in patients with valvular heart disease has reached 80 % (Carney et al. 1990).

The significant variability in reported prevalence of psychological disturbance in valvular heart disease is likely multifactorial. Existing studies are generally small and potentially underpowered to give a true prevalence rate in the general valvular heart disease population. Populations studied can also vary significantly, from relatively asymptomatic patients in the community to hospitalized patients with end-stage heart failure. Perhaps one of the greatest limitations to determining true prevalence of psychological disturbance among people with valvular heart disease is the lack of consistent definitions of depression, anxiety, and personality disorder together with variable tools employed for disease detection. While the *Diagnostic and Statistical Manual of Mental Disorders* is used to formally diagnose these conditions in clinical practice, most research studies rely on simpler and potentially less accurate means of detection. Some studies rely on self-diagnosis and reporting of symptoms; others use various standardized questionnaires or scoring symptoms, while only a few utilize formal psychological assessment by a trained professional.

The significant degree of variability in detection was eloquently demonstrated in a study examining a cohort of elderly women with mitral stenosis. When the cohort was assessed using the Hospital Anxiety and Depression Scale (HADS), both anxiety and depression were significantly higher than age-matched controls. However, administration of the Short Form (36) Health Survey in the same population did not elicit any difference between the groups in mental health scores (Shuldham et al. 2001). This suggests that while individual studies may be able to show an increased rate of psychological disturbance between cohorts, results are often not comparable between studies.

Despite high prevalence of psychological disturbance among people with valvular heart disease, the issue receives little to no attention in published guidelines (Nishimura et al. 2014; Vahanian et al. 2012). While national guidelines rely heavily on a sufficient evidence base prior to making formal recommendations, the omission of the significant psychological/cardiac interplay fails to address this important aspect of holistic care. The European Society of Cardiology guidelines, in only one paragraph regarding assessment of comorbidities, lists frequently encountered physical conditions but no psychological conditions. It briefly states that "validated scores enable the assessment of cognitive and functional capacities which have important prognostic implications in the elderly" (Vahanian et al. 2012). The guidelines do not state which validated scores should be used, and indeed it is unclear if they are instead focused more on the detection of cognitive impairment in the elderly rather than psychological illness in the entire

cohort. Unfortunately, this lack of guidance regarding the need for screening for psychological symptoms, the optimal screening tool, and the best treatment of psychological disorders when present is likely to contribute further to lack of detection, lack of understanding, and suboptimal care within both the research and clinical environments.

The Etiology of Psychological Conditions in Patients with Valvular Heart Disease

While the association between psychological conditions and valvular heart disease is generally accepted, a causal relationship is far more difficult to establish and prove. Valvular heart disease is a chronic illness that is associated with significant morbidity and mortality, and there is an extensive evidence pool that depressive and anxiety disorders are more common in patients with chronic illnesses (Katon et al. 2007). The health impact of a chronic illness often leads to reactive depressive disorders with an increasing prevalence as the severity of the underlying medical illness worsens (Cassem 1995). If the patient is unable to employ appropriate adaptive responses, these reactive disorders can develop into major depressive or anxiety disorders.

Further pathophysiological mechanisms to explain the development of psychological conditions in the setting of valvular heart disease have been postulated. Left-sided annular and valvular calcification is associated with increased subclinical cerebral infarcts identified on magnetic resonance imaging (Rodriguez et al. 2011). It has been demonstrated that up to half of presenile major depression may be associated with similar silent cerebral infarction (Fujikawa et al. 1993). While this offers a potential mechanistic association between valvular heart disease and higher rates of psychological disturbance, reactive psychological disturbance remains a more feasible explanation in the majority of cases.

The Role of Psychological Disturbance in the Etiology of Valvular Heart Disease

While it is generally accepted that the presence of a chronic illness can lead to reactive psychological conditions, a number of hypotheses exist regarding a pathobiological role for psychological conditions exacerbating or contributing to the development of cardiac disease. The majority of these theories were developed in populations with chronic ischemic heart disease but may also hold in association with valvular heart disease.

Major depressive disorder has been shown to result in alteration of the neurohormonal milieu including up-titration of a number of pro-inflammatory cytokines including TNF-alpha, IL-10, IFN-gamma, BNP, and ADMA (Anisman and Merali 2002; Zorrilla et al. 2001). This has led to the suggestion that depression may be considered a low-grade chronic inflammatory condition. These inflammatory

cytokines through direct pro-inflammatory action on the endothelium and by downregulation of anti-inflammatory/vasodilatory nitric oxide (NO) may result in vascular inflammation, attraction of inflammatory cells, and hence accelerated atherosclerosis (Empana et al. 2005). While a similar relationship has not been proven in the setting of valvular heart disease, histopathological studies of aortic stenosis have found an increase in inflammatory cell infiltrate suggesting that there may be at least an inflammatory component to this disease (Wallby et al. 2013). It could, therefore, be hypothesized that these same pro-inflammatory cytokines that are upregulated in the setting of major depressive disorder could result in valve leaflet inflammation and calcific degeneration.

An association has been demonstrated between recurrent major depression in middle-aged women and development of coronary and aortic calcification. One study looking at calcification in 200 healthy middle-aged women found that a history of recurrent major depression was associated with an odds ratio of 3.39 (95 % confidence interval 1.34 – 8.63) for high aortic calcification compared to those with no history of depression or only an isolated episode (Agatisa et al. 2005). While age-related valvular degeneration often involves calcification of the valvular apparatus, this study did not extend to investigation of valvular calcification. Other studies have, however, shown that the presence of coronary and/or aortic calcification correlates with the presence of aortic valve and mitral annular calcification (Jeon et al. 2001). Further work is required to directly assess the role of depression and other psychological conditions, in the pathogenesis of valvular calcification and dysfunction and whether the previously described inflammatory-mediated hypothesis is the causative process.

Even if depression and anxiety are proven not to be causative in the development of valvular heart disease, it is highly likely that their presence alters patients' perceptions of their valvular disease and symptom burden and potentially alters outcome. Psychological conditions may result in increased awareness of symptoms compared to age-matched controls when corrected for objective means of disease severity assessment (Katon et al. 2001). Depression and anxiety may also be associated with upregulation of the autonomic nervous system resulting in a fight or flight response with somatic symptoms such as increased muscle tension, palpitations, perspiration, and dyspnea.

The Impact of Psychological Illness on Valvular Heart Disease and Its Treatment

The presence of psychological stressors negatively impact on the clinical outcomes of patients with most chronic illnesses and valvular heart disease is no exception. Conditions such as depression, anxiety, and personality disorder can affect compliance with recommended therapy, physician's judgment in offering treatment, and potentially the efficacy of treatment.

Testing and Costs

The presence of a psychological condition can result in increased awareness of symptoms and potentially over-reporting of disease severity. This may result in patients being subjected to an increased number of tests or at an increased frequency resulting in costs of treatment in some cases 50 % higher than matched patients without comorbid psychological illness (Katon 2003). Cardiac societies in a number of countries have established screening guidelines for patients with documented valvular heart disease. These guidelines are designed to identify changes in disease severity or unfavorable compensatory changes early yet not overburden the patient or health system with unnecessarily frequent testing.

The finding of increased health costs in the setting of comorbid depression and chronic illness has been demonstrated in a number of illnesses. In a population of patients with diabetes mellitus in the United States of America, the presence of major depression, as assessed by the nine-item PHQ survey, was associated with a 70 % increase in healthcare costs (Simon et al. 2005). While the presence of depression can increase the costs of chronic illness care provision, there is also evidence that appropriate recognition and treatment of depression can reduce costs. One randomized study, also in a diabetic cohort with depression, found that implementation of case-managed depression intervention resulted in a net cost saving over 2 years despite an initial additional cost for the mental health treatment (Katon et al. 2006). Given the significant health costs encountered in a valvular heart disease cohort during all phases of screening, surveillance, and treatment, potential cost savings are significant.

Heart Failure

Progression in the severity of valvular heart disease can result in complications such as heart failure, arrhythmia, and stroke, each of which has psychological

Table 2 The New York Heart Association (NYHA) classification of heart failure symptoms

NHYA class	Definition
I	Documented cardiac disease without symptoms or physical limitation. Ordinary physical activity does not cause fatigue, palpitation, dyspnea, or angina
II	Documented cardiac disease resulting in slight limitation of physical activity. Ordinary physical activity results in fatigue, dyspnea, palpitation, or angina. No symptoms are present at rest
III	Documented cardiac disease resulting in marked limitation of physical activity. Less than ordinary activity causes fatigue, palpitation, dyspnea, or angina. No symptoms are present at rest
IV	Documented cardiac disease resulting in inability to perform physical activity without symptoms. Symptoms may also be present at rest

implications for patients. Heart failure is the most common clinical sequelae of valvular heart disease and occurs when the cardiac output is not sufficient to meet the metabolic demands of the organs despite normal filling pressures. The symptoms of heart failure include dyspnea, fatigue, lethargy, and peripheral edema. The presence of heart failure is associated with increased rates of depression with reported prevalence of 11 – 58 % (Koenig 1998; Havranek et al. 1999; Turvey et al. 2002) and anxiety with reported prevalence ranging from 29 % to 45 % (Friedmann et al. 2006; Jiang et al. 2004). Despite the high rate of comorbid psychological disturbance in the heart failure population, there is evidence that early intervention can ameliorate this. The presence of strong social supports and family relationships may, however, counter the onset of depression (Friedmann et al. 2006; Scherer et al. 2007).

There is evidence that as heart failure severity worsens, as measured by the New York Heart Association class, the incidence of depression increases (Scherer et al. 2007). The New York Heart Association classification grades heart failure severity based on the degree of functional limitation due to heart failure symptoms (Table 2). However such results may be confounded by over-reporting of symptoms in patients with depression. Although not consistently demonstrated, the majority of evidence suggests that the presence of a depressive disorder adversely affects heart failure prognosis, independent of other measures of disease severity (Faris et al. 2002; Jiang et al. 2001; Murberg et al. 1999). One such study, a retrospective analysis of 396 patients hospitalized with nonischemic heart failure, identified those with a documented history of depression. When adjusted for conflicting variables, a history of depression predicted mortality with a hazard ratio of 3.0 (CI 1.4 – 6.6, $p = 0.004$) (Faris et al. 2002). A similar association has been demonstrated in patients with stable heart failure symptoms not necessitating admission. A population of 119 stable Norwegian outpatients attending a cardiology clinic were enrolled. These patients were assessed for depressive symptoms using the Zung Depression Scale (Zung 1965). Depressed mood was found to inversely predict 2-year survival with an almost doubling of the hazard ratio (HR = 1.9, $p = 0.002$) (Murberg et al. 1999).

Pharmacological Treatment

Medical management remains the mainstay of treatment for patients with valvular heart disease during most phases of care as opposed to surgical or percutaneous intervention, which are generally only required in symptomatic severe dysfunction. In the setting of valvular dysfunction, medication may be used to prevent the development of, or mitigate the clinical effect of, valvular heart disease symptoms. In patients who have undergone percutaneous or operative intervention, medication is even more important in preventing complications such as prosthesis thrombosis or systemic thromboembolism.

Comorbid depression has been shown to correlate with reduced medication compliance in a number of chronic illness settings. A meta-analysis looking at

this issue analyzed 31 studies with chronic illnesses including heart failure, coronary artery disease, hypertension, dyslipidemia, and diabetes. The presence of depression in these populations was associated with 1.76 times the odds of medication noncompliance. The means of measuring noncompliance in the included studies varied from self-reporting to analysis of pharmacy records and electronic medication container measurements (Grenard et al. 2011). Another meta-analysis looked for association between not only depression but also anxiety and medication noncompliance. Again depression was associated with increased noncompliance (OR 3.03, CI 1.95 – 4.89). The combined results of 13 studies assessing anxiety, however, did not demonstrate a significant increase in noncompliance (DiMatteo et al. 2000). Medication noncompliance may lead to worsening of symptoms which, given that symptom burden has been shown to correlate with depression, may further exacerbate underlying psychological conditions creating a vicious circle of deteriorating physical and mental health.

Once depression is diagnosed, patients may be commenced on antidepressant medication. While no large-scale trials have assessed the safety and efficacy of antidepressants in a valvular heart disease population, they have been widely used without significant issue. Despite some concern regarding a possible link between the use of serotonin selective reuptake inhibitors (SSRIs) and valvular heart disease, this has not been proven in clinical or research use. Such concerns stemmed from previously used weight loss agents, particularly fenfluramine, which substantially raised plasma levels of serotonin as well as possessing agonistic properties at the 5-HT_{2B} receptor resulting in fibrotic valvulopathy. SSRI agents do not result in such significant serotonin levels and lack the direct receptor activity that was the likely predominant mechanism of fenfluramine-induced valvulopathy. While no firm recommendation can be made regarding the optimal class of antidepressant for use in valvular heart disease, small studies have suggested that SSRIs have a lower side effect profile than tricyclic antidepressants in other cardiac conditions such as ischemic heart disease and heart failure.

Surgical Valve Repair or Replacement

Up to 30 % of elderly patients with severe aortic stenosis are denied surgical treatment due to physician or patient preference (Iung et al. 2005). The rationale for physician refusal in this population has been studied and in most cases is multifactorial although comorbidities such as depression contribute to each individual' s global perceived risk. Denial of definitive operative or percutaneous treatment leaves patients at the mercy of the natural history of the underlying valvular condition (Fig. 2), which includes worsening physical health and hence often worsening psychological health. In the case of aortic stenosis, the natural disease history includes a 50 % mortality rate of over 2 years in patients with severe stenosis and symptoms. Failure to identify underlying psychological conditions and treat them appropriately may, therefore, lead to denial of lifesaving treatments.

While some patients with existing depressive illness may be unfairly denied definitive treatment, the presence of depression adversely affects patients who do undergo surgery. One study comparing patients with baseline depression to those without prior to coronary artery bypass grafting found that it was independently associated with increased mortality with an adjusted hazard ratio of 2.4 (Blumenthal et al. 2003).

The Impact of Valvular Heart Disease Treatment on Psychological Illness and Quality of Life

While the presence of psychological illness may affect treatment offered or the efficacy of treatment for valvular heart disease, the effect of valvular heart disease interventions on patients' psychological health must also be considered. Treatment of advanced valvular heart disease often involves invasive surgical or complex percutaneous interventions. Even among patients without pre-existing psychological illness, such major events may result in new onset depression or anxiety. In patients with existing depression or anxiety, the effect of invasive treatment on the underlying psychological illness is variable. The advent of percutaneous valve interventions has led to treatment of an older, frailer, and generally more physically unwell cohort whose psychological response to valvular treatment may differ from patients undergoing traditional operative valve replacement and from reported community cohorts with valvular heart disease.

Pharmacological Treatment

Inhibition of beta-adrenoreceptor activation with the use of beta-blockers is commonly used in the treatment of valvular heart disease conditions. Beta-blockers have traditionally been thought to increase the incidence of depression, along with other side effects including fatigue and sexual dysfunction. A recently published meta-analysis of 15 randomized trials, however, found no significant difference in the incidence of depression in patients on beta-blockers compared to placebo and only a small increase in the rate of fatigue and sexual dysfunction (Ko et al. 2002).

Angiotensin-converting enzyme inhibitors (ACEIs) are similarly used in valvular heart disease for their beneficial effect in reducing cardiac afterload and reducing negative ventricular remodeling. One study using a prescription sequence symmetry analysis suggested that ACEI may increase the incidence of depression with a hazard ratio of 1.29 (1.08 – 1.56) (Hallas 1996). This form of analysis compares the rate of people commencing an ACEI prior to an antidepressant with those who commence an antidepressant prior to an ACEI. Of course such an analysis has many intrinsic flaws so it should be seen only as hypothesis generation with a need for formal studies.

Surgical Valve Repair or Replacement

Definitive management of valvular heart disease by surgical intervention is often required once disease severity worsens and symptoms develop. Surgical procedures can vary from minimally invasive thoracoscopic-guided intervention to open sternotomy and from repair of native valves to replacement with bioprosthetic or mechanical devices.

The incidence of anxiety and depression as assessed by the HADS score is high following cardiac surgery with reported rates of 16 % and 20 %, respectively (Okamoto et al. 2013). These high rates of psychological illness are important as the presence of psychological ill health (Zipfel et al. 2002) or significant social isolation (Oxman et al. 1995) may lead to a worse surgical outcome and recovery. Patients who develop worsening depressive symptoms within 2 months of cardiac surgery have a lower reported quality of life at 6 months postoperation (Goyal et al. 2005).

Despite high rates of depression and anxiety following cardiac surgery, among a more select patient population undergoing cardiac transplantation, it has been demonstrated that psychological preparation leads to an increased use of more productive, active problem-focused coping mechanisms rather than emotion-focused coping mechanisms (Pfeifer et al. 2013). The use of such preemptive strategies may reduce the rates of depression seen and hence improve postoperative recovery and survival. It is likely that similar psychological preparation would be beneficial prior to other cardiothoracic surgical procedures and potentially newer transcatheter procedures.

While it remains important to identify and treat new onset depression and anxiety following cardiac surgery and transplantation, the majority of patients note an improved quality of life (Rimington et al. 2010). In one such study, the overall improvement in mental health outcomes was actually greater than self-reported improvement in physical quality of life. This same study identified baseline depression and mental health illness as predictors of poor mental health quality of life at 1 year while advanced age appeared to be protective (Rimington et al. 2010).

Transcatheter Aortic Valve Intervention

Transcatheter aortic valve implantation (TAVI) or transcatheter aortic valve replacement (TAVR) was developed as a minimally invasive method of replacing the aortic valve in high-surgical-risk patients. The first case was performed in 2002 (Cribier et al. 2002) with subsequent rapid adoption of the technology. It is now estimated that more than 100,000 procedures have been performed globally with a number of competing devices now available. The replacement valve is inserted in a constrained form via a delivery catheter through either the femoral artery, alternate peripheral vessel, or in some cases a minimal surgical approach allowing access to the ventricular apex or the ascending aorta. The constrained valve is positioned

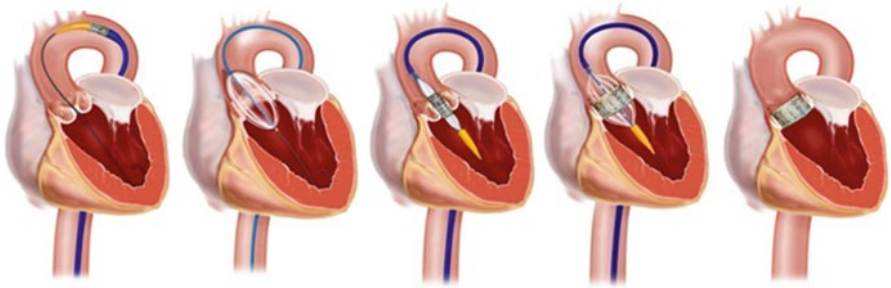

Fig. 3 Transcatheter aortic valves are delivered in a constrained form to the native aortic valve. The valve frame is then expanded by balloon, self-expansion, or mechanical expansion, exposing the new tissue leaflets within the frame and displacing the native leaflets into the sinuses of Valsalva

across the native valve and expanded. This displaces the native valve leaflets between the valve frame and the sinuses of Valsalva while new tissue leaflets sutured to the valve frame begin to function (Fig. 3). This percutaneous approach negates the need for a midline sternotomy, reduces risk, and hence hastens recovery.

TAVI, while less invasive than open surgery, has modest yet significant complication rates that may directly or indirectly impact on patients' psychological well-being. The TAVI procedure often involves a balloon valvuloplasty followed by passage of a delivery catheter across the aortic arch to the native aortic valve. Manipulating the native aortic valve and maneuvering the delivery catheter through an often-diseased aorta may result in embolization of atherosclerotic and/or calcific debris. This has been demonstrated in clinical trials where the rate of clinically detected stroke has been reported to be between 2 % and 5 %. The rate of magnetic resonance (MR) detected cerebral lesions, however, is much higher at 60 – 100 % (Ghanem et al. 2010, 2013; Kahlert et al. 2010). The majority of MR-detected lesions are randomly distributed throughout the subcortex. While this has led to the assertion that the majority of new cerebral lesions do not result in clinical sequelae, it is highly likely that the means of symptom detection used in published trials as well as in clinical practice are flawed and inadequate. Commonly used assessments vary but may include patient reports of symptoms, non-neurologist physical assessments, or global assessment tools such as the Modified Rankin or NIH Stroke Scale. Subtle neurocognitive and behavioral changes are likely to be missed in such global cognitive assessments (Barber et al. 2008). Nonspecialist review in such situations is likely to focus on the presence of new gross sensory or motor deficits rather than mild psychological disturbance, which may also be a clinical consequence of stroke.

While the rate of new onset psychological disturbance due to procedural complications may be under-recognized, the majority of studies have shown that

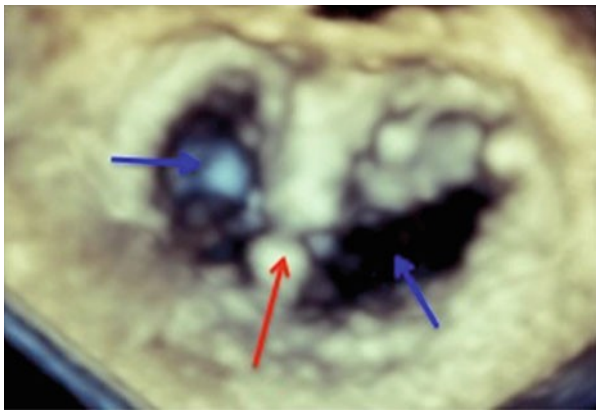

Fig. 4 Three-dimensional echocardiographic image of the mitral valve following deployment of a MitraClip. The MitraClip (*red arrow*) approximates the edge of the two mitral valve leaflets leaving a double-orifice mitral valve (*blue arrows*)

patients undergoing TAVI have an improvement in quality of life, including mental health scores (Ussia et al. 2009; Kala et al. 2013). In some studies the improvement in self-reported quality of mental health was greater than that in physical quality of life. These improvements in mental health correlate with functional improvement and reduction in cardiovascular symptoms as measured by the New York Heart Association score. Unfortunately, the majority of these studies have relied on participants completing self-assessment forms such as the Medical Outcomes Trust Short Form 12 (Ware et al. 1996), Medical Outcomes Trust Short Form 36 (Ware et al. 1993), or EuroQol EQ-5D (Rabin and de Charro 2001). With reported response rates of 73 – 77 %, this opens such means of detection to responder bias and hence may under-detect psychological and mental health disturbance.

Percutaneous Mitral Valve Repair

Similar to the advent of TAVI, the need for percutaneous mitral valve repair has been identified as a preferable treatment modality among a cohort of patients who are highly symptomatic due to severe mitral regurgitation yet are at high or extreme operative risk. The MitraClip (Abbott Vascular, IL, USA) device functions by clipping the leading edge of the anterior and posterior mitral leaflets together to form a double-orifice valve (Fig. 4). Approximating the two leaflets in this manner reduces the degree of mitral regurgitation in a similar mechanism to the surgical Alfieri (or edge-to-edge) repair.

The MitraClip device is inserted via the femoral vein with a transseptal puncture performed to gain access to the left atrium. The MitraClip entered clinical practice after TAVI and as such the body of evidence regarding its effect on psychological health is limited. In one large reported cohort of 127 patients, however, it was demonstrated that the SF36 quality of life scores improved significantly post

procedure. This improvement was seen in both the physical and mental component SF36 summary scores (Lim et al. 2013). To date no published studies have looked at the rate of subclinical stroke by routine cerebral imaging.

Practical Implications of Psychological Conditions and Valvular Heart Disease

With the increasing burden of valvular heart disease on the health service and on patients' quality of life, most clinicians, not only cardiologists but also other medical professions including psychologists, psychiatrists, and allied health providers, will encounter affected patients. The role of psychological conditions that patients experience during all stages of valvular heart disease is probably grossly under-recognized. Prompt diagnosis and treatment of depression, anxiety, and/or personality disorders may result in reduction of somatic symptom burden, increased efficacy of treatment, and improved rapid recovery following intervention. With the advent of new technologies opening treatment to a new, potentially more high-risk cohort, the importance of multidisciplinary care is imperative and now well recognized. Within most jurisdictions the "Heart Team" has been adopted for the care of patients in whom TAVI has been considered and, however, is often limited in its composition to include only cardiologists, cardiothoracic surgeons, anesthetists, and primary care physicians. While limited in the diversity of healthcare providers, such Heart Teams are in line with current societal guidelines with the current 2014 American Heart Association/American College of Cardiology guidelines stating the importance of the Heart Team, in particular to decisions regarding TAVI, but mention only the need to include professionals with expertise in valvular heart disease, cardiac imaging, interventional cardiology, cardiac anesthesia, and cardiac surgery (Nishimura et al. 2014). Given the importance of psychological health and early detection of depression or anxiety, thought should be given to expanding this team to include psychologists and/or psychiatrists while ensuring that the "Heart Team" is involved in most patients with valvular heart disease, not just those undergoing transcatheter procedures (Fig. 5). The current European Society of Cardiology guidelines fail to mention the importance of a more diverse Heart Team, stating only that the Heart Team should include cardiologists and cardiac surgeons and other specialists if necessary (Vahanian et al. 2012). It could be argued that recognizing when other specialists "are necessary" is unlikely to occur if appropriate specialists are not routinely involved to detect the patient need.

Conclusion

There is no doubt that valvular heart disease is a health epidemic predominantly due to the aging population of most western societies. At the same time, treatment options are growing, leading to a larger population of treated patients.

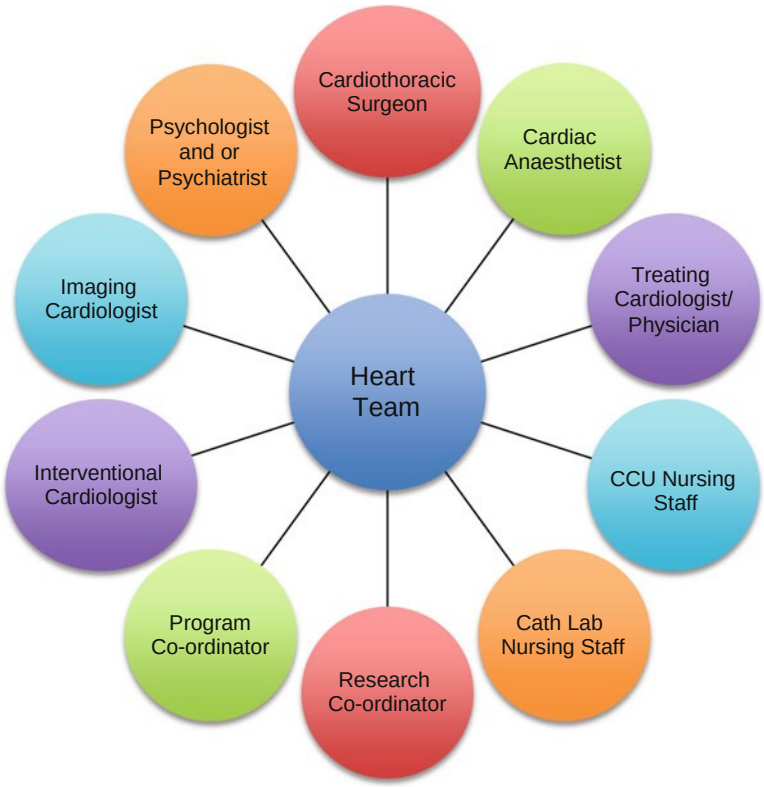

Fig. 5 The Heart Team concept was formally introduced with the advent of TAVI though used prior to this in many institutions. The inclusion of a trained psychologist or psychiatrist is, however, not currently mandated in European or United States guidelines

Psychological disturbance occurs in a valvular heart disease cohort at a higher rate than age-matched controls and can occur at all phases of the disease process. Depression and anxiety remain under-reported, underdiagnosed, and undertreated. Failure to diagnose and treat conditions such as depression, anxiety, and personality disorders may lead to increased morbidity, inappropriate denial of access to treatment, and poorer patient outcomes following treatment. Engagement of a multidisciplinary team including psychologists and psychiatrists during all aspects of valvular heart disease treatment is imperative to provide early recognition of psychological disturbance, provide necessary psychological treatment, and support and guide appropriate patient-centered valvular heart disease care.

References

Agatisa, P. K., Matthews, K. A., Bromberger, J. T., Edmundowicz, D., Chang, Y. F., & Sutton-Tyrrell, K. (2005). Coronary and aortic calcification in women with a history of major depression. *Archives of Internal Medicine, 165*, 1229 – 1236.

Anisman, H., & Merali, Z. (2002). Cytokines, stress, and depressive illness. *Brain, Behavior, and Immunity, 16*, 513 – 524.

Australian Bureau of Statistics. (2013). *Population projections, Australia, 2012 (base) to 2101*. Belconnen: Australian Bureau of Statistics.

Australian Institute of Health and Welfare. (2011). *Aboriginal and Torres Strait Islander health performance framework 2010: Detailed analyses*. Canberra: Australian Institute of Health and Welfare.

Barber, P. A., Hach, S., Tippett, L. J., Ross, L., Merry, A. F., & Milsom, P. (2008). Cerebral ischemic lesions on diffusion-weighted imaging are associated with neurocognitive decline after cardiac surgery. *Stroke; A Journal of Cerebral Circulation, 39*, 1427 – 1433.

Blumenthal, J. A., Lett, H. S., Babyak, M. A., et al. (2003). Depression as a risk factor for mortality after coronary artery bypass surgery. *Lancet, 362*, 604 – 609.

Carney, R. M., Freedland, K. E., Ludbrook, P. A., Saunders, R. D., & Jaffe, A. S. (1990). Major depression, panic disorder, and mitral valve prolapse in patients who complain of chest pain. *American Journal of Medicine, 89*, 757 – 760.

Cassem, E. H. (1995). Depressive disorders in the medically ill. An overview. *Psychosomatics, 36*, S2 – S10.

Colquhoun, D. M., Bunker, S. J., Clarke, D. M., et al. (2013). Screening, referral and treatment for depression in patients with coronary heart disease. *Medical Journal of Australia, 198*, 483 – 484.

Cribier, A., Eltchaninoff, H., Bash, A., et al. (2002). Percutaneous transcatheter implantation of an aortic valve prosthesis for calcific aortic stenosis: First human case description. *Circulation, 106*, 3006 – 3008.

DiMatteo, M. R., Lepper, H. S., & Croghan, T. W. (2000). Depression is a risk factor for noncompliance with medical treatment: Meta-analysis of the effects of anxiety and depression on patient adherence. *Archives of Internal Medicine, 160*, 2101 – 2107.

Empana, J. P., Sykes, D. H., Luc, G., et al. (2005). Contributions of depressive mood and circulating inflammatory markers to coronary heart disease in healthy European men: The prospective epidemiological study of myocardial infarction (PRIME). *Circulation, 111*, 2299 – 2305.

Faris, R., Purcell, H., Henein, M. Y., & Coats, A. J. (2002). Clinical depression is common and significantly associated with reduced survival in patients with non-ischaemic heart failure. *European Journal of Heart Failure, 4*, 541 – 551.

Friedmann, E., Thomas, S. A., Liu, F., Morton, P. G., Chapa, D., & Gottlieb, S. S. (2006). Relationship of depression, anxiety, and social isolation to chronic heart failure outpatient mortality. *American Heart Journal, 152*, 940 e1 – 940 e8.

Fujikawa, T., Yamawaki, S., & Touhouda, Y. (1993). Incidence of silent cerebral infarction in patients with major depression. *Stroke; A Journal of Cerebral Circulation, 24*, 1631 – 1634.

Ghanem, A., Muller, A., Nahle, C. P., et al. (2010). Risk and fate of cerebral embolism after transfemoral aortic valve implantation: A prospective pilot study with diffusion-weighted magnetic resonance imaging. *Journal of the American College of Cardiology, 55*, 1427 – 1432.

Ghanem, A., Kocurek, J., Sinning, J. M., et al. (2013). Cognitive trajectory after transcatheter aortic valve implantation. *Circulation Cardiovascular Interventions, 6*, 615 – 624.

Goyal, T. M., Idler, E. L., Krause, T. J., & Contrada, R. J. (2005). Quality of life following cardiac surgery: Impact of the severity and course of depressive symptoms. *Psychosomatic Medicine, 67*, 759 – 765.

Grenard, J. L., Munjas, B. A., Adams, J. L., et al. (2011). Depression and medication adherence in the treatment of chronic diseases in the United States: A meta-analysis. *Journal of General Internal Medicine, 26*, 1175 – 1182.

Hallas, J. (1996). Evidence of depression provoked by cardiovascular medication: A prescription sequence symmetry analysis. *Epidemiology, 7*, 478 – 484.

Havranek, E. P., Ware, M. G., & Lowes, B. D. (1999). Prevalence of depression in congestive heart failure. *American Journal of Cardiology, 84*, 348 – 350. A9.

Iung, B., Cachier, A., Baron, G., et al. (2005). Decision-making in elderly patients with severe aortic stenosis: Why are so many denied surgery? *European Heart Journal, 26*, 2714 – 2720.

Jeon, D. S., Atar, S., Brasch, A. V., et al. (2001). Association of mitral annulus calcification, aortic valve sclerosis and aortic root calcification with abnormal myocardial perfusion single photon emission tomography in subjects age < or =65 years old. *Journal of the American College of Cardiology, 38*, 1988 – 1993.

Jiang, W., Alexander, J., Christopher, E., et al. (2001). Relationship of depression to increased risk of mortality and rehospitalization in patients with congestive heart failure. *Archives of Internal Medicine, 161*, 1849 – 1856.

Jiang, W., Kuchibhatla, M., Cuffe, M. S., et al. (2004). Prognostic value of anxiety and depression in patients with chronic heart failure. *Circulation, 110*, 3452 – 3456.

Kahlert, P., Knipp, S. C., Schlamann, M., et al. (2010). Silent and apparent cerebral ischemia after percutaneous transfemoral aortic valve implantation: A diffusion-weighted magnetic resonance imaging study. *Circulation, 121*, 870 – 878.

Kala, P., Tretina, M., Poloczek, M., et al. (2013). Quality of life after transcatheter aortic valve implantation and surgical replacement in high-risk elderly patients. *Biomedical Papers of the Medical Faculty of the University Palacky, Olomouc, Czechoslovakia, 157*, 75 – 80.

Katon, W. J. (2003). Clinical and health services relationships between major depression, depressive symptoms, and general medical illness. *Biological Psychiatry, 54*, 216 – 226.

Katon, W., Sullivan, M., & Walker, E. (2001). Medical symptoms without identified pathology: Relationship to psychiatric disorders, childhood and adult trauma, and personality traits. *Annals of Internal Medicine, 134*, 917 – 925.

Katon, W., Unutzer, J., Fan, M. Y., et al. (2006). Cost-effectiveness and net benefit of enhanced treatment of depression for older adults with diabetes and depression. *Diabetes Care, 29*, 265 – 270.

Katon, W., Lin, E. H., & Kroenke, K. (2007). The association of depression and anxiety with medical symptom burden in patients with chronic medical illness. *General Hospital Psychiatry, 29*, 147 – 155.

Ko, D. T., Hebert, P. R., Coffey, C. S., Sedrakyan, A., Curtis, J. P., & Krumholz, H. M. (2002). Beta-blocker therapy and symptoms of depression, fatigue, and sexual dysfunction. *JAMA, 288*, 351 – 357.

Koenig, H. G. (1998). Depression in hospitalized older patients with congestive heart failure. *General Hospital Psychiatry, 20*, 29 – 43.

Lim, D. S., Reynolds, M. R., Feldman, T., et al. (2013). Improved functional status and quality of life in prohibitive surgical risk patients with degenerative mitral regurgitation following transcatheter mitral valve repair with the MitraClip(R) system. *Journal of the American College of Cardiology*. J Am Coll Cardiol. 2014 Jul 15;*64*(2):182 – 92.

Murberg, T. A., Bru, E., Svebak, S., Tveteras, R., & Aarsland, T. (1999). Depressed mood and subjective health symptoms as predictors of mortality in patients with congestive heart failure: A two-years follow-up study. *International Journal of Psychiatry in Medicine, 29*, 311 – 326.

Nishimura, R. A., Otto, C. M., Bonow, R. O., et al. (2014). AHA/ACC guideline for the management of patients with valvular heart disease: Executive summary: A report of the American College of Cardiology/American Heart Association task force on practice guidelines. J Am Coll Cardiol *63*(22):2438 – 2488.

Nkomo, V. T., Gardin, J. M., Skelton, T. N., Gottdiener, J. S., Scott, C. G., & Enriquez-Sarano, M. (2006). Burden of valvular heart diseases: A population-based study. *Lancet, 368*, 1005 – 1011.

Okamoto, Y., Motomura, N., Murashima, S., & Takamoto, S. (2013). Anxiety and depression after thoracic aortic surgery or coronary artery bypass. *Asian Cardiovascular & Thoracic Annals, 21*, 22 – 30.

Oxman, T. E., Freeman, D. H., Jr., & Manheimer, E. D. (1995). Lack of social participation or religious strength and comfort as risk factors for death after cardiac surgery in the elderly. *Psychosomatic Medicine, 57*, 5 – 15.

Pfeifer, P. M., Ruschel, P. P., & Bordignon, S. (2013). Coping strategies after heart transplantation: Psychological implications. *Revista Brasileira de Cirurgia Cardiovascular: Orgao Oficial da Sociedade Brasileira de Cirurgia Cardiovascular, 28*, 61 – 68.

Rabin, R., & de Charro, F. (2001). EQ-5D: A measure of health status from the EuroQol group. *Annals of Medicine, 33*, 337 – 343.

Rimington, H., Weinman, J., & Chambers, J. B. (2010). Predicting outcome after valve replacement. *Heart, 96*, 118 – 123.

Rodriguez, C. J., Bartz, T. M., Longstreth, W. T., Jr., et al. (2011). Association of annular calcification and aortic valve sclerosis with brain findings on magnetic resonance imaging in community dwelling older adults: The cardiovascular health study. *Journal of the American College of Cardiology, 57*, 2172 – 2180.

Rumsfeld, J. S., Havranek, E., Masoudi, F. A., et al. (2003). Depressive symptoms are the strongest predictors of short-term declines in health status in patients with heart failure. *Journal of the American College of Cardiology, 42*, 1811 – 1817.

Rutledge, T., Reis, V. A., Linke, S. E., Greenberg, B. H., & Mills, P. J. (2006). Depression in heart failure a meta-analytic review of prevalence, intervention effects, and associations with clinical outcomes. *Journal of the American College of Cardiology, 48*, 1527 – 1537.

Scherer, M., Himmel, W., Stanske, B., et al. (2007). Psychological distress in primary care patients with heart failure: A longitudinal study. *The British Journal of General Practice: The Journal of the Royal College of General Practitioners, 57*, 801 – 807.

Shuldham, C., Goodman, H., Fleming, S., Tattersall, K., & Pryse-Hawkins, H. (2001). Anxiety, depression and functional capacity in older women with mitral valve stenosis. *International Journal of Nursing Practice, 7*, 322 – 328.

Simon, G. E., Katon, W. J., Lin, E. H., et al. (2005). Diabetes complications and depression as predictors of health service costs. *General Hospital Psychiatry, 27*, 344 – 351.

Sullivan, M., Levy, W. C., Russo, J. E., & Spertus, J. A. (2004). Depression and health status in patients with advanced heart failure: A prospective study in tertiary care. *Journal of Cardiac Failure, 10*, 390 – 396.

Turvey, C. L., Schultz, K., Arndt, S., Wallace, R. B., & Herzog, R. (2002). Prevalence and correlates of depressive symptoms in a community sample of people suffering from heart failure. *Journal of American Geriatrics Society, 50*, 2003 – 2008.

Ussia, G. P., Mule, M., Barbanti, M., et al. (2009). Quality of life assessment after percutaneous aortic valve implantation. *European Heart Journal, 30*, 1790 – 1796.

Vahanian, A., Alfieri, O., Andreotti, F., et al. (2012). Guidelines on the management of valvular heart disease (version 2012). *European Heart Journal, 33*, 2451 – 2496.

Wallby, L., Steffensen, T., Jonasson, L., Broqvist, M. (2013). Inflammatory characteristics of stenotic aortic valves: A comparison between rheumatic and nonrheumatic aortic stenosis. *Cardiology Research and Practice,* 895215.

Ware, J., Snow, K. K., & Kosinski, M. (1993). *SF-36 health survey*. Boston: New England Medical Center, The Health Institute.

Ware, J., Jr., Kosinski, M., & Keller, S. D. (1996). A 12-item short-form health survey: Construction of scales and preliminary tests of reliability and validity. *Medical Care, 34*, 220 – 233.

World Health Organization. (2010). *International statistical classification of diseases and related health problems: 10th revision.* Geneva: World Health Organization.

Zipfel, S., Schneider, A., Wild, B., et al. (2002). Effect of depressive symptoms on survival after heart transplantation. *Psychosomatic Medicine, 64*, 740 – 747.

Zorrilla, E. P., Luborsky, L., McKay, J. R., et al. (2001). The relationship of depression and stressors to immunological assays: A meta-analytic review. *Brain, Behavior, and Immunity, 15*, 199 – 226.

Zung, W. W. (1965). A self-rating depression scale. *Archives of General Psychiatry, 12*, 63 – 70.

Appendix B – Oral Presentations

1. Assessment of the Geometric Interaction Between the Lotus Transcatheter Aortic Valve Prosthesis and the Native Ventricular Aortic Interface by 320-Multidetector Computed Tomography

    Cardiac Society of Australia and New Zealand 2015
    Transcatheter Cardiovascular Therapeutics 2014

2. Comparison of Self-Expanding and Mechanically Expanded Transcatheter Aortic Valve Prostheses

    Cardiac Society of Australia and New Zealand 2015
    EuroPCR 2015
    Transcatheter Cardiovascular Therapeutics 2014

3. 4-Dimensional Multidetector Computed Tomographic Assessment of Leaflet Thickening and Motion in Patients Treated with a Mechanically Expanded TAVR Prosthesis

    EuroPCR 2016

Appendix C – Awards and Scholarships

National Health and Medical Research Council Postgraduate Scholarship
Australian Federal Government
2013-2016

Australian Postgraduate Award
Monash University
2013

Faculty Postgraduate Award
Faculty Medicine, Nursing and Health Sciences – Monash University
2013

Clinical Academic Fellowship
Monash Health
2012-2013